



ORAL PRESENTATIONS

[OP-01]**When Bifurcation PCI Meets Coil Embolization: Mini-Crush Reconstruction of a Distal Left Main Aneurysm**

Direnc Yılmaz, Yusuf Can

Department of Cardiology, Sakarya University Training and Research Hospital, Sakarya

Aim: Coronary artery aneurysms involving the distal left main coronary artery (LMCA) and the bifurcation of the left anterior descending (LAD) and circumflex (Cx) arteries are rare and represent a complex therapeutic challenge. Optimal management remains controversial and may include surgical repair, covered stents, or percutaneous exclusion techniques. Stent-assisted coil embolization has emerged as a potential alternative in selected cases. We present a case of distal LMCA aneurysm involving the LAD and Cx ostia treated with bifurcation percutaneous coronary intervention (PCI) followed by coil embolization.

Methods: A 60-year-old male with a history of bladder and renal pelvis malignancy was admitted to the coronary intensive care unit with non-ST-segment elevation myocardial infarction. Transthoracic echocardiography demonstrated a left ventricular ejection fraction of 60% with mild mitral and tricuspid regurgitation. Coronary angiography revealed a distal LMCA aneurysm involving the LAD and Cx ostia, with a significant distal LAD lesion (~70%). After multidisciplinary evaluation, surgical treatment was considered inappropriate due to underlying malignancy and diffuse coronary anatomy. Therefore, a percutaneous strategy was planned.

Results: PCI was performed via right femoral access using a 7F sheath. The LMCA was engaged with a 7F EBU guiding catheter. After wiring the LAD and Cx, lesion preparation was performed with sequential balloon predilatations. Due to challenging anatomy and difficulty in stent delivery, a mini-crush bifurcation technique was performed. A drug-eluting stent was deployed from the LAD extending into the LMCA, followed by implantation of a Cx drug-eluting stent which crushed the LAD stent at the bifurcation. Proximal optimization technique and final kissing balloon inflation were subsequently performed. Following bifurcation stenting, a microcatheter was advanced through the stent struts into the aneurysm sac. Two detachable coils (6 mm×20 cm and 9 mm×30 cm) were successfully deployed within the aneurysm, achieving effective embolization. An additional LMCA drug-eluting stent was then implanted with proximal optimization to reinforce the reconstruction. Final angiography demonstrated preserved vessel patency and TIMI 3 flow without procedural complications. On the evening following the procedure, the patient developed severe vomiting and increasing somnolence. Urgent cranial imaging revealed no evidence of intracranial pathology. Neurology consultation was obtained, and no acute neurological event was suspected. The patient's clinical status subsequently stabilized, and he was discharged in good condition two days later. However, four days after discharge, he was brought to the emergency department with cardiac arrest and could not be resuscitated.

Conclusion: Distal LMCA aneurysms involving coronary bifurcations are extremely rare and present significant technical challenges for revascularization. Conventional treatment options such as surgical repair or covered stents may not be feasible in patients with complex anatomy or high surgical risk. In such situations, a hybrid percutaneous approach combining bifurcation PCI and stent-assisted coil embolization may provide an effective alternative. The stent framework acts as a scaffold that prevents coil protrusion while preserving side-branch patency. This case demonstrates the feasibility of combining mini-crush bifurcation stenting with coil embolization for the treatment of a complex distal LMCA aneurysm.

Keywords: Coronary artery aneurysm, left main coronary artery, coil embolization, mini-crush technique, percutaneous coronary intervention

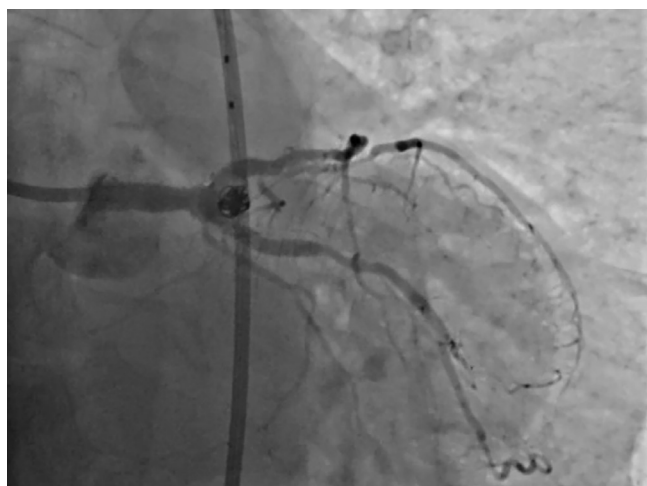


Figure 1.

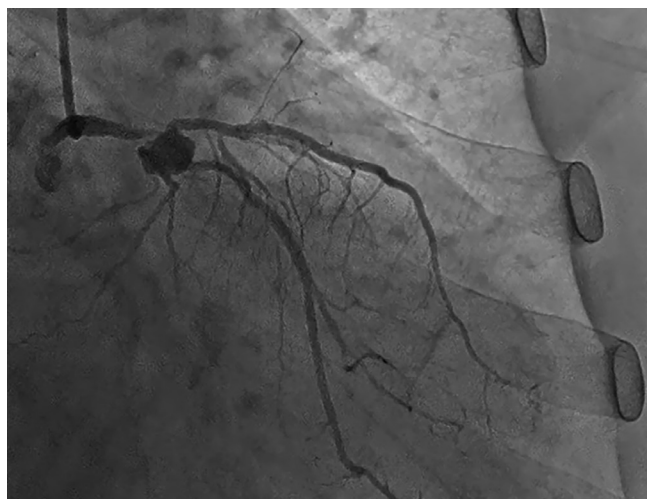


Figure 2.

[OP-02]**Can We Predict the Severity of Coronary Artery Disease with ECG Before Angiography? The Role of fQRS and Tp-e/QTc Ratio**Gülizar Traş¹, Emre Paçacı²¹University of Health Sciences Türkiye, Mersin City Hospital, Mersin²University of Health Sciences Türkiye, Osmaniye Training and Research Hospital, Osmaniye

Aim: Coronary artery disease (CAD) is one of the leading causes of global morbidity and mortality. The Syntax score, which demonstrates the complexity and prevalence of coronary lesions, is of critical importance in determining treatment strategies. In this study, we aimed to investigate the relationship between the presence of fragmented QRS (fQRS) and the Tp-e/QTc ratio observed on a standard 12-lead ECG before invasive procedures, and the presence and severity (Syntax score) of CAD.

Methods: A total of 247 patients who underwent coronary angiography were included in the study. Patients were divided into two groups according to their Syntax score: "normal/non-significant stenosis" (n=91) and "significant Stenosis" (Syntax >0, n=156). The presence of fQRS, Tp-e interval, and Tp-e/QTc ratios were calculated on ECG. Demographic, clinical, and electrocardiographic data were compared between the groups.

Results: The prevalence of age, hypertension, diabetes, and hyperlipidemia was significantly higher in the CAD group (p<0.05). The presence of fQRS was significantly higher in the CAD group compared to the normal group (70.6% vs. 6.6%, p<0.001). The Tp-e interval was significantly longer in the CAD group (102 ms vs. 78 ms). The Tp-e/QTc ratio showed a positive correlation with the severity of CAD (0.24 in the Syntax >0 group vs. 0.18 in the normal group).

Conclusion: The presence of fQRS and an increased Tp-e/QTc ratio on a standard ECG are cost-effective, accessible, and strong non-invasive markers for predicting the severity of CAD. Evaluating these parameters before angiography may provide clinical benefit in identifying high-risk patients.

Keywords: Coronary artery disease, Syntax score, fragmented QRS, Tp-e/QTc

Table 1. Demographic and clinical characteristics of the study groups

Parameters	Normal/non-significant stenosis (n=91)	Significant stenosis (Syntax >0) (n=156)	p value
Age (mean)	Lower	Higher	<0.05
Hypertension (HT)	Lower prevalence	Higher prevalence	<0.05
Diabetes mellitus (DM)	Lower prevalence	Higher prevalence	<0.05
Hyperlipidemia (HL)	Lower prevalence	Higher prevalence	<0.05

Table 2. Comparison of electrocardiographic parameters between groups

ECG parameters	Normal group (n=91)	CAD group (n=156)	p value
Presence of fQRS (%)	6.6%	70.6%	<0.001
Tp-e interval (ms)	78 ms	102 ms	<0.05
Tp-e/QTc ratio	0.18	0.24	<0.05

Table 3. Correlation between ECG markers and Syntax score

Variable	Correlation with Syntax score (r)	Statistical significance (p)
Presence of fQRS	Strong positive	<0.001
Tp-e/QTc ratio	Positive	<0.05

[OP-03]**Successful Percutaneous Extraction of a Partially Aortic-Migrated Coronary Stent Using a Snare During Primary PCI: A Complex Bailout Case in an Elderly Patient**

İlyas Cetin, Deniz Dilan Naki Tekin

Clinic of Cardiology, University of Health Sciences Türkiye, Başakşehir Çam and Sakura City Hospital, Istanbul

Aim: Stent loss during percutaneous coronary intervention (PCI) is a rare but potentially life-threatening complication. The risk is increased particularly in the presence of advanced age, vessel tortuosity, and heavily calcified lesions. Early recognition and appropriate percutaneous retrieval techniques may reduce the need for emergency surgical intervention.

Case Report: An 87-year-old male patient presented with chest pain and dyspnea persisting for two days. Elevated troponin levels were detected, and the patient was hospitalized with a diagnosis of non-ST-elevation myocardial infarction. Following loading doses of acetylsalicylic acid and clopidogrel, the patient was transferred to the catheterization laboratory. Coronary angiography demonstrated a severely calcified lesion causing approximately 90% stenosis in the mid right coronary artery (RCA), and PCI was planned using a 7F AL-1 guiding catheter. Initial predilatation was performed with 2.5×10 mm semi-compliant (SC) and 2.75×20 mm non-compliant balloons. Subsequently, a 3.0×31 mm drug-eluting stent was advanced toward the lesion but could not be delivered. A floppy extra-support guidewire was introduced as a buddy wire. A 2.5×10 mm SC balloon was then advanced to the distal RCA for an anchor-balloon technique. During a subsequent attempt at stent delivery, the stent became dislodged from the shaft before reaching the lesion and migrated to the proximal segment, partially protruding into the guiding catheter. As the guidewires and guiding catheter position were preserved, the distally located 2.5×10 mm SC balloon was pulled back proximally for a trapping maneuver. The stent segment protruding into the guiding catheter was trapped using the balloon; however, while withdrawing the guiding catheter, the stent slipped out of the catheter. During advancement of a 2.5×20 mm SC balloon for a repeated trapping attempt, catheter disengagement occurred and approximately half of the stent protruded into the aorta. Subsequently, multiple retrieval attempts were performed using 6-10 mm and 12-20 mm snare systems targeting the proximal segment of the stent. However, the stent could not be captured because it was lying against the aortic wall. Severe tortuosity of the femoral arteries further complicated catheter manipulation; therefore, a 45 cm Destination sheath was inserted. Despite repeated attempts, retrieval remained unsuccessful, and a second 7F sheath was inserted through the contralateral femoral artery. The strategy was revised to advance behind the stent and elevate its proximal edge using right guiding and internal mammary artery catheters, followed by capture with a snare. These attempts were also unsuccessful. A pigtail catheter was then utilized; however, optimal repositioning of the stent could not be achieved. Consequently, the distal half of the pigtail catheter tip was cut and modified into a U-shaped configuration. This modified pigtail catheter was successfully advanced behind the stent, allowing elevation of the proximal portion of the stent. The proximal segment was then successfully captured using a 12-20 mm snare with the assistance of a right diagnostic catheter. During withdrawal, it was observed that the pigtail catheter had also become entrapped within the snare. To prevent distal embolization, the entire system was withdrawn together up to the level of the Destination sheath. As the system could not be fully retrieved into the sheath, it was pulled back to the right femoral artery. The Destination sheath and right diagnostic catheter were completely removed, and a 10F sheath was inserted over the snare wire. While attempting to advance the pigtail catheter into the 10F sheath over a guidewire introduced through the sheath, the stent slipped again and remained freely suspended within the femoral artery. The pigtail catheter was withdrawn through the contralateral sheath. Finally, using a right guiding catheter and a 6-10 mm snare introduced through the 10F sheath in the right femoral artery, the stent was securely captured and successfully removed from the body. Control angiography demonstrated no evidence of iliac or femoral artery dissection or contrast extravasation. Continuation of RCA stenting was planned; however, because the patient became clinically agitated, the procedure was deferred

to an elective second session. The incidence of stent loss with contemporary coronary systems has been reported to be below 0.5%. Advanced age, severe calcification, and tortuous vascular anatomy are recognized major risk factors. In the current literature, the snare technique remains the most commonly utilized retrieval method. ESC guidelines addressing rare PCI complications recommend percutaneous retrieval strategies whenever feasible in order to avoid emergency surgery. Prompt intervention is essential to reduce the risk of distal embolization and systemic complications.

Conclusion: Stent migration occurring during PCI in elderly patients can be successfully managed percutaneously without the need for surgical intervention when appropriate equipment, advanced retrieval techniques, and operator experience are available

Keywords: Stent migration, snare retrieval, modified pigtail hook technique

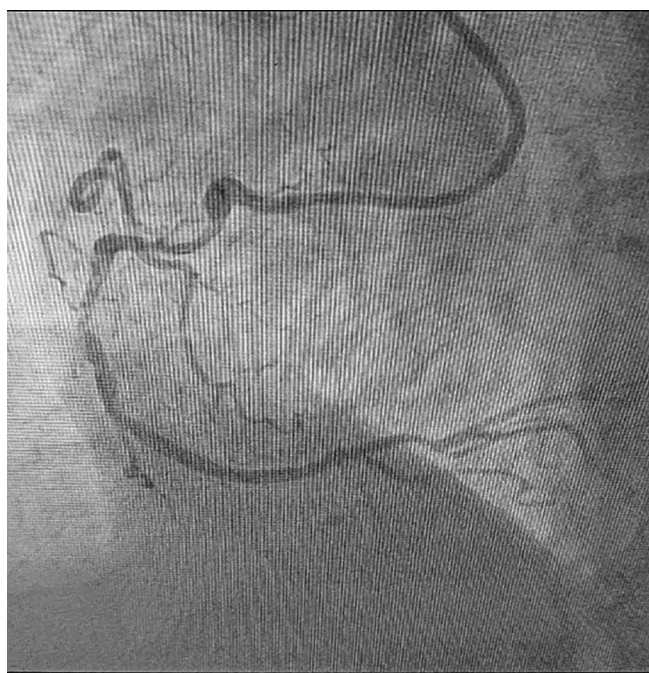


Figure 1. Angiographic imaging. Tortuous, calcified mid-RCA segment

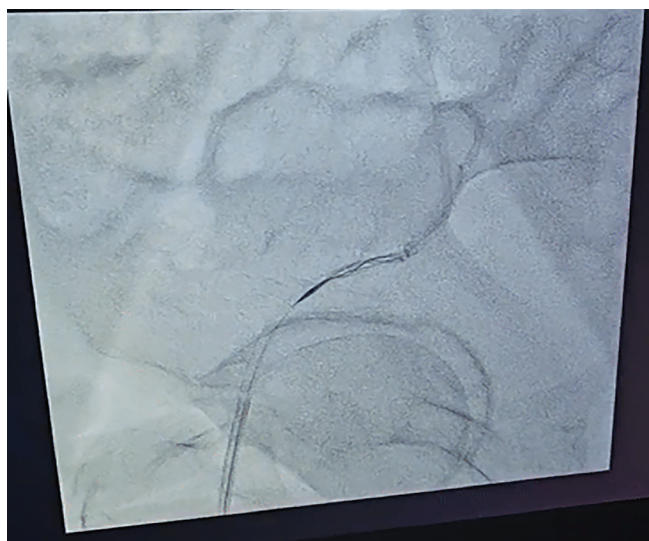


Figure 2. The modified pigtail and the stent were captured together with a snare and pulled downward. Subsequently, the stent was safely retrieved using a second snare

[OP-07]**Not Everything that Appears is Real: In a Patient Recommended for CABG, IVUS Showed Normal Coronary Arteries**

Esra Danişman¹, Oğuzhan Abanoz¹, Lina Boukhemis¹, Kamran Kerimzade¹, Behice Hande Şişman Uzunoglan², Sezgin Uzunoglan², Mahmut Uluganyan¹

¹Bezmialem Vakıf University Hospital, İstanbul

²Kırklareli Training and Research Hospital, Kırklareli

Case Report: A 46-year-old male with a history of smoking, newly diagnosed hypertension, and a strong family history of coronary artery disease was referred for elective coronary angiography. He had a prior normal angiogram in 2018. Due to the new onset of a resistant hypertension the patient underwent a coronary angiography at an external center, revealing a distal left main and an ostial circumflex (CX) lesions with a pathological FFR value of 0.69. Based on these findings, coronary artery bypass grafting (CABG) was recommended. At our center, the patient was asymptomatic with normal electrocardiography and preserved left ventricular systolic function. Repeat angiographic evaluation did not demonstrate significant stenosis. To clarify the discrepancy, intravascular ultrasound (IVUS) imaging of the left main-left anterior descending (LMCA-LAD) and LMCA-CX segments was performed. IVUS revealed non-critical atherosclerotic plaques with normal lumen area, no significant intimal thickening, and no calcification. No hemodynamically significant lesion was identified.

Conclusion: This case highlights the potential for discordance between physiological and anatomical assessments and underscores the critical role of IVUS in avoiding unnecessary revascularization. Multimodality evaluation should be considered in cases of diagnostic uncertainty.

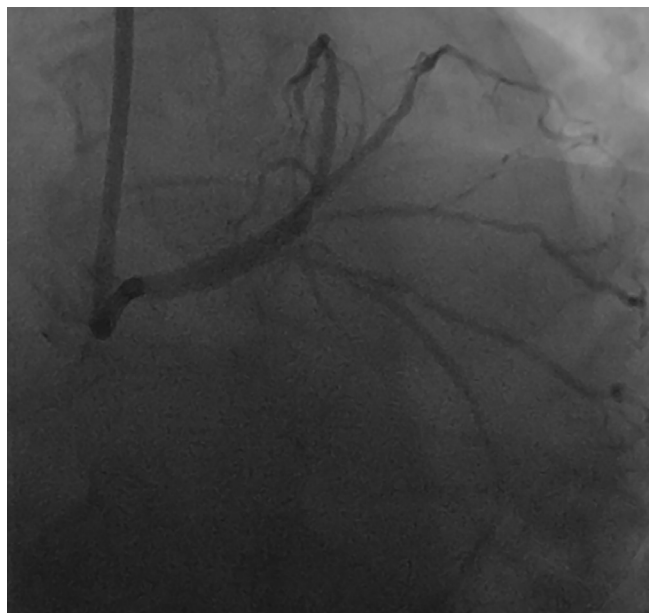


Figure 1.

[OP-09]**Successful Management of Complex Ostial SVG-CX In-Stent Restenosis with LMCA-CX Crossover CTO PCI**

Ahmet Anil Başkurt, Oktay Senoz

Department of Cardiology, Bakırçay University Çiğli Training and Research Hospital, İzmir

Aim: The management of recurrent in-stent restenosis (ISR) in saphenous vein grafts (SVGs), especially at ostial locations, remains a clinical challenge in patients with prior coronary artery bypass grafting (CABG). Drug-coated balloons (DCB), non-compliant (NC) balloons, and intravascular lithotripsy (IVL) may not always provide optimal outcomes, particularly in heavily calcified and fibrotic lesions. We present a case of a heavily diseased SVG-CX ostial lesion with recurrent restenosis treated successfully via native LMCA-CX CTO recanalization and stenting.

Case Report: A 75-year-old male with a history of three-vessel CABG in 1988 was referred for recurrent exertional angina despite optimal medical therapy. His prior coronary interventions include:

- 2018: PCI to ostial SVG-CX due to acute coronary syndrome.
- 2022: Repeat PCI to the same region due to SVG-CX in-stent thrombosis.
- 2025: New onset angina despite OMT; diagnostic angiography revealed a 99% restenosis in ostial SVG-CX.

Despite pre-dilation with non-compliant balloon and drug-coated balloon therapy, optimal luminal area could not be achieved. IVL was considered, but due to anatomical limitations and high restenosis risk, a native vessel CTO intervention was planned. Angiography revealed a CTO at the CX ostium extending from the LMCA. CTO-PCI was performed via antegrade wiring and successful lesion crossing. A drug-eluting stent was implanted from LMCA to CX in cross-over fashion, achieving TIMI 3 flow with excellent angiographic result. This case highlights the limitations of repeat SVG intervention and the potential benefit of returning to native circulation in selected patients. CTO PCI of the LMCA-CX segment poses significant technical demands but can offer a more durable solution in recurrent SVG restenosis cases, especially when the lesion involves the ostium and prior interventions have failed. LMCA involvement increases procedural complexity and risk, yet cross-over stenting remains a viable strategy when executed in high-volume centers with intraprocedural imaging. Although IVL was considered, the lesion's characteristics and the patient's comorbidities directed the choice toward CTO PCI.

Conclusion: In patients with complex, recurrent SVG-CX restenosis, native vessel CTO-PCI with LMCA to CX cross-over stenting can be a feasible and effective revascularization strategy when performed in experienced centers. This case underscores the importance of individualized anatomical and procedural planning in the era of high-complexity coronary interventions.

Keywords: LMCA-CX crossover, CTO PCI, IVL

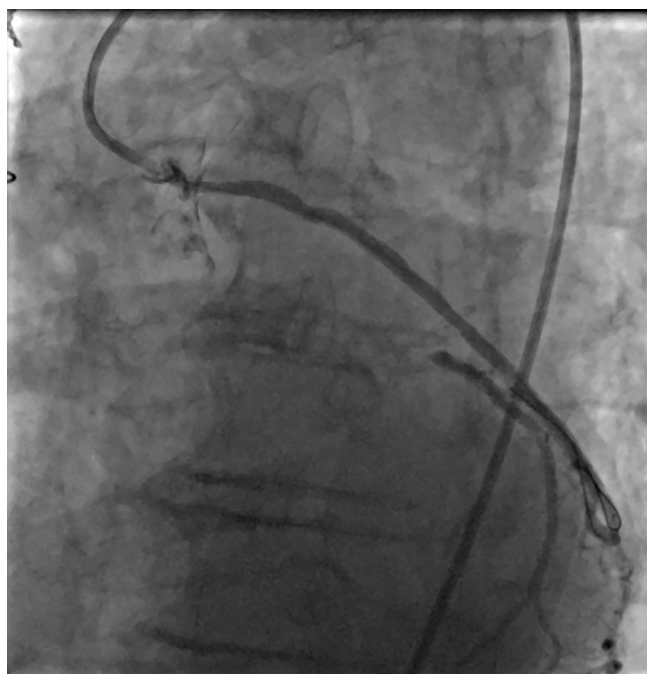

Figure 1. Angiographical result after AO-SVG-OM intervention

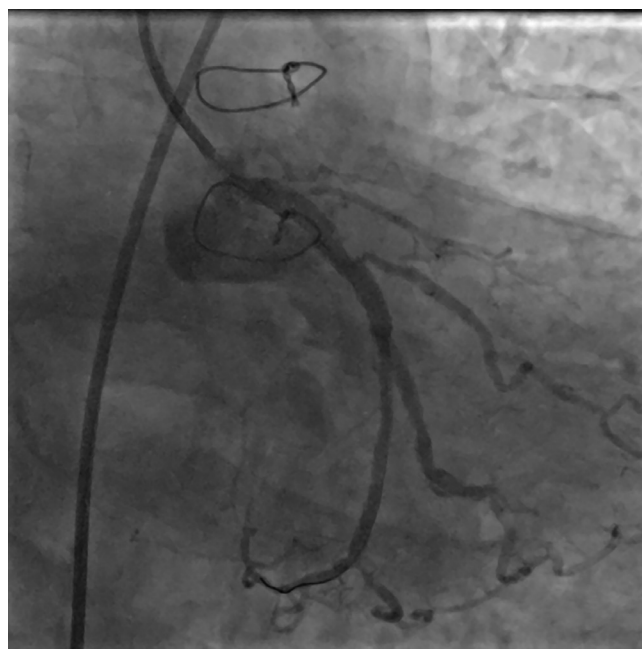


Figure 2. Final view after LMCA-CX crossover CTO PCI procedure

[OP-11]**Complex Percutaneous Coronary Intervention of a Severely Calcified Native Circumflex Artery Using Rotational Atherectomy in a Post-CABG Patient**

İlker Gül, Oktay Şenöz, Ecem Gürses, İlhan Koyuncu, Ahmet Anıl Başkurt, Fuat Gündoğdu

Department of Cardiology, Bakırçay University Çiğli Training and Research Hospital, Izmir

Aim: Severe coronary artery calcification is an important factor limiting the success of percutaneous coronary intervention (PCI), particularly in patients with previous coronary artery bypass grafting (CABG). Adequate lesion preparation in heavily calcified and diffusely diseased vessels is crucial for optimal stent expansion and procedural success. Rotational atherectomy is an established plaque modification technique used to facilitate PCI in such complex lesions.

Case Report: A 65-year-old male with a history of CABG performed 11 years earlier was admitted to our clinic with a diagnosis of non-ST elevation myocardial infarction (NSTEMI). Coronary angiography revealed patent left internal mammary artery to left anterior descending artery (LIMA-LAD) and aorto-saphenous vein graft to the right coronary artery (Ao-SVG-RCA). However, the aorto-saphenous graft to the obtuse marginal branch (Ao-SVG-OM) was totally occluded. The native circumflex artery distal to the bifurcation was diffusely diseased and severely calcified. PCI of the native circumflex artery was planned. The patient received a loading dose of prasugrel 60 mg prior to the procedure and was already on acetylsalicylic acid 100 mg daily. At the beginning of the procedure, 10,000 IU unfractionated heparin was administered intracoronarily. Vascular access was obtained via the right femoral artery and a vascular sheath was placed. An EBU 4 guiding catheter was engaged at the ostium of the left main coronary artery (LMCA). With microcatheter support, a PT II guidewire was advanced to the distal OM II branch. Subsequently, a Rotawire was positioned distally through the microcatheter. Rotational atherectomy was successfully performed using a 1.75 mm burr from the circumflex artery to the distal OM II. Following plaque modification, post-dilatation was performed with a 2.5×20 mm non-compliant balloon. Drug-eluting stents (2.5×28 mm and 2.75×23 mm) were implanted in the treated segments. The mid segment of the OM II branch was predilated with a 2.0×20 mm non-compliant balloon and subsequently treated with a 2.0×22 mm drug-coated balloon inflated for 120 seconds. After intracoronary nitrate administration, final angiography demonstrated TIMI III flow with an optimal angiographic result. The procedure was completed without complications.

Conclusion: In patients with severely calcified and diffusely diseased coronary arteries, adequate plaque modification is a key determinant of procedural success. Rotational atherectomy is an effective technique to facilitate PCI in such complex lesions. When sufficient lesion preparation cannot be achieved, adjunctive devices such as cutting balloons, scoring balloons, or intravascular lithotripsy may further improve procedural outcomes.

Keywords: Coronary artery by-pass surgery, calcified lesion, plaque modification, rota-ablation

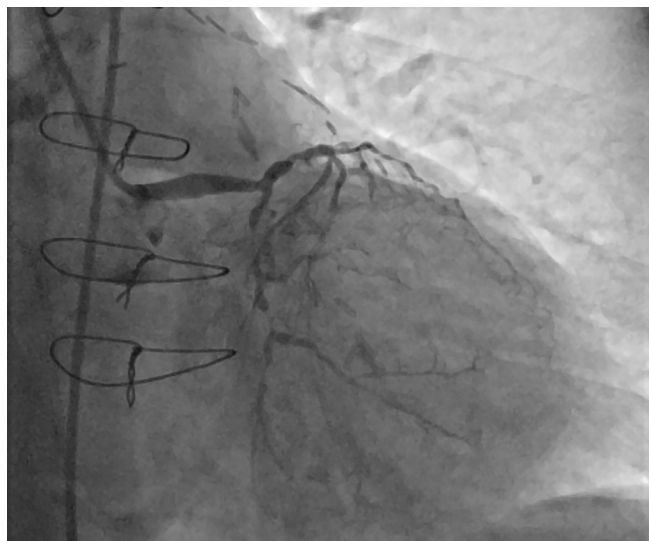


Figure 1.

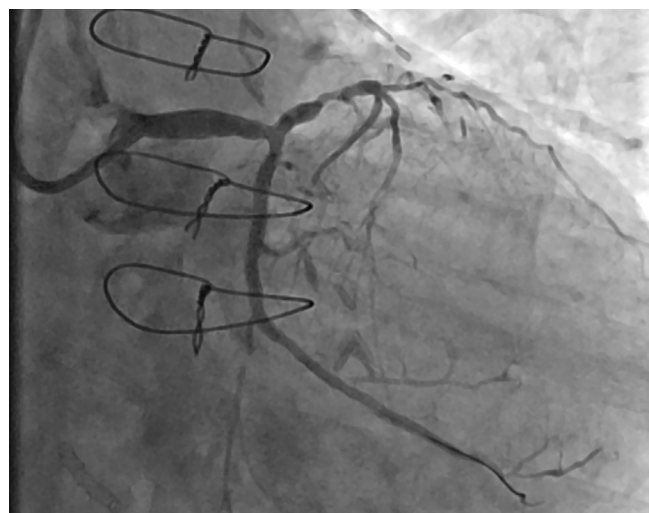


Figure 2.

[OP-12]**Complex Percutaneous Management of Guidewire Fracture During Coronary Bifurcation Intervention: A Case Report**

Onur Şeref, Cemil Zencir, Sevil Ulaştı

Department of Cardiology, Aydın Adnan Menderes University Faculty of Medicine, Aydın

Aim: Although guidewire entrapment or fracture during percutaneous coronary intervention (PCI) is uncommon, with reported incidences of approximately 0.1-0.2% in some series, its management can be challenging and may lead to serious complications. The risk of side-branch wire entrapment beneath stent struts (jailed wire entrapment) may increase in bifurcation lesions, particularly when dual-wire protection of the side branch is used, in the presence of severe calcification or vessel tortuosity, overlapping stents, and high-pressure post-dilatation. Management depends on the coronary flow status, the location of the entrapped wire, hemodynamic stability, and whether a free wire end is available. Percutaneous techniques such as balloon trapping, space enlargement with a microcatheter or low-profile balloon, and snare retrieval have been described, as have conservative management, leaving the wire within the stent, and surgical removal.

Case Report: A 47-year-old male patient was admitted to the catheterization laboratory for elective coronary angiography because of stable angina. Arterial access was obtained through the right radial artery using a 7 Fr thin-walled introducer sheath. The left main coronary artery (LMCA) was engaged with an EBU guiding catheter. The circumflex artery (Cx) and obtuse marginal (OM) lesions were crossed with floppy guidewires. Predilatation of the Cx lesion was performed using a 2.0x15 mm balloon. Subsequently, a 2.5x15 mm stent was implanted in the Cx lesion, followed by an additional 2.5x16 mm stent to provide proximal overlap. On post-stenting control angiography, the OM wire was noted to be trapped beneath the stent struts. An attempt was made to withdraw the wire; however, it could not be mobilized because it was caught beneath the stent struts. A 1.25x6 mm balloon was then used with the aim of enlarging the strut-vessel wall space and freeing the wire. When the balloon and wire were withdrawn together, most of the wire was retrieved; however, the wire tip remained trapped beneath the struts. Because the wire tip could not be straightened and to secure against possible loss of main-branch flow, the left anterior descending artery (LAD) was first wired. A snare system was then advanced, and percutaneous retrieval of the retained wire tip was attempted. The wire was captured with the snare, but it could not be removed despite traction. During this process, TIMI 0 flow developed in the Cx. Because of suspected acute thrombotic burden and possible no-reflow, intracoronary tirofiban was administered. Both OM1 and Cx were then rewired, and percutaneous transluminal coronary angioplasty (PTCA) was performed using 1.0x5 mm, 1.25x5 mm, and 2.0x15 mm balloons. When deterioration of LAD flow also occurred during the procedure, a 3.0x50 mm stent was implanted from the LMCA into the LAD. Proximal optimization technique (POT) was subsequently performed at the LMCA ostium using a 4.5x15 mm balloon. Thereafter, the Cx was recrossed with a PT2 guidewire. Predilatation along the Cx was performed using 1.25x5 mm and 2.0x15 mm balloons. A 2.75x12 mm stent was implanted in the Cx using the T and protrusion (TAP) technique. For final bifurcation optimization, kissing balloon dilatation was performed using a 3.5x15 mm balloon on the LAD side and the stent balloon on the Cx side. Finally, post-dilatation of the LMCA ostium was performed with a 5.0x6 mm balloon. The procedure was completed after achieving TIMI 3 flow. The patient was monitored for one day in the intensive care unit and then for one day in the ward. During follow-up, he reported no chest pain and was discharged uneventfully.

Conclusion: Jailed wire entrapment develops when a side-branch protection wire used during bifurcation PCI becomes trapped between the main-vessel stent struts and the vessel wall. Aggressive traction may result in wire fracture, stent deformation, or vessel injury. Therefore, excessive traction should be avoided during wire retrieval attempts. When necessary, stepwise percutaneous bailout techniques, including space enlargement with a microcatheter or

low-profile balloon, balloon trapping, or snare retrieval in suitable anatomy, should be considered. The distinctive feature of the present case is that the problem evolved beyond a simple entrapped wire: it first resulted in TIMI 0 flow in the Cx and subsequently caused deterioration of LAD flow, thereby becoming clinically significant. At this stage, the interventional strategy shifted from a wire retrieval-focused approach to a complex bifurcation bailout strategy aimed at restoring coronary flow. Cases reported from Türkiye have also described different strategies for jailed guidewire management, including conservative follow-up, leaving the wire within the stent, and surgical removal. In addition, a surgical approach may become unavoidable when the guidewire extends into the aorta or proximal coronary segments, when percutaneous retrieval fails, or when ongoing ischemia persists.

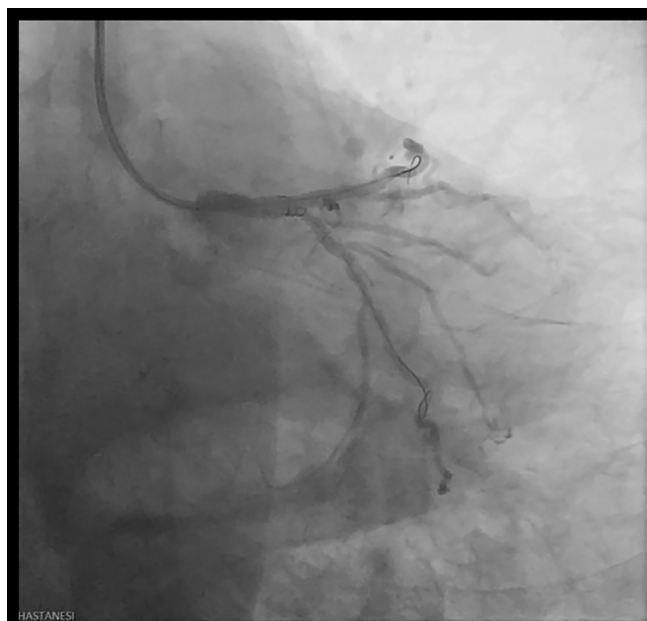


Figure 1. Final image

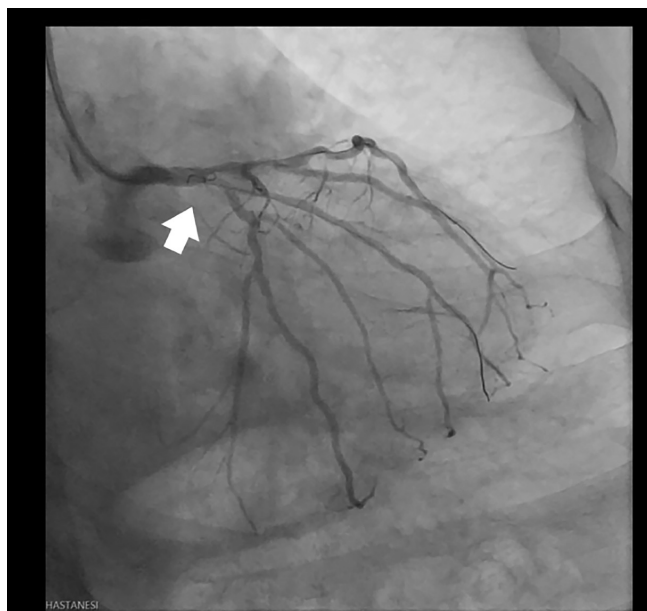


Figure 2. Guide wire breakage

[OP-13]**Colchicine Use After Coronary Artery Stenting: One-Year Follow-Up Results**Sherzod Akhmedov^{1,2}¹Ezgu Niyat Clinic, Tashkent²Carmen Clinic, Bukhara

Aim: Restenosis following coronary artery stenting remains an important clinical challenge in patients with ischemic heart disease. Although drug-eluting stents (DES) have significantly reduced restenosis rates, high-risk populations such as patients with diabetes mellitus and vascular calcification continue to experience in-stent restenosis and recurrent ischemic events. Inflammation plays a central role in restenosis development, as vascular injury during stent implantation triggers inflammatory pathways that promote neointimal proliferation. Colchicine, a well-known anti-inflammatory agent, inhibits the NLRP3 inflammasome and reduces inflammatory mediators including C-reactive protein (CRP), interleukin-6 (IL-6), and tumor necrosis factor-alpha (TNF- α). While colchicine has demonstrated cardiovascular benefits in recent trials, its effect on restenosis prevention after percutaneous coronary intervention (PCI) remains insufficiently studied. This study aimed to evaluate the efficacy of colchicine in reducing the incidence of in-stent restenosis one year after PCI with DES implantation.

Methods: This prospective randomized controlled trial was conducted at Ezgu Niyat Cardiology Center and Carmen + Clinic (Uzbekistan) between January 2021 and December 2024. A total of 120 patients with stable coronary artery disease who underwent successful elective PCI with DES implantation

were enrolled. Participants were randomized in a 1:1 ratio into two groups: Colchicine group (n=60): colchicine 0.5 mg once daily for 12 months, Placebo group (n=60): matching placebo for 12 months. The primary endpoint was the incidence of angiographically confirmed in-stent restenosis at 12 months, defined as $\geq 50\%$ luminal diameter narrowing within the stented segment. Secondary endpoints included major adverse cardiovascular events (MACE) during follow-up and changes in inflammatory biomarkers (CRP, IL-6, and TNF- α).

Results: At one-year follow-up, restenosis occurred significantly less frequently in the colchicine group compared with the placebo group (6.7% vs. 18.3%, $p=0.02$). In the colchicine group, restenosis was observed in 4 patients (6.7%): LAD 0%, RCA 15%, and LCX 6.7%. In the placebo group, restenosis occurred in 11 patients (18.3%): LAD 6.7%, RCA 25%, and LCX 40%. Subgroup analysis showed lower restenosis rates with colchicine in patients with diabetes (7.3% vs. 16.7%) and in those with coronary calcification (7.7% vs. 15.4%). Inflammatory markers significantly decreased in the colchicine group during follow-up: CRP decreased from 4.2 ± 1.1 to 1.8 ± 0.7 mg/L, IL-6 from 6.5 ± 1.4 to 3.1 ± 1.0 pg/mL, and TNF- α from 12.7 ± 2.3 to 6.2 ± 1.5 pg/mL ($p < 0.01$). No significant biomarker changes were observed in the placebo group.

Conclusion: Daily colchicine therapy (0.5 mg) significantly reduced the incidence of in-stent restenosis and systemic inflammation at one year following PCI with DES implantation. The benefit was particularly notable in high-risk patients with diabetes and coronary calcification. These findings suggest that colchicine may serve as a valuable adjunctive therapy after PCI to reduce inflammatory activity and restenosis risk. Larger multicenter trials are warranted to confirm these results and further define patient populations that may benefit most from colchicine therapy.

Keywords: Colchicine, in-stent restenosis, inflammation

[OP-14]**Climbing the Steps of Complex PCI: Stepwise Multivessel Revascularization in a High-Risk Patient**

İlker Gül, Oktay Şenöz, Ecem Gürses, Zeynep Yapan Emren, Fuat Gündoğdu, Ahmet Anıl Başkurt, Saadet Aydın, Eren Ozan Bakır

Department of Cardiology, Bakırçay University Çiğli Training and Research Hospital, İzmir

Aim: Management of complex multivessel coronary artery disease in patients with significant comorbidities remains challenging, particularly when surgical revascularization carries high perioperative risk. In such patients, percutaneous coronary intervention (PCI) using contemporary devices and tailored strategies may offer an effective alternative. Drug-coated balloons (DCB), selective drug-eluting stent (DES) implantation, and chronic total occlusion (CTO) techniques can facilitate successful revascularization in diffuse and complex lesions.

Case Report: A 59-year-old male patient with a history of diabetes mellitus, active smoking, chronic obstructive pulmonary disease, and a previous thromboembolic cerebrovascular event was evaluated for symptomatic coronary artery disease. Coronary angiography revealed diffuse disease of the left anterior descending artery (LAD), a critical distal lesion in the circumflex artery (Cx), and chronic total occlusion (CTO) of the OM II branch. Given the patient's high surgical risk profile, the heart team decided to perform percutaneous coronary intervention. The patient was already receiving dual antiplatelet therapy with acetylsalicylic acid and clopidogrel; therefore, no additional loading dose was administered. At the beginning of the procedure, 10,000 IU of unfractionated heparin was administered intracoronarily. The LAD lesions were crossed with a Runthrough guidewire. The distal LAD was predilated using 2.0×20 mm and 2.5×18 mm non-compliant balloons. Drug-coated balloons measuring 2.0×26 mm and 2.5×22 mm were subsequently inflated for 90 seconds in the distal LAD segment. In the mid-LAD segment, a 2.75×28 mm drug-eluting stent was implanted followed by high-pressure postdilatation to optimize stent expansion. The distal circumflex lesion was predilated with a 2.5×18 mm non-compliant balloon and subsequently treated with a 2.5×22 mm drug-coated balloon. The OM II CTO lesion was crossed with a Fielder XT-R guidewire with microcatheter support. After successful wire crossing, sequential predilatations were performed, and a 2.75×38 mm drug-eluting stent was implanted from the ostium of OM II to the distal segment. Final angiography demonstrated restoration of TIMI III flow. Following the complex multivessel PCI procedure, the patient remained hemodynamically stable and was discharged from the hospital without any additional complications.

Conclusion: In carefully selected patients with complex multivessel coronary artery disease and high surgical risk, single-session multivessel PCI can be performed safely and effectively. The combination of drug-coated balloon therapy, selective DES implantation, and dedicated CTO techniques may allow complete revascularization while minimizing procedural complications. Careful patient selection and appropriate interventional strategies are essential to achieve optimal outcomes.

Keywords: Multi-vessel revascularization, drug coated balloon, chronic total occlusion

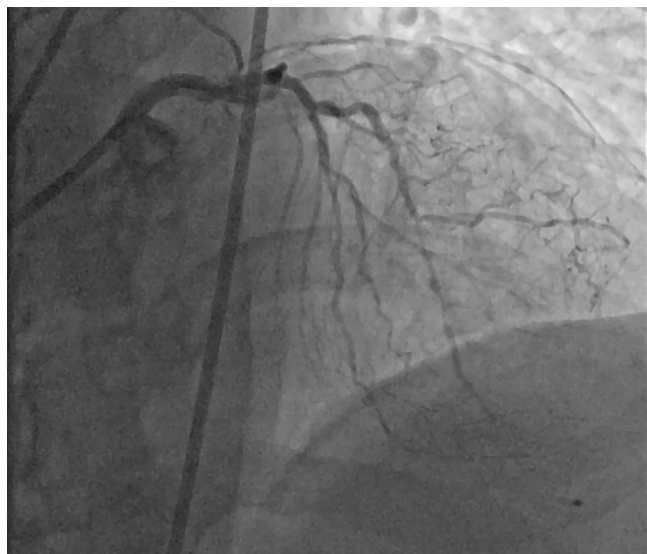

Figure 1.

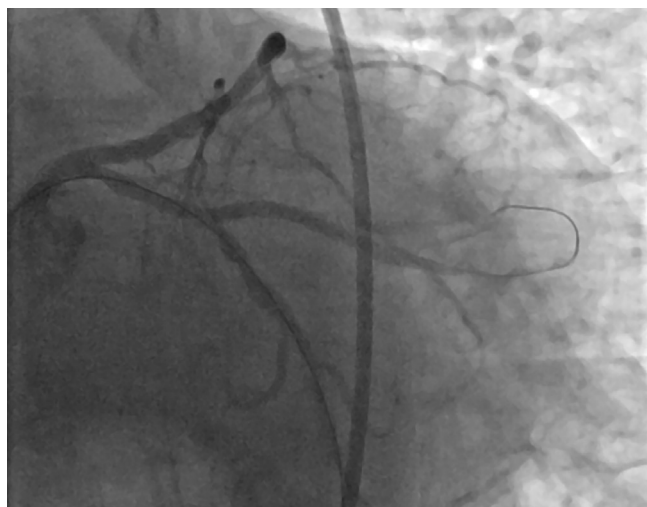

Figure 2.

[OP-18]**Distal Coronary Artery Perforations During Percutaneous Coronary Intervention and Their Management: Case Series**Rauf Avcı, Ahmet Genç, Oğuz Çiçekçibaşı*Clinic of Cardiology, University of Health Sciences Türkiye, Antalya Training and Research Hospital, Antalya*

Aim: Coronary artery perforations (CAP), which are rare but life-threatening complications during percutaneous coronary interventions (PCI), may particularly occur in distal segments due to guidewire manipulation. In this case series, we present cases in which autologous fat tissue embolization was used in distal CAP cases resistant to conservative methods.

Case Report: Case 1: A 45-year-old male patient developed guidewire-related Ellis Type II perforation during PCI for distal occlusion of the right coronary artery (RCA) with NSTEMI diagnosis. Despite prolonged balloon inflation, contrast extravasation persisted; therefore, autologous fat embolization was performed via a microcatheter, and the perforation was completely sealed. A proximal RCA dissection that developed during follow-up was successfully treated with stenting; no additional complications were observed. Case 2: In an 86-year-old male patient, guidewire-related Ellis Type III perforation occurred in the distal segment during RCA intervention. Balloon inflation failed to control the leakage. Embolization with fat particles obtained from subcutaneous tissue achieved complete angiographic success. Other coronary lesions were treated safely two days later. Case 3: A 79-year-old male patient underwent pericardiocentesis due to acute hemodynamic instability following circumflex artery (Cx) intervention. Distal Cx Ellis Type III perforation did not respond to balloon inflation, so autologous fat embolization was performed. Leakage was completely stopped; contrast-induced nephropathy resolved with medical treatment. Clinical and procedure-related characteristics and outcomes of the cases are shown. After angiographic confirmation of distal coronary artery perforation, the guidewire was advanced distally beyond the perforation, and the microcatheter was positioned approximately 10-15 mm proximal to the perforation. Autologous fat tissue was obtained from subcutaneous tissue via minimal skin incision, mixed with contrast material, and injected slowly and carefully through the microcatheter. Control angiography confirmed cessation of contrast extravasation.

Conclusion: Guidewire manipulation in distal coronary segments (<1 mm) is a significant risk factor for perforation. In small-caliber vessels where covered stents cannot be used, autologous fat embolization may be an effective alternative treatment option.

Keywords: Perforation, fat, embolization

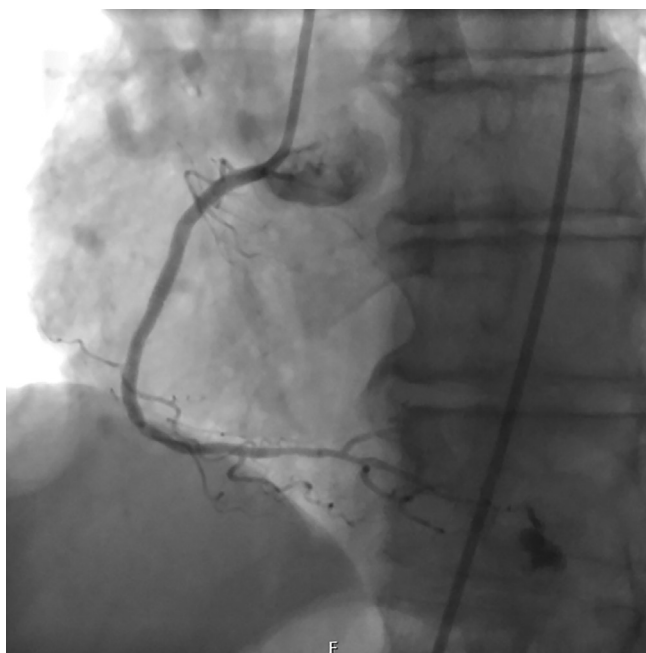


Figure 1. RCA distal perforation

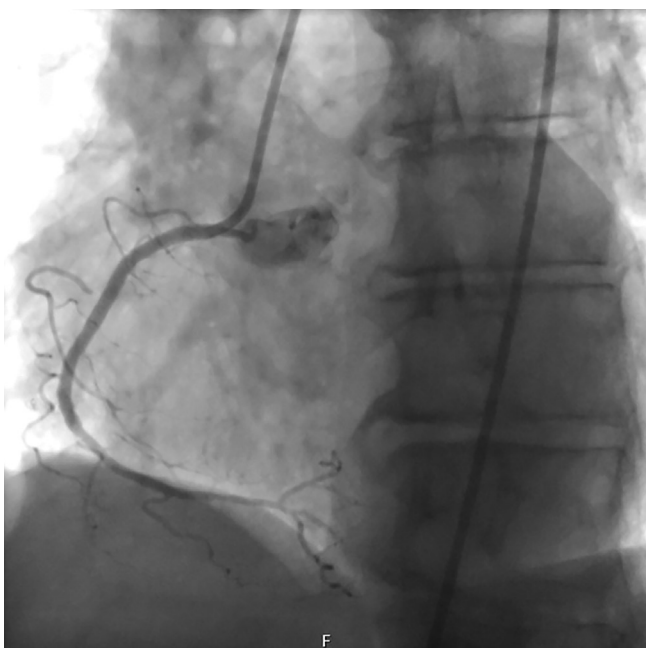

Figure 2. After autologous fat embolization

Table 1.

Feature	Case 1	Case 2	Case 3
Age/sex	45/male	86/male	79/male
Height (cm)	170	160	170
Weight (kg)	78	55	90
Clinical presentation	NSTEMI	Preoperative evaluation (before CEA)	Stable angina
Cardiovascular risk factors	DM, active smoker	Active smoker	HT, CAD, CKD
ECG findings	Sinus rhythm, no ST-T changes	Sinus rhythm, V4-V6 T (-)	Sinus rhythm, no ST changes
Echocardiography findings	EF 65%, normal	EF 60%, mild MR	EF 65%, mild MR
Target vessel	RCA	RCA	Cx
Lesion characteristics	Distal 100% occlusion	Mid 70% stenosis	80% critical stenosis
Guiding catheter used	JR 4	JR 4	EBU 3.5
Guidewire used	Floppy	Floppy	Floppy
Implanted stent	RCA proximal: 3.0×28 mm DES	RCA: 2.5×29 mm + 3.0×29 mm DES	Cx: 3.0×18 mm DES
Cause of perforation	Guidewire-related	Guidewire-related	Guidewire-related
Perforation type (Ellis)	Type II	Type III	Type III
Perforation location	Distal RCA	Distal RCA	Distal Cx
Initial intervention	Prolonged balloon inflation	Prolonged balloon inflation	Prolonged balloon inflation
Balloon inflation duration	15 min	15 min	10 min
Additional complication	Proximal RCA dissection	None	Cardiac tamponade
Pericardial effusion	Minimal	Minimal	Significant
Pericardiocentesis	No	No	Yes (500 cc)
Embolization method used	Autologous fat embolization	Autologous fat embolization	Autologous fat embolization
Microcatheter	Terumo Finecross®	Terumo Finecross®	Terumo Finecross®
Angiographic success	Complete sealing	Complete sealing	Complete sealing
In-hospital complication	None	None	Contrast nephropathy
Additional treatment	DES (for dissection)	Additional PCI (2 days later)	CVVH
Clinical follow-up outcome	Uneventful	Uneventful	Uneventful
1-month clinical follow-up	No symptoms	No symptoms	No symptoms

[OP-19]**Refractory and Catastrophic TIMI 0 No-Reflex Following Elective Left Anterior Descending (LAD) Intervention: A Case Presenting with Transient Severe Left Ventricular Dysfunction**

Muhammet Ali Ekiz, Ali Bağcı, Fatih Aksoy, Selim Süleyman Sert

Department of Cardiology, Süleyman Demirel University Faculty of Medicine, Isparta

Aim: The no-reflow phenomenon is defined as impaired perfusion at the distal microvascular level despite the achievement of mechanical patency in the epicardial coronary artery. Its pathophysiology involves distal embolization, microvascular spasm, endothelial injury, reperfusion injury, and platelet aggregation. Clinically, it is associated with myocardial injury, arrhythmia, hemodynamic instability, and increased mortality. No-reflow has been mostly reported during acute ST-elevation myocardial infarction (STEMI), whereas its occurrence following elective intervention in patients with stable angina pectoris is less common. Severe no-reflow cases developing during elective percutaneous coronary intervention (PCI) and progressing to TIMI 0 flow have been reported only in a limited number in the literature. In this report, we present a case of refractory no-reflow and transient severe left ventricular dysfunction following elective left anterior descending artery (LAD) intervention for stable angina.

Case Report: A 52-year-old male patient presented with retrosternal chest pain occurring with exertion and relieved by rest. His medical history was significant for diabetes mellitus (DM) and a prior cerebrovascular event. There was no known history of cardiac disease. On admission electrocardiography, sinus rhythm was observed, and no signs of acute ischemia were detected. Cardiac troponin levels were negative. Transthoracic echocardiography revealed a left ventricular ejection fraction (EF) of 65%. Coronary angiography demonstrated a diffuse long-segment lesion extending from proximal to distal LAD with a maximum stenosis of 99% at its narrowest point (Figure 1). The patient's SYNTAX score was calculated as 18, and elective percutaneous coronary intervention was planned. A drug-eluting stent (DES) appropriate for the vessel diameter was implanted. Following stent implantation, control angiography revealed sudden development of TIMI 0 flow in the distal LAD. Simultaneously, ST-segment elevation was observed in the anterior leads. The patient developed marked hypotension (blood pressure: 70/40 mmHg) and short episodes of pulsed ventricular tachycardia were noted. Considering the no-reflow phenomenon, intracoronary adenosine (50 mcg, two doses) was administered. As no improvement in flow was observed, intracoronary adrenaline was administered sequentially at doses of 50 mcg, 100 mcg, and 150 mcg. The no-reflow phenomenon was noted to progress more proximally. Tirofiban infusion was initiated, and thrombus aspiration was performed. Due to persistent impaired flow, intracoronary alteplase (12.5 mg, two doses) was administered; however, TIMI 0 flow progressed up to the LMCA and Cx ostial region (Figure 2). Despite all interventions, hemodynamic instability persisted for approximately 25 minutes. Subsequently, sequential post-dilatations were performed, resulting in TIMI 1 flow. After repetition of medical therapies, final angiography demonstrated TIMI 3 flow. Echocardiography performed on the first post-procedural day showed an EF of 35-40% and anterior wall hypokinesia. After two days of follow-up in the coronary intensive care unit, the patient was transferred to the ward. On the fifth day, follow-up echocardiography revealed an EF of 60%, and the patient was discharged on dual antiplatelet therapy. This case demonstrates severe and refractory no-reflow phenomenon following elective LAD intervention in a patient with stable angina pectoris. Although no-reflow is generally associated with acute coronary syndromes and high thrombus burden, it may also develop in stable patients, particularly in the presence of long and diffuse lesions, due to distal microembolization. The presence of DM is also a predisposing factor for microvascular dysfunction. Early and aggressive management is critical for prognosis once no-reflow develops. While adenosine provides microvascular vasodilation, adrenaline may offer inotropic support and improve microvascular flow in cases of severe hypotension. Tirofiban and intracoronary fibrinolytic therapy

were administered to reduce distal thrombotic burden. With a multimodal approach, epicardial flow was restored, and left ventricular function showed marked recovery.

Conclusion: Severe no-reflow occurring during elective percutaneous coronary intervention in patients with stable angina pectoris is a rare but potentially life-threatening complication. With early diagnosis, rapid hemodynamic support, and a multimodal intracoronary treatment approach, myocardial injury may be reversible, and left ventricular function may fully recover.

Keywords: Microvascular obstruction, no-reflow phenomenon, percutaneous coronary intervention (PCI), stable angina pectoris, total coronary flow loss

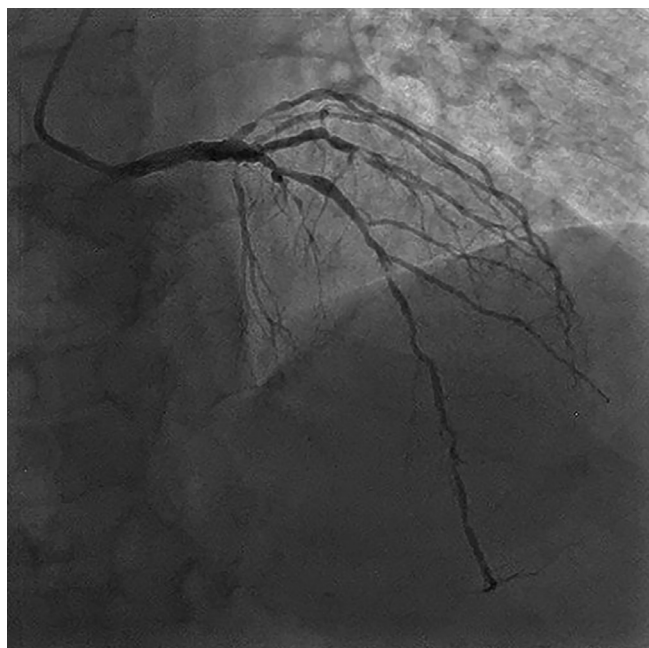

Figure 1.

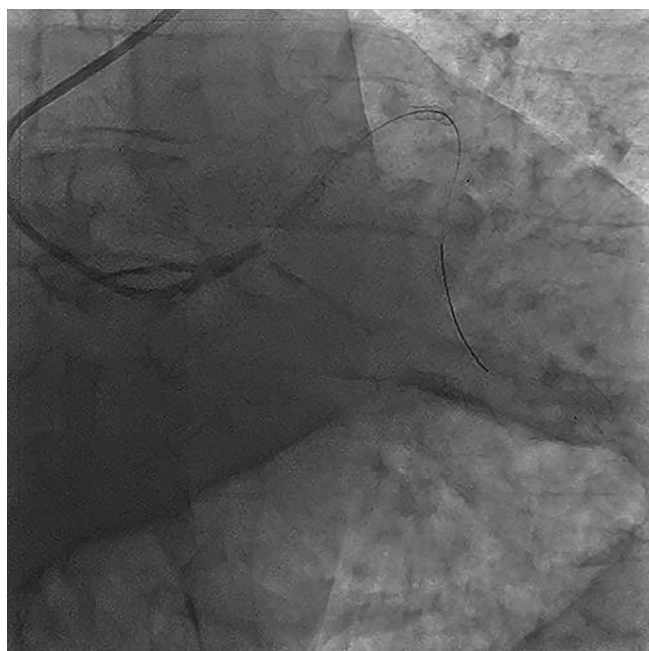


Figure 2.

[OP-21]**IVUS-Guided LMCA-LAD PCI Complicated by Guidewire Fracture Successfully Managed with Bailout Reverse Crush Stenting**

Behice Hande Sışman Uzunođlan¹, Sezgin Uzunođlan¹, Ođuzhan Abanoz², Esra Daniřman², Mahmut Uluganyan²

¹Kırklareli Training and Research Hospital, Kırklareli

²Bezmialem Vakıf University Hospital, İstanbul

A 72-year-old male with stable angina pectoris and a history of hypertension and benign prostatic hyperplasia was evaluated. Laboratory findings were unremarkable except for LDL 153 mg/dL. ECG showed normal sinus rhythm. Echocardiography revealed preserved left ventricular systolic function (EF 60%) with mild mitral regurgitation and grade 1 diastolic dysfunction. Coronary angiography demonstrated 70% LMCA stenosis. Intravascular ultrasound (IVUS) confirmed up to 80% luminal narrowing involving the LMCA with ostial LAD plaque. Heart team discussion favored PCI. After wiring the LAD, circumflex (Cx), and intermediate (IM) branches, LMCA-to-LAD predilatation was performed followed by implantation of a 4.0×30 mm drug-eluting stent (DES). Proximal optimization technique (POT) was performed with a 5.0×15 mm non-compliant balloon. Control IVUS revealed distal edge dissection, which was treated with an overlapping 3.0×12 mm DES and further post-dilatation. During device withdrawal, the IM guidewire fractured. Attempts to retrieve the retained wire fragment in the aorta using a snare were unsuccessful. A decision was made to crush the retained segment with a stent. The IM branch was rewired, predilated, and a 2.75×15 mm DES was implanted with minimal protrusion into the LAD. A bailout crush technique was performed, followed by rewiring of the IM branch, sequential ostial dilatations, kissing balloon inflation (IM 2.75 mm/LAD 4.0 mm), and final POT with a 5.0 mm non-compliant balloon. Final angiography demonstrated optimal expansion and TIMI 3 flow without residual stenosis or complications. Patient were free of anginal symptoms at 3 months follow-up.

Keywords: Coronary angiography, complication, guidewire fracture

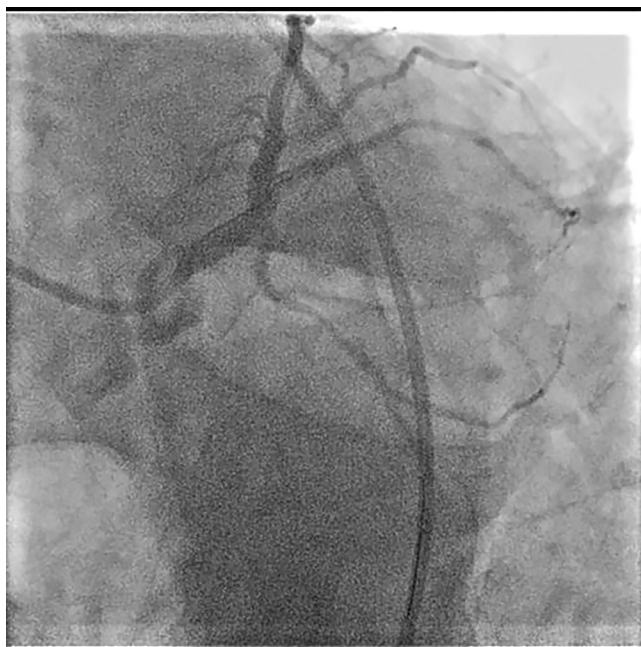

Figure 1. Final image

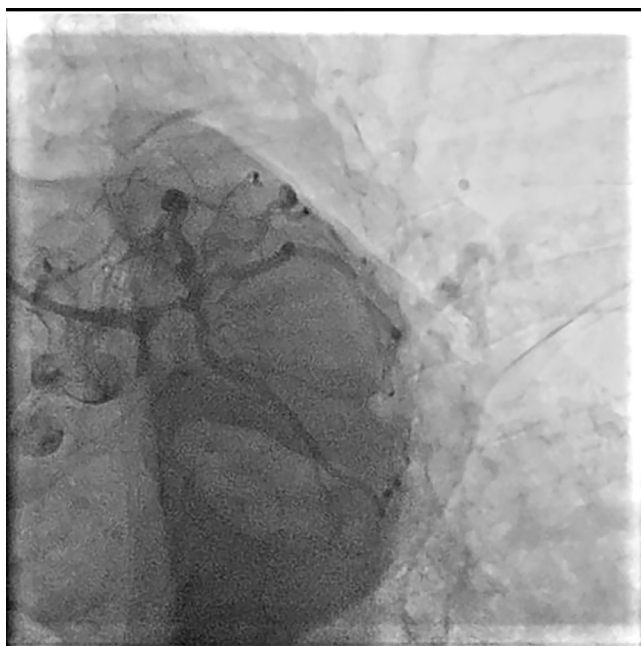


Figure 2. First spider view

[OP-22]**The Simple the Better: A Successful Case of the Trifurcation PCI**

Esra Danışman¹, Oğuzhan Abanoz¹, Lina Boukhemis¹, Kamran Kerimzade¹, Behice Hande Şişman Uzunoğlu², Sezgin Uzunoğlu², Mahmut Uluganyan¹

¹Bezmialem Vakıf Üniversitesi Hastanesi, İstanbul

²Kırklareli Eğitim ve Araştırma Hastanesi, Kırklareli

A 65-year-old male with hypertension and diabetes mellitus presented with occasional chest pain on exertion and a prior ED admission with hypertensive crisis. Coronary angiography performed at an external center revealed a complex left main (LM) trifurcation lesion, and the patient was referred to our institution for percutaneous coronary intervention (PCI) following heart team evaluation. Baseline assessment showed sinus rhythm on ECG and preserved left ventricular systolic function (EF 60%) without significant valvular disease on echocardiography. PCI was performed via radial access using a provisional single-stent strategy. After wiring all three branches (LAD, circumflex, and intermediate), lesion preparation was followed by IVUS-guided stenting from the LAD into the LMCA. Proximal optimization technique (POT) was applied to ensure adequate stent expansion within the LM. The intermediate branch was treated with balloon angioplasty after rewiring, followed by kissing balloon inflation. The circumflex artery was also managed without stent implantation, using a drug-coated balloon approach to minimize metal burden. Final optimization included triple kissing balloon inflation to ensure optimal flow distribution across all three branches. Intravascular imaging confirmed satisfactory stent expansion and apposition. Final angiography demonstrated excellent result with preserved patency of all branches and TIMI 3 flow. In selected patients with LM trifurcation disease, a provisional single-stent strategy combined with drug-coated balloon treatment for side branches and comprehensive kissing balloon optimization may provide an effective revascularization approach while minimizing stent burden and procedural complexity.

Keywords: Trifikasyon, kissing PTCA, POT, IVUS

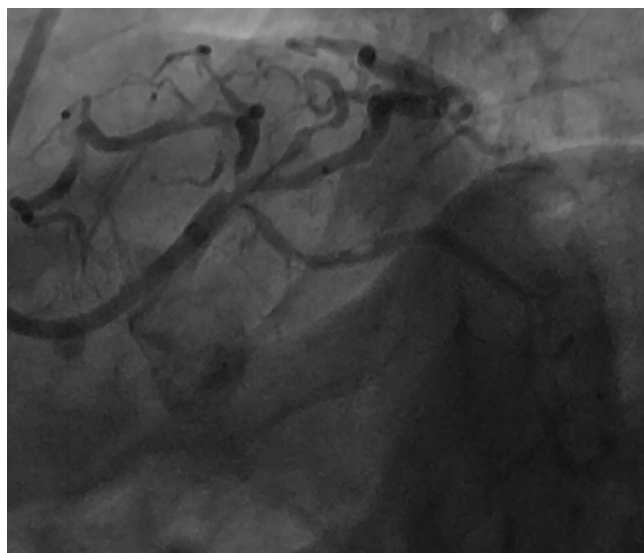


Figure 1.

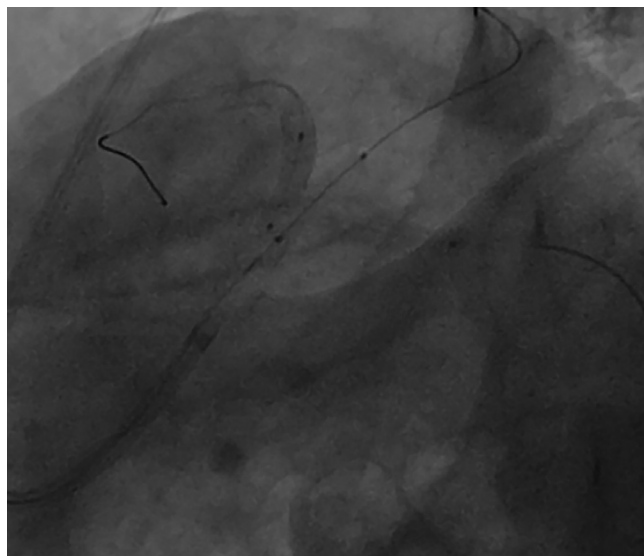


Figure 2.

[OP-23]**LAD and Diagonal Myocardial Bridge Passing Through the Parallel Muscle Band**

Beytullah Kulac, Ferit Büyük, İlker Duman, Harun Akarsu, Aysun Karahan, İsmail Polat Canbolat, Bilal Çuğlan

Clinic of Cardiology, University of Health Sciences Türkiye, Kanuni Sultan Süleyman Training and Research Hospital, İstanbul

66-year-old male patient. Echocardiography: EF 60%, all heart chambers of normal size, degenerative changes present in the aortic and mitral valves. Mild AY, Mild My PAB: 26 mmHg. Biochemistry: Hgb: 13.5 g/dL, creatinine: 0.95 mg/dL, Pro Bnp: 106 ng/L, HbA1C: 5.7. The patient, who presented with Polk's angina, was admitted to the ward for CAG (cardiovascular angiography) due to a suspiciously positive stress test result and a previous CAG performed in 2014. A severe myocardial bridge causing 90-95% diastolic stenosis was observed in coronary artery intervention (CAG) performed via the right radial artery. A cranial angle of 45 degrees revealed a myocardial bridge in the mid-region of the diagonal branch 1 (D1) and parallel to the mid-region of the LAD, causing 90-95% diastolic stenosis.

Keywords: Myocardial bridge, LAD and diagonal myocardial bridge, parallel muscle band bridge

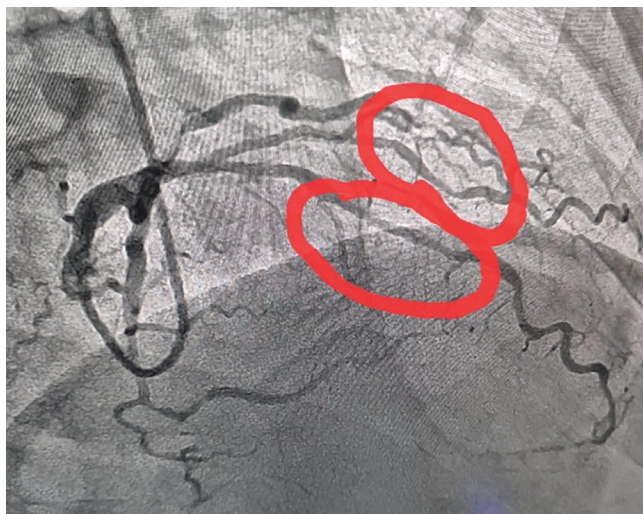


Figure 1.

[OP-24]**Successful Left Main Coronary Artery Bifurcation Intervention with DoubleKissing-Mini Crush Method and Intravascular Ultrasonography Assistance**

Abdullah Özçelik

Mardin Training and Research Hospital, Mardin

Critical left main coronary artery (LMCA) disease is a very high-risk subgroup of coronary artery disease and a critical indicator of increased morbidity and mortality rates. Despite its clinical significance, uncertainties remain regarding the optimal treatment strategy for patients, particularly given the phenotypic variations. While coronary artery bypass graft (CABG) was previously considered the only treatment option, today, with advancements in percutaneous intervention techniques and materials, percutaneous coronary intervention (PCI) has become a significant and powerful option for LMCA lesions. Although current evidence-based guidelines provide information on revascularization options, questions remain regarding long-term prognostic and clinical outcomes when comparing percutaneous coronary intervention with coronary artery bypass grafting. Intravascular ultrasonography (IVUS) can be used to characterize the lesion in more detail when left main artery stenosis is unclear, or to evaluate apposition after stent implantation. ESC guidelines recommend classifying patients using the SYNTAX score to predict outcomes prior to PCI. In patients with a low SYNTAX score (0-22), both PCI and CABG are recommended as class I procedures. In patients with an intermediate SYNTAX score (23-32), CABG is recommended as a class I procedure, while PCI is recommended as a class IIa procedure. Finally, in patients with a SYNTAX score ≥ 33 and significant LMCA lesions, CABG remains a class I recommendation, while PCI is not recommended. Management and phenotypic presentation of LMCA disease in elderly patients (age >75) require special attention. Elderly patients generally have reduced physiological reserves, which makes them more susceptible to the hemodynamic consequences of left main artery disease, including myocardial infarction. Older patients tend to experience higher rates of complications and mortality, as well as worse postoperative outcomes, after cardiac procedures. Therefore, in older patients, since the risk of CABG is higher, PCI may be a better option. Our case was a 75-year-old male patient with a known diagnosis of diabetes, coronary artery disease, and hypertension. The patient underwent RCA PCI procedure for acute inferior myocardial infarction. CABG has been recommended for LMCA-LAD-Cx lesions. Since the patient refused surgery, PCI was planned. The patient's Syntax 2 score was assessed as 25. A sheath was placed via the right femoral approach, and the LAD and Cx were treated with double wires. The lesions were predilated, and the LAD, Cx, and LMCA bifurcation lesions were stented using the DK-mini crus method. Post-dilatation was performed. Postoperative IVUS was used for monitoring. It was observed that the stents in all three coronary arteries were appositioned and adequate patency was achieved. The procedure was successfully completed. In conclusion, as seen in our case, PCI as an important and successful alternative method for patients with LMCA lesions who have a low syntax score, high surgical risk, or who refuse surgery.

Keywords: LMCA, bifurcation, IVUS, syntax score, DK-crush

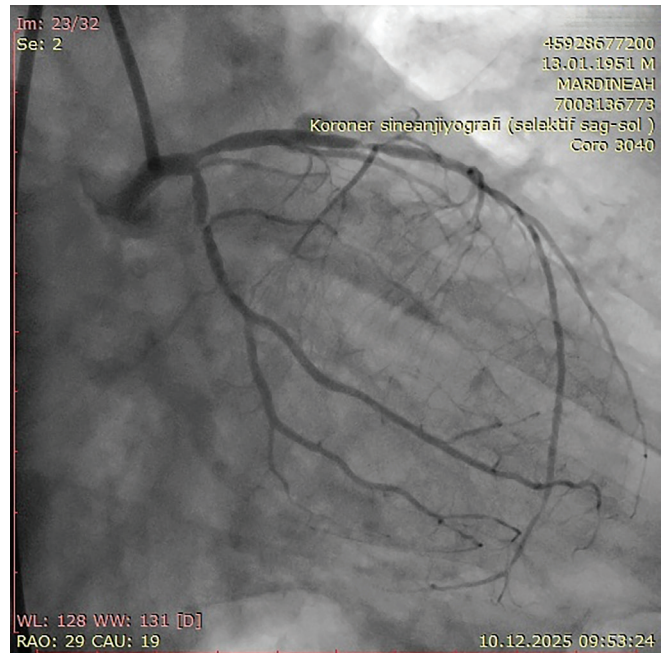


Figure 1. Basal caudal view

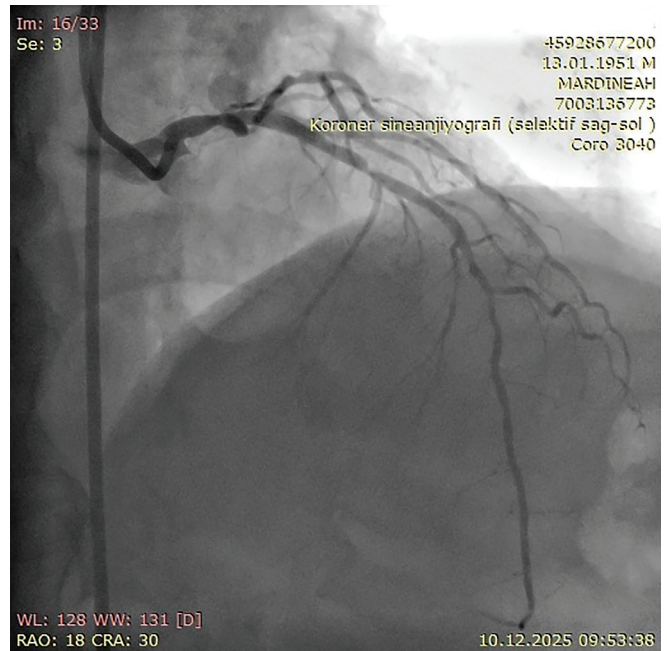


Figure 2. Basal cranial image

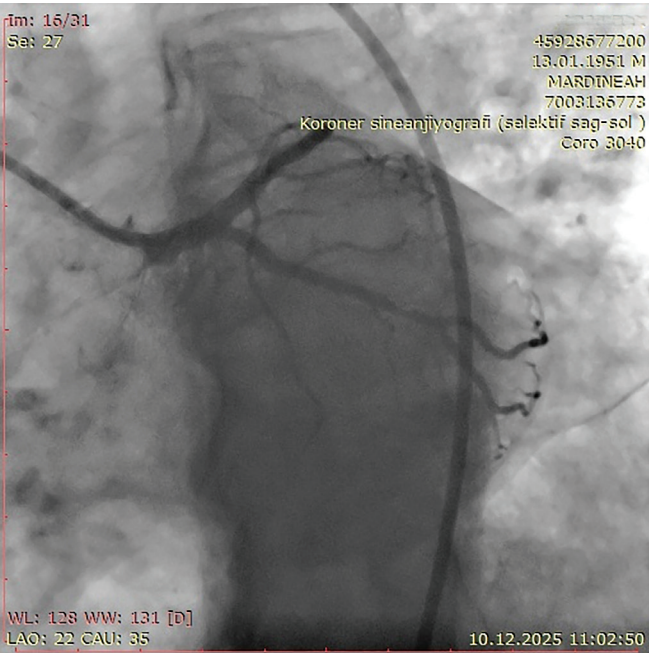


Figure 3. Final image

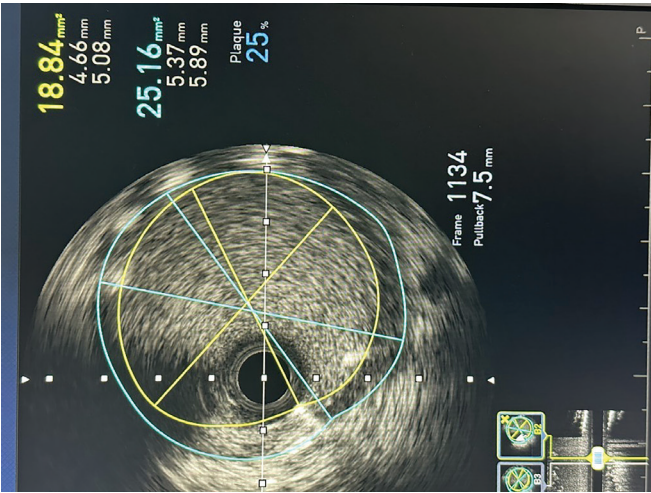


Figure 4. Final IVUS (intracoronary ultrasonography) image

[OP-25]**Successful Revascularization of a Severely Calcified Right Coronary Artery Ostial Lesion with Cutting Balloon Support**

Abdullah Özçelik

Clinic of Cardiovascular Diseases, Mardin Training and Research Hospital, Mardin

Stenosis located in the first 3 mm segment from the origin of the coronary arteries is classified as ostial lesions. Generally, these can be categorized into two classes: Aorta-ostial lesions: These include lesions at the origin of the right coronary artery (RCA) and the left main coronary artery (LMCA), or at the aorto-coronary saphenous graft ostium. Non-aorta-ostial lesions: These include lesions at the ostium of the left anterior descending artery (LAD) and the circumflex artery (Cx). Procedures for ostial coronary lesions are a part of complex percutaneous coronary interventions (PCI). Due to the characteristic features of the lesion structure, the success rate of the procedure is lower compared to other coronary interventions, while the rates of early and late complications are higher. Although the general principles in these cases are the same as in other coronary interventions, the techniques and equipment may differ. Complications such as coronary dissection, loss of guide catheter position, stent malposition, excessive protrusion of the stent into the aorta or related major vessel, and stent placement too distal to the ostium are more common in ostial coronary calcific lesions. Avoiding oversizing and performing careful post-dilatation can reduce the risk of dissection. Loss of guide catheter position can also be prevented by using an auxiliary wire. In calcified lesions, stent malposition can be minimized by using debulking techniques such as cutting balloon and rotational atherectomy during the lesion preparation phase. Stent protrusion can be prevented by avoiding foreshortening or by using stent implantation methods such as tail-wire or pull-back techniques. Our case is a 68-year-old male patient with a diagnosis of diabetes and hyperlipidemia. He had severe calcified stenosis of the RCA ostial region (Figure 1). The lesions were treated with floppy wire and extra support wire. During case preparation, fluoroscopy and intravascular ultrasonography (IVUS) were used to evaluate the calcified lesion. Initially, IVUS did not penetrate the lesion. Evaluation was performed with IVUS after balloon predilatation. The calcified area was dilated with a cutting balloon (Figure 2). Subsequently, drug-eluting stents were placed, extending 1 mm from the ostium into the aorta (Figure 3). Finally, a repeat evaluation with IVUS was performed, and the procedure was successfully completed. Ultimately, obtaining detailed information about the structure of the lesion at the ostial is crucial for achieving the best results from interventional treatment of ostial coronary lesions. For that, a complete anatomical and physiological evaluation of the lesion is essential. Dissection and inadequate stent expansion are frequently observed; this can be overcome with pre-stent preparation of the lesion. The stent used should be drug-eluting and should adequately cover the stent ostium for minimal restenosis. Preparation should be made for complications that may arise during the procedure, and they should be managed quickly with the ideal technique.

Keywords: Ostial lesion, calcific lesion, IVUS, cutting balloon

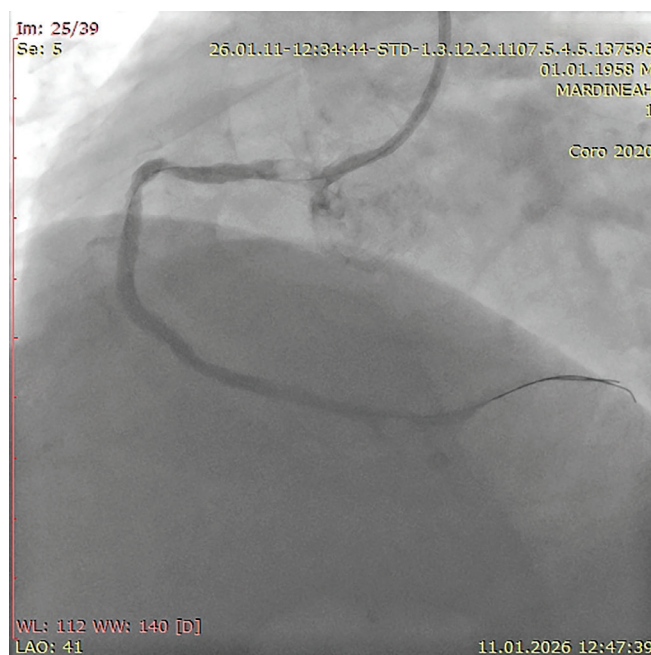


Figure 1. Baseline RCA image

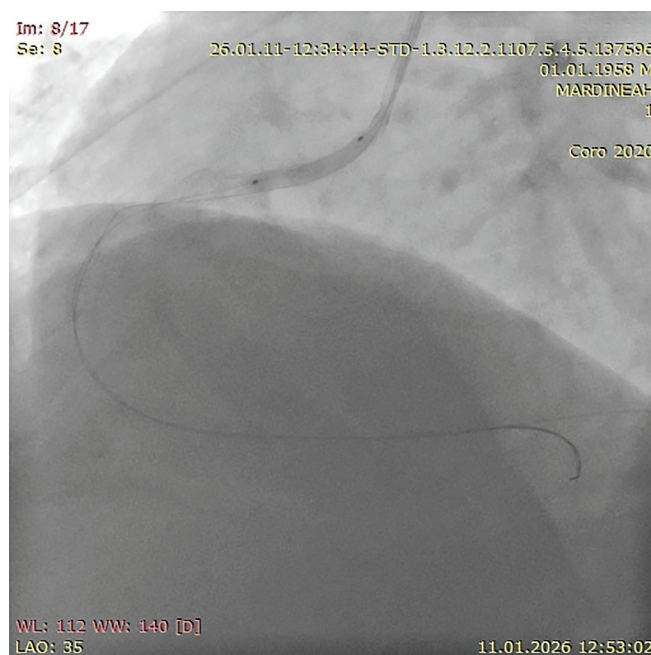


Figure 2. Dilatation of the lesion with cutting balloon

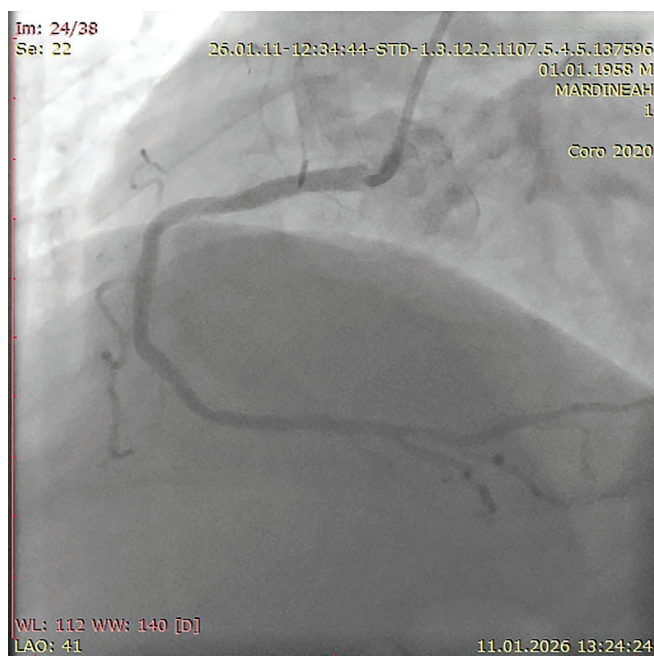


Figure 3. Final image of calcific ostial lesion

[OP-28]

Successful Covered Stent Strategy for Ellis Type III LAD Perforation Complicating Percutaneous Coronary Intervention

Sezgin Uzunođlan¹, Behice Hande Şişman Uzunođlan¹, Ođuzhan Abanoz², Esra Danışman², Mahmut Uluganyan²

¹Clinic of Cardiology, Kırklareli Training and Reserarch Hospital, Kırklareli

²Department of Cardiology, Bezmialem Vakıf University Hospital, Istanbul

A 65-year-old female with a history of ischemic cerebrovascular disease and hypertension presented with chest pain. Blood pressure was 160/105 mmHg. No ischemic changes observed in electrocardiography. Echocardiography showed preserved left ventricular systolic function (EF 60%) with grade 1 diastolic dysfunction. Coronary angiography revealed significantly calcific and long lesion in LAD lesions. There is also critical lesions in D1, Cx and RPL. Heart team evaluation concluded high risk percutaneous coronary intervention. After lesion crossing with a floppy wire, sequential predilatation was performed, followed by implantation of a 3.0×38 mm drug-eluting stent (DES) in the distal LAD and post-dilatation with a non-compliant balloon. Subsequent angiography demonstrated contrast extravasation at the D2 level consistent with Ellis type III perforation. Due to prolonged balloon tamponade failure to seal perforation 3.0×20 mm covered stent implantated and successfully sealed the perforation. However, pericardial effusion developed, necessitating emergent pericardiocentesis. After succesful pericardiocentesis and autotransfusion patient hemodynamic parameters recovered immediately. We planned to treat LAD D1 bifurcation lesion with double kissing crush (DK-crush) technique but considering complexity of procedure LAD was subsequently treated with DES implantation using a provisional strategy. Shortly after the procedure, the patient developed recurrent chest pain with new ST-segment elevation in anterior and lateral leads, most prominent in V2. Repeat angiography demonstrated a hazy image at the covered stent segment, suggestive of acute stent-related complication. A 4.0×12 mm DES was implanted with high-pressure post-dilatation, restoring TIMI 3 flow and complete angiographic patency.

Keywords: Angiography, calcification, coronary rupture

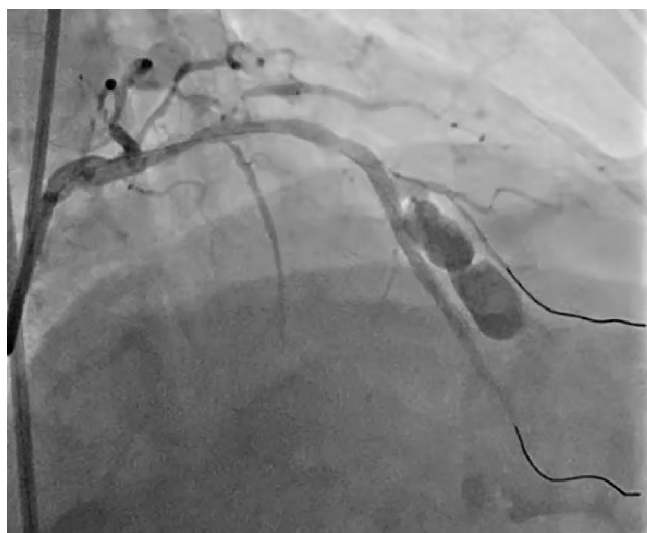


Figure 1. Ellis type III coronary rupture

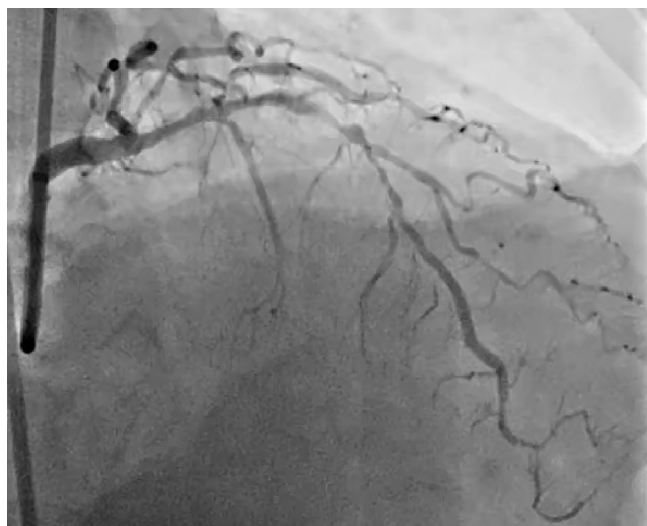


Figure 2. First cranial image

[OP-29]**Relationship Between NAPLES Score and Syntax Score and Short-term Mortality in Patients with Coronary Artery Disease**Gülüzar Traş¹, Emre Paçacı²¹Department of Cardiology, University of Health Sciences Türkiye, Mersin City Hospital, Mersin²Department of Cardiology, University of Health Sciences Türkiye, Osmaniye Training and Research Hospital, Osmaniye

Aim: Risk stratification in cardiovascular diseases is of critical importance in determining treatment strategies. The NAPLES score (a scoring system including parameters such as neutrophil-to-albumin ratio and Platelet-to-Lymphocyte ratio) is a new prognostic indicator reflecting inflammatory and nutritional status. This study aims to evaluate the relationship between the NAPLES score and demographic characteristics, coronary artery disease burden (Syntax score), and mortality in patients followed at our center.

Methods: Data from 933 patients included in the study were analyzed retrospectively. The following patient data were recorded:

- Demographic data,
- Comorbidities (DM, HT, hyperlipidemia, smoking),
- Echocardiographic findings (EF),
- Angiographic scores (Syntax).

The NAPLES score was categorized between 0 and 4, and the relationship between score groups and clinical results (mortality and Syntax score) was analyzed.

Results: The analyses yielded the following data:

3.1. Demographic characteristics and risk factors

The mean age of the patients was 61.2. Gender distribution showed a predominance of male patients (75.9% male, 24.1% female).

3.2. Clinical and angiographic data

- The majority of patients were in the NAPLES 3 (282 patients) and NAPLES 2 (217 patients) groups. Mortality rates: A trend of increasing mortality rates was observed as the NAPLES score increased. The highest mortality was found in the NAPLES 4 group at 17.3%.

- Clinical relationship: While the Syntax score reached its highest average in the NAPLES 3 group (14.4), mortality was most significant in the NAPLES 4 group.

Conclusion: The study indicates that the NAPLES score is closely related to both anatomical complexity (Syntax score) and long-term survival in individuals with coronary artery disease. A NAPLES score of 3 or higher points to a higher-risk patient group. This system can be used in clinical practice as a low-cost and easily accessible risk assessment tool.

Keywords: Syntax score, NAPLES score, coronary artery disease, mortality

Table 1. General demographic data

Demographic data	Value/rate
Mean age	61.2
Gender	75.9% male/24.1% female
Hypertension (HT)	53.7%
Diabetes (DM)	37.8%
Smoking	54.1%
Hyperlipidemia (HL)	16.8%
Ejection fraction (EF)	47.1%
Mean Syntax score	9.4
General mortality rate	12.8%

Table 2. NAPLES score comparison

NAPLES score	Number of patients (n)	Mean Syntax score	Mortality rate (%)
Score 0	107	6.1	4.7%
Score 1	132	7.4	6.8%
Score 2	217	6.9	12.4%
Score 3	282	14.4	16.0%
Score 4	195	7.3	17.3%

[OP-30]**Long-term Clinical Course After Complex Coronary Bifurcation Stenting: Was the Initial Strategy Appropriate?**

Oğuz Kaan Kaya

Department of Cardiology, University of Health Sciences Türkiye, Antalya Training and Research Hospital, Antalya

Aim: The choice of initial interventional strategy in coronary bifurcation lesions not only determines immediate angiographic success but also significantly influences long-term clinical outcomes. Contemporary guidelines recommend a provisional stenting strategy as the default approach, reserving two-stent techniques for selected complex anatomies.

Case Report: A male patient without diabetes mellitus or hypertension presented with exertional angina in 2017. Coronary angiography revealed a significant circumflex-obtuse marginal (Cx-OM) bifurcation lesion, and percutaneous coronary intervention was performed using the TAP (T-stenting and small protrusion) technique. During follow-up, the patient experienced recurrent chest pain. Coronary angiographies in 2018 and 2019 demonstrated in-stent plaque formation in the Cx artery without critical stenosis or

thrombosis, and the patient was managed conservatively with optimal medical therapy. In July 2019, due to approximately 70% in-stent restenosis, balloon angioplasty, final kissing balloon inflation, and proximal optimization technique (POT) were performed. In August 2020, recurrent critical restenosis required implantation of a long stent extending from proximal to distal Cx. Mild plaque shift at the OM ostium was observed, although TIMI 3 flow was preserved. In November 2022, the patient presented again with chest pain. Angiography revealed patent main vessel stents but thrombus formation at the OM ostium. A 24-hour tirofiban infusion was administered. Control angiography showed approximately 90% restenosis at the Cx-OM segment; however, due to clinical stability and preserved flow, no further intervention was performed, and optimal medical therapy was continued. In April 2024, the patient presented with exertional angina. Myocardial perfusion scintigraphy was normal, and no revascularization was indicated. Medical therapy was intensified with ranolazine and colchicine.

Conclusion: This case illustrates that complex bifurcation stenting without functional or intravascular imaging guidance may lead to increased stent burden, restenosis, and late thrombotic complications. A physiology- and imaging-guided, stepwise provisional approach may reduce long-term adverse events, as emphasized in contemporary bifurcation PCI literature. Functional assessment (e.g., FFR) and intravascular imaging (e.g., IVUS) should be considered to optimize strategy selection in bifurcation PCI. The initial strategy in bifurcation lesions remains a key determinant of long-term clinical outcomes.

[OP-31]**Primary Percutaneous Coronary Intervention Using a Mirror-image Angiographic Approach in Acute Inferior ST-segment Elevation Myocardial Infarction in a Patient with Dextrocardia**

Ali Bayraktar, Büşra Tozlu

University of Health Sciences Türkiye, Sancaktepe Şehit Prof. Dr. İlhan Varank Training and Research Hospital, İstanbul

Dextrocardia is a rare congenital cardiac anomaly characterized by the location of the heart in the right hemithorax and is frequently associated with situs inversus. Although the prevalence of coronary artery disease is comparable to that in the general population, the mirror-image anatomical orientation of the heart may create diagnostic and technical challenges during electrocardiographic evaluation and interventional procedures. Electrocardiographic findings in dextrocardia may include right axis deviation, global negativity in lead I, and loss of normal R-wave progression in the precordial leads, which can complicate the evaluation of acute myocardial infarction. In this case report, a 53-year-old male patient presented to the emergency department with acute-onset chest pain. His medical history was notable for known dextrocardia, and active cigarette smoking was identified as a cardiovascular risk factor. Electrocardiography obtained at presentation demonstrated ST-segment elevation in the inferior leads, and the patient was referred emergently to the catheterization laboratory for coronary angiography with a diagnosis of acute inferior ST-segment elevation myocardial infarction. Coronary angiography revealed a thrombotic total occlusion of the right coronary artery. Primary percutaneous coronary intervention was successfully performed, achieving effective revascularization. During the procedure, catheter manipulation and fluoroscopic imaging were performed according to a mirror-image approach because of the reversed cardiac anatomy. The diagnosis and interventional management of acute coronary syndromes in patients with dextrocardia may be challenging because of anatomical variations. In the literature, experience with percutaneous coronary intervention in this patient population has been limited to a small number of case reports. This case highlights that accurate interpretation of electrocardiographic findings and the application of a mirror-image interventional approach are of critical importance for successful revascularization in patients with dextrocardia presenting with acute myocardial infarction.

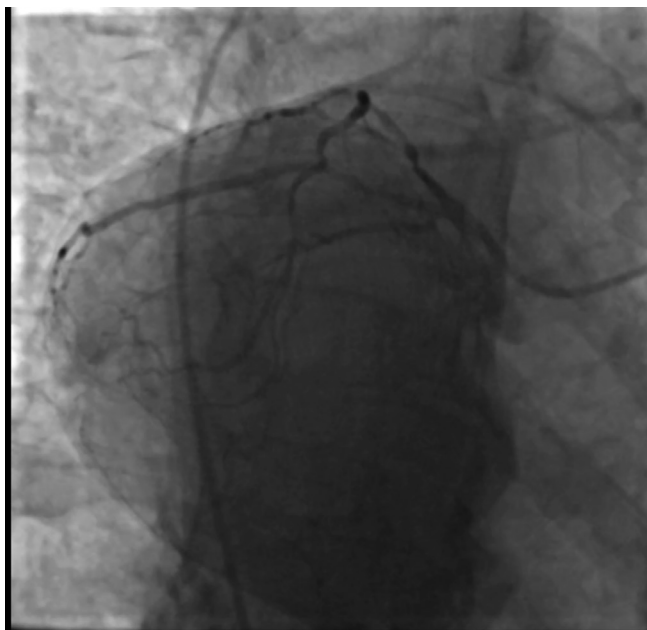


Figure 1. Coronary angiographic image of the left coronary system in a patient with dextrocardia, demonstrating the mirror-image anatomical orientation of the coronary arteries

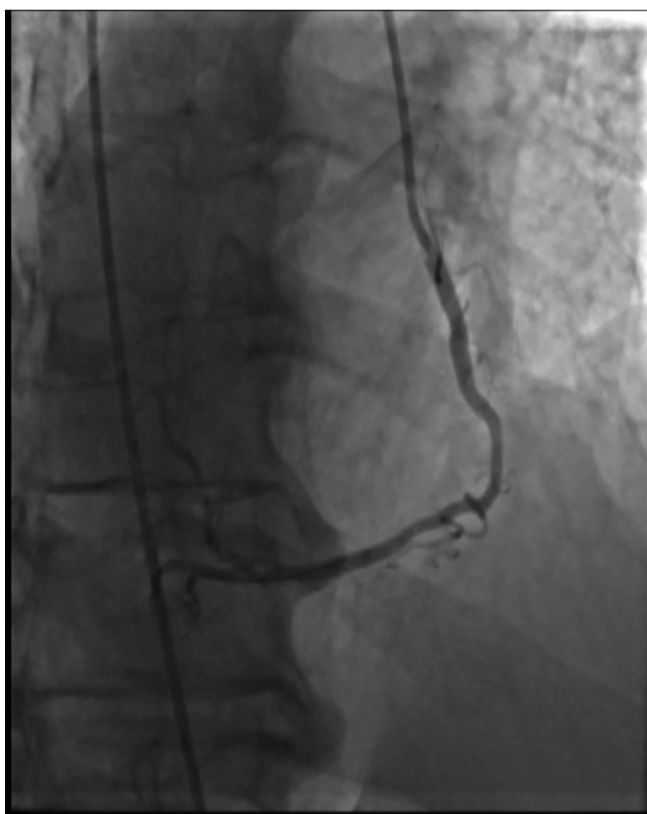


Figure 2. Coronary angiographic visualization of the right coronary artery in a patient with dextrocardia

[OP-32]**Complex Bifurcation with Concomitant Coronary Anomaly:
Double DK Crush Technique**

Esra Danışman¹, Oğuzhan Abanoz¹, Lina Boukhemis¹, Kamran Kerimzade¹, Behice Hande Şişman Uzunoğlu², Sezgin Uzunoğlu², Mahmut Uluganyan¹

¹Department of Cardiology, Bezmialem Vakıf University Hospital, Istanbul

²Clinic of Cardiology, Kırklareli Training and Research Hospital, Kırklareli

An 81-year-old male presented with chest pain and underwent coronary angiography, which revealed complex bifurcation lesions involving the left anterior descending artery (LAD) and first diagonal branch (D1), as well as an anomalous circumflex artery (Cx) with obtuse marginal (OM) bifurcation disease. Electrocardiography showed sinus rhythm with anterior T-wave inversions at a heart rate of 80 bpm. Transthoracic echocardiography demonstrated preserved left ventricular systolic function (ejection fraction 60%) without significant valvular pathology. Percutaneous coronary intervention (PCI) was performed via right radial access using a 7F guiding catheter. The LAD-D1 bifurcation was treated using an intravascular ultrasound (IVUS)-guided double kissing (DK) crush technique. After lesion preparation with balloon angioplasty, a drug-eluting stent (DES) was deployed in D1 with minimal protrusion into the LAD, followed by crushing and rewiring. Sequential kissing balloon inflations were performed, and a DES was subsequently implanted in the LAD with proximal optimization technique (POT). Final kissing balloon inflation and IVUS confirmed optimal stent expansion and apposition with full patency. The anomalous Cx-OM bifurcation lesion was then treated using a similar DK-crush strategy. Following predilation and IVUS assessment, a DES was implanted in the Cx, crushed, and rewired. Kissing balloon inflations were performed, followed by stenting from Cx to OM. Final POT and kissing balloon inflations were applied. IVUS confirmed adequate expansion and complete lesion coverage with restoration of vessel patency. The procedure achieved successful revascularization of both complex bifurcation lesions without immediate complications. The patient remains under close cardiology follow-up.

Keywords: Anomalous circumflex artery, bifurcation lesion, DK crush technique, IVUS-guided PCI, drug-eluting stent

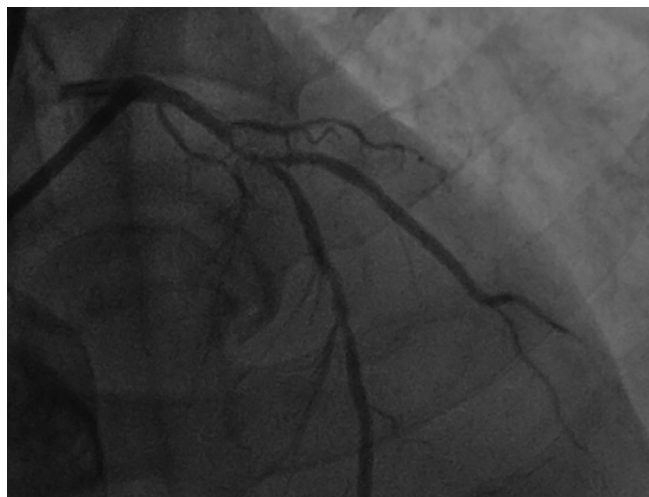

Figure 1.

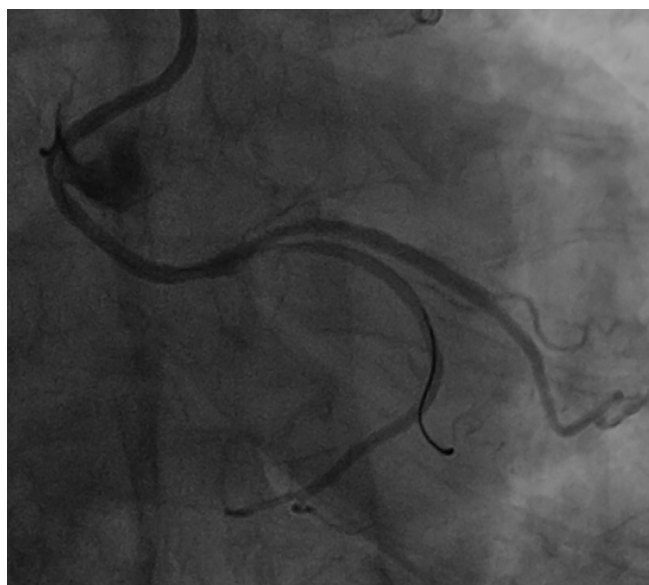


Figure 2.

[OP-34]**Angiographically Occult Retained Guidewire Missed on Repeated Angiographic Evaluations**

İrem Bilge Erkarakoç¹, Ahmet Onur Çelik², Fethi Emre Ustabasıoğlu², Servet Altay¹

¹Department of Cardiology, Trakya University Faculty of Medicine, Edirne

²Department of Radiology, Trakya University Faculty of Medicine, Edirne

Aim: Guidewire entrapment and fracture are rare but clinically relevant complications of percutaneous coronary intervention (PCI). Although typically recognized during the procedure, retained intravascular material may occasionally remain undetected, particularly when it exhibits low radiopacity or an atypical anatomical course.

Case Report: A 55-year-old male with coronary artery disease presented with unstable angina. Coronary angiography demonstrated significant left anterior descending artery (LAD), circumflex (CX) and Right coronary artery (RCA) stenoses (Figure 1A, B). Initial intervention involved LAD stenting with kissing balloon angioplasty to the diagonal branch (Figure 1C). However, following stent implantation, a dissection was observed, and the LAD-diagonal bifurcation procedure was completed using the crush technique (Figure 1D). CX lesions were treated with DES implantation (Figure 1E). Due to persistent angina, repeat angiography demonstrated patent LAD and CX stents (Figure 1F, G) but severe distal RCA stenosis, which was successfully treated with DES implantation (Figure 1H, I). Importantly, final angiographic images after each procedure, as well as repeated control angiograms, did not demonstrate any intravascular abnormality. During follow-up, the patient developed persistent chest and back pain, raising suspicion for aortic pathology. Contrast-enhanced thoracic CT excluded aortic dissection; however, a linear structure creating a dissection-like appearance was initially observed. Careful evaluation revealed a continuous intravascular structure extending from the

LMCA to the descending thoracic aorta, consistent with a retained guidewire (Figure 2A-C). In addition, stress cardiac MRI was performed to assess for myocardial ischemia, which revealed no inducible ischemia. A linear signal void within the aortic lumen was also demonstrated (Figure 2D), and the patient was subsequently managed with anticoagulation. The most striking aspect of this case is the failure to detect a retained intravascular guidewire despite multiple angiographic procedures and repeated control imaging. A plausible mechanism involves partial guidewire entrapment during complex bifurcation PCI, followed by structural disruption and separation during retrieval. Technique such as crush stenting, repeated rewiring, and kissing balloon inflations may predispose the wire to mechanical stress. However, the absence of resistance during wire retrieval makes a classical entrapment-fracture mechanism less convincing. A small radiopaque focus at the distal end may represent a residual portion of the radiopaque tip. This finding argues against complete retention of the radiopaque distal segment and instead supports partial unraveling or stripping of the distal radiopaque coil, with removal of the more visible component and persistence of a predominantly low-radiopacity segment. Given the minimal size of the remaining radiopaque portion, such a long intravascular structure could have been easily overlooked during angiographic evaluation, explaining both the CT findings and poor angiographic visibility. The angiographic invisibility of the retained segment can be further explained by the heterogeneous radiopacity of guidewires. Distal segments are typically radiopaque, whereas proximal core segments may have significantly lower radiopacity, making retained portions angiographically occult. In addition, alignment along the aortic axis within a contrast-filled lumen may further reduce visibility. Importantly, smooth guidewire retrieval does not exclude intravascular complications, and repeated angiographic assessments do not guarantee detection. This case highlights the importance of multimodal imaging in patients with persistent or unexplained symptoms following complex PCI.

Conclusion: Retained guidewires may remain undetected despite angiography, necessitating multimodal imaging in unexplained post-PCI symptoms.

Keywords: Coronary angiography, multimodality imaging, percutaneous coronary intervention, retained guidewire

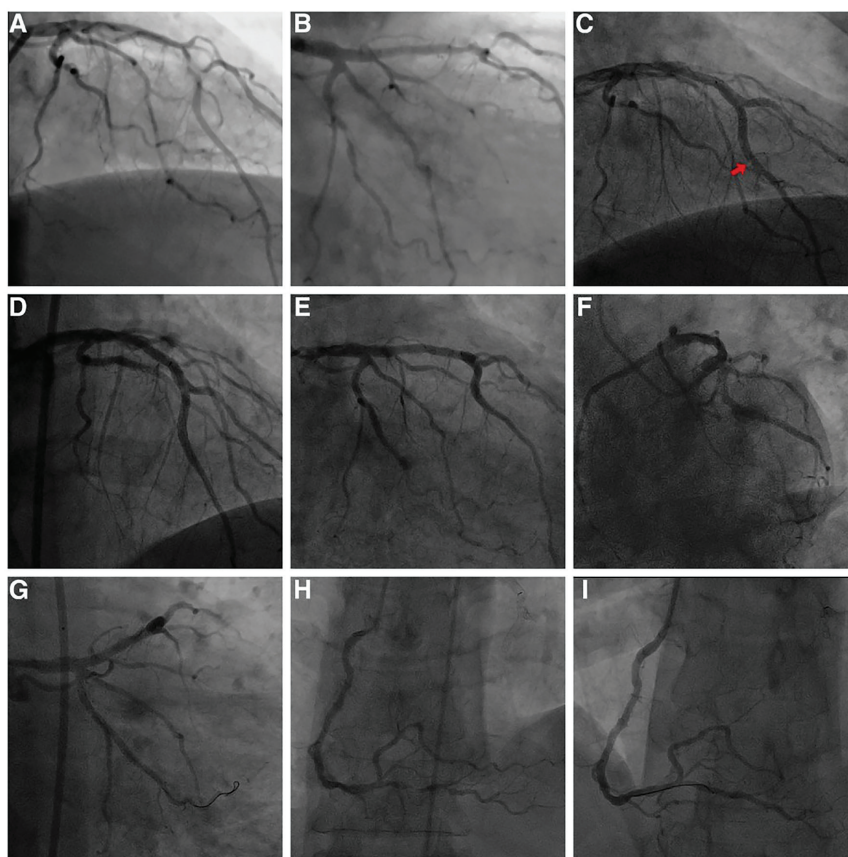


Figure 1. Serial coronary angiography and staged percutaneous coronary interventions. (A, B) Initial coronary angiography demonstrating significant stenoses in the left anterior descending (LAD) and circumflex (CX) arteries. (C) LAD stenting with kissing balloon angioplasty to the diagonal branch. (D) Post-stenting dissection leading to completion of the LAD-diagonal bifurcation using the crush technique. (E) Overlapping drug-eluting stent (DES) implantation in the CX artery. (F, G) Follow-up angiography demonstrating patent LAD and CX stents. (H, I) Right coronary artery (RCA) before and after successful DES implantation

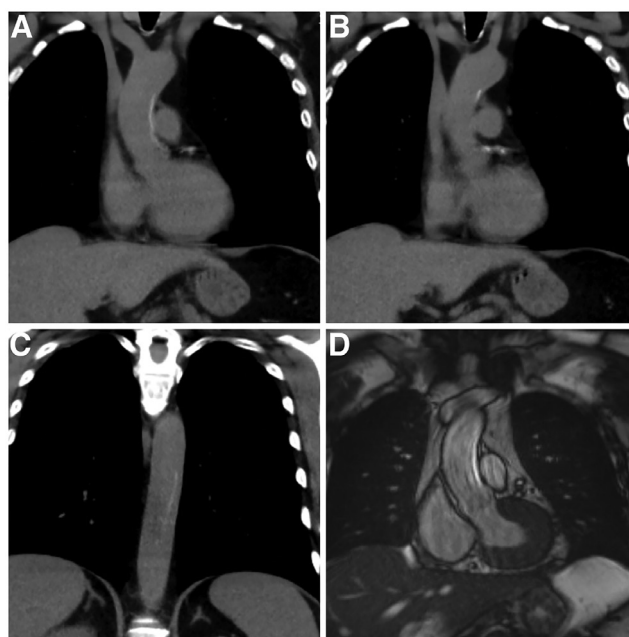


Figure 2. Multimodality imaging of angiographically occult retained guidewire. (A-C) Contrast-enhanced thoracic computed tomography demonstrating a long linear intravascular structure extending from the left main coronary artery (LMCA) through the ascending and descending thoracic aorta. (D) Cardiac magnetic resonance imaging showing a linear signal void within the aortic lumen, consistent with a retained intravascular guidewire

[OP-35]**Radial Loop: A Rare Anatomical Barrier to Transradial Coronary Intervention**

Saim Sağ, Yusuf Aktürk

Clinic of Cardiology, Acibadem Bursa Hospital, Bursa

Aim: Transradial access has become the preferred approach for coronary angiography and percutaneous coronary interventions due to its reduced bleeding complications, earlier mobilization, and shorter hospital stay. Despite these advantages, anatomical variations of the radial artery may pose technical challenges. Radial loop is a relatively rare anatomical variant, with a reported incidence of approximately 1-2%, and may prevent catheter advancement, leading to procedural difficulty or access failure. Recognition of this variation and familiarity with dedicated techniques are essential for procedural success.

Case Report: A 70-year-old male with a history of stent implantation to the circumflex obtuse marginal artery 10 years prior was admitted with a one-week history of chest pain, occasionally occurring at rest. Electrocardiography revealed non-ST-segment elevation. Based on clinical evaluation, unstable angina pectoris was diagnosed, and coronary angiography was planned. The procedure was initiated via the right radial artery. After local anesthesia, a 6F sheath was inserted, and a standard antispasmodic protocol was administered. A 0.035-inch hydrophilic guidewire was advanced toward the brachial artery; however, a 5F TIG diagnostic catheter could not be advanced. Radial arteriography demonstrated a 360° radial loop. Attempts to cross the loop with the 0.035-inch guidewire were unsuccessful. Subsequently, a 0.014-inch extra-support PTCA guidewire was used to cross the loop. Balloon-assisted tracking was then applied to facilitate catheter advancement. Using a microcatheter, the guidewire was exchanged for a 0.035-inch stiff wire, resulting in straightening of the loop and improved support. Diagnostic catheters were subsequently advanced without difficulty, and coronary angiography was completed. Angiography revealed significant stenosis in the right coronary artery. Percutaneous coronary intervention was performed during the same session, with successful balloon predilatation followed by stent implantation. At the end of the procedure, the radial sheath was removed and hemostasis was achieved using a compression device. The patient had an uneventful recovery and was discharged the following day. The transradial approach is now the default strategy for coronary angiography and intervention; however, anatomical variations of the radial artery continue to challenge even experienced operators. Radial loop, although infrequent, represents a clinically significant anatomical obstacle that may lead to procedural delay, increased radiation exposure, or access site crossover if not appropriately managed. Early recognition is critical. Resistance to catheter advancement despite successful wire progression should raise suspicion for radial loop, and radial angiography should be promptly performed. Blind or forceful manipulation must be avoided due to the risk of dissection or perforation. Management requires a structured, escalation-based approach. While 0.035-inch hydrophilic guidewires are commonly used initially, they may be insufficient in tight loops. A 0.014-inch coronary guidewire, particularly with extra support, provides superior steerability and facilitates safe traversal of the loop. Balloon-assisted tracking (BAT) represents a key technique in such cases. By advancing a partially inflated balloon at the catheter tip, BAT reduces vessel trauma and allows smooth catheter passage through complex anatomy. Additional strategies such as buddy wire technique and microcatheter support may further enhance procedural success. Following successful crossing, exchange to a

stiffer 0.035-inch guidewire can help straighten the loop and improve support for catheter delivery. Equally important is procedural judgment—operators should avoid persistent forceful attempts and maintain a low threshold for technique modification or access site conversion when necessary. This case demonstrates that, with appropriate technique selection and operator experience, even a 360° radial loop can be successfully managed, allowing completion of both diagnostic angiography and percutaneous coronary intervention via the transradial route.

Conclusion: Radial loop is a rare but important anatomical variation that can complicate transradial coronary procedures. With early recognition and the use of appropriate techniques such as coronary guidewires and BAT, successful intervention can be achieved without the need for alternative access.

Keywords: Transradial intervention, radial loop, balloon assisted tracking

[OP-38]**Patient-Centered Staged Percutaneous Coronary Revascularization in Triple-vessel Coronary Artery Disease: A Video Case of Sequential CTO, Drug-coated Balloon, and DES Strategy**

Mustafa Tunahan Öz, Adnan Kaya

Department of Cardiology, Bahçeşehir University Faculty of Medicine, İstanbul

Aim: Management of multivessel coronary artery disease remains a complex clinical challenge, particularly when different lesion morphologies require individualized revascularization strategies. Decisions between coronary artery bypass grafting (CABG), multivessel percutaneous coronary intervention (PCI), hybrid approaches, or optimal medical therapy should ideally involve heart-team discussion and patient preferences.

Case Report: A 66-year-old male with hypertension, diabetes mellitus, and hyperlipidemia presented with exertional chest discomfort. He had no smoking or alcohol history. Coronary computed tomography angiography revealed a critical lesion in the left anterior descending artery (LAD). Subsequent invasive coronary angiography demonstrated severe triple-vessel coronary artery disease with a chronic total occlusion (CTO) of the right coronary artery (RCA), a significant lesion in the circumflex artery (Cx), and a critical LAD stenosis. After discussing treatment options including CABG, hybrid revascularization, and staged PCI with the patient, a patient-centered staged percutaneous strategy was selected. The procedure was performed in three sessions. In the first stage, successful CTO PCI of the RCA was achieved. During the second session, the Cx lesion was treated using a drug-coated balloon following adequate lesion preparation. In the final stage, the LAD critical stenosis was successfully treated with drug-eluting stent implantation, achieving optimal angiographic results in all vessels.

Conclusion: This case illustrates how lesion-specific staged PCI strategies may provide an effective alternative to surgical revascularization in selected patients with multivessel coronary artery disease. Tailoring the intervention according to lesion complexity—combining CTO PCI, drug-coated balloon therapy, and drug-eluting stenting—can achieve complete revascularization while respecting patient preferences.

Keywords: Multivessel coronary artery disease, staged percutaneous coronary intervention, chronic total occlusion PCI

[OP-39]**The Prognostic Role of Admission Glucose in the Era of High-sensitivity Troponins and Contemporary Primary PCI**

Ömer Bedir

University of Health Sciences Türkiye, Adana City Hospital, Adana

Aim: Admission hyperglycemia is frequently encountered in patients presenting with ST-elevation myocardial infarction (STEMI) and has been associated with adverse in-hospital outcomes across multiple observational cohorts. Whether elevated glucose independently drives early complications or merely reflects the neuroendocrine and hemodynamic consequences of extensive myocardial necrosis remains unresolved, particularly in the context of contemporary reperfusion practice and high-sensitivity biomarker assessment. We investigated the relationship between admission glucose, markers of myocardial injury, and early clinical outcomes in a consecutive STEMI population treated with primary percutaneous coronary intervention (pPCI).

Methods: Consecutive STEMI patients undergoing pPCI between January 2025 and May 2025 were retrospectively analyzed. Patients were classified as normoglycemic (admission glucose <140 mg/dL) or hyperglycemic (\geq 140 mg/dL), consistent with the threshold commonly applied in the stress hyperglycemia literature. Myocardial injury was quantified by peak high-sensitivity troponin I (hsTnI, ng/L), peak creatine kinase-MB mass (ng/mL), and pre-discharge left ventricular ejection fraction (LVEF). The primary endpoint was a composite of in-hospital mortality, cardiogenic shock, sustained

ventricular arrhythmia, or new-onset acute heart failure. Independent predictors were identified by multivariable logistic regression adjusting for age, sex, diabetes mellitus, HbA1c, eGFR, symptom-to-balloon time, LVEF, infarct location, post-PCI TIMI flow grade, and multivessel disease.

Results: One hundred and fifty-two patients were included (mean age 63 ± 12 years; 71% male). Admission hyperglycemia was present in 63 patients (41%). Compared with normoglycemic patients, those with hyperglycemia had longer symptom-to-balloon times (188 vs. 142 min; $p=0.02$), lower rates of post-PCI TIMI 3 flow (81% vs. 93%; $p=0.02$), higher peak hsTnI [54,200 (IQR 24,100-112,000) vs. 22,450 (9,800-48,600) ng/L; $p<0.001$], higher peak CK-MB mass [268 (118-486) vs. 118 (52-224) ng/mL; $p<0.001$], and lower discharge LVEF ($42.4 \pm 10.6\%$ vs. $49.1 \pm 8.8\%$; $p=0.001$). The primary composite endpoint occurred more frequently in the hyperglycemic group (32% vs. 16%; $p=0.018$). On multivariable analysis, however, admission hyperglycemia did not retain independent prognostic significance (adjusted OR 1.6, 95% CI 0.7-3.4; $p=0.27$). LVEF per 5% decrement (adjusted OR 2.0, 95% CI 1.5-2.8; $p<0.001$) and symptom-to-balloon time per 30-minute increment (adjusted OR 1.4, 95% CI 1.0-1.8; $p=0.03$) emerged as the sole independent predictors.

Conclusion: In STEMI patients treated with contemporary pPCI, admission hyperglycemia was associated with larger infarct burden and reduced systolic function, yet failed to independently predict early adverse outcomes once infarct size and ischemia duration were accounted for. These findings suggest that in the current era of high-sensitivity troponin measurement and guideline-directed reperfusion, admission glucose may serve as a marker of ischemic injury severity rather than a discrete mediator of poor prognosis.

Keywords: Admission hyperglycemia, high-sensitivity troponin, myocardial injury, primary percutaneous coronary intervention, ST-elevation myocardial infarction

Table 1. Baseline and clinical characteristics according to admission glucose status

Variable	Normoglycemia (<140 mg/dL, n=89)	Hyperglycemia (\geq 140 mg/dL, n=63)	p value
Age, years	60.8 \pm 11.4	66.8 \pm 12.1	0.01
Male sex, n (%)	65 (73%)	43 (68%)	0.51
Diabetes mellitus, n (%)	11 (12%)	30 (48%)	<0.001
Prior myocardial infarction, n (%)	8 (9%)	10 (16%)	0.17
Symptom-to-balloon time, min	142 (108-198)	188 (138-272)	0.02
Anterior STEMI, n (%)	35 (39%)	29 (46%)	0.38
TIMI 3 flow post-PCI, n (%)	83 (93%)	51 (81%)	0.02
Admission glucose, mg/dL	108 \pm 21	212 \pm 68	<0.001
HbA1c, %	5.6 \pm 0.4	7.2 \pm 1.6	<0.001
eGFR, mL/min/1.73 m ²	82.4 \pm 18.2	74.6 \pm 22.5	0.03
Hemoglobin, g/dL	13.8 \pm 1.7	13.2 \pm 1.9	0.06
hsCRP, mg/L	4.2 (1.8-9.4)	8.6 (3.5-18.2)	0.001
Peak hsTroponin I, ng/L	22,450 (9,800-48,600)	54 200 (24,100-112,000)	<0.001
Peak CK-MB mass, ng/mL	118 (52-224)	268 (118-486)	<0.001
LVEF at discharge, %	49.1 \pm 8.8	42.4 \pm 10.6	0.001
Composite adverse outcome, n (%)	14 (16%)	20 (32%)	0.018
In-hospital mortality	3 (3%)	7 (11%)	0.063
Cardiogenic shock	4 (4%)	8 (13%)	0.074
Sustained ventricular arrhythmia	4 (4%)	5 (8%)	0.30
Acute heart failure	7 (8%)	12 (19%)	0.028

CK-MB mass: Creatine kinase-myocardial band mass assay, eGFR: Estimated glomerular filtration rate (CKD-EPI), HbA1c: Glycated haemoglobin, hsCRP: High-sensitivity C-reactive protein, hsTnI: High-sensitivity troponin I, LVEF: Left ventricular ejection fraction, PCI: Percutaneous coronary intervention, TIMI: Thrombolysis in myocardial infarction

Table 2. Multivariable logistic regression: independent predictors of in-hospital adverse outcomes

Variable	Unadjusted OR (95% CI)	p value	Adjusted OR (95% CI)	p value
Glycemic variables				
Admission hyperglycemia (≥ 140 mg/dL)	2.4 (1.1-5.1)	0.02	1.6 (0.7-3.4)	0.27
Diabetes mellitus	2.0 (0.9-4.2)	0.08	1.2 (0.5-2.8)	0.68
HbA1c (per 1% increase)	1.4 (1.1-1.9)	0.02	1.1 (0.8-1.6)	0.44
Markers of myocardial injury				
LVEF (per 5% decrease)	1.9 (1.4-2.5)	<0.001	2.0 (1.5-2.8)	<0.001
Peak hsTnI (per 10 000 ng/L increase)	1.3 (1.1-1.6)	0.008	1.1 (0.9-1.4)	0.22
Peak CK-MB mass (per 100 ng/mL increase)	1.2 (1.0-1.5)	0.04	1.1 (0.9-1.4)	0.31
Procedural and clinical factors				
Symptom-to-balloon time (per 30-min increase)	1.4 (1.1-1.9)	0.01	1.4 (1.0-1.8)	0.03
TIMI flow post-PCI <3	2.1 (0.9-4.8)	0.08	1.8 (0.8-4.2)	0.17
Anterior STEMI	1.7 (0.8-3.6)	0.18	1.5 (0.7-3.2)	0.33
eGFR (per 10 mL/min/1.73 m ² decrease)	1.3 (1.0-1.6)	0.04	1.2 (0.9-1.5)	0.19
Age (per 10-year increase)	1.5 (1.1-2.1)	0.02	1.2 (0.9-1.8)	0.21

Composite outcome: in-hospital mortality, cardiogenic shock, sustained ventricular arrhythmia, or acute heart failure. Model adjusted for age, sex, diabetes mellitus, symptom-to-balloon time, LVEF: Anterior infarct location, multivessel disease, eGFR, and HbA1c
CK-MB: Creatine kinase-myocardial band mass, eGFR: Estimated glomerular filtration rate, HbA1c: Glycated haemoglobin, hsTnI: High-sensitivity troponin I, LVEF: Left ventricular ejection fraction, TIMI: Thrombolysis in myocardial infarction

[OP-40]

Major Bleeding in Patients with Cardiogenic Shock Receiving Tirofiban Therapy in Acute Coronary Syndrome

Erdi Babayigit, Taha Maheryaseen Yaseen, Yousef Aljaber, Mohamad Ali Alhussein, Dua Hegazi

Eskişehir Osmangazi University Faculty of Medicine, Eskişehir

Aim: Tirofiban, a glycoprotein IIb/IIIa inhibitor, is frequently used as adjunctive antiplatelet therapy during percutaneous coronary intervention (PCI) in patients with acute coronary syndrome (ACS). Cardiogenic shock (CS) is a life-threatening complication of ACS characterized by hemodynamic instability, impaired renal function, reduced ejection fraction, and anemia—all established bleeding risk factors. This study aimed to evaluate whether cardiogenic shock is associated with higher rates of major bleeding and adverse clinical outcomes in ACS patients receiving tirofiban therapy.

Methods: We conducted a retrospective single-center study of 225 consecutive ACS patients who received tirofiban during PCI. Patients were stratified by the presence (n=30, 13.3%) or absence (n=195, 86.7%) of cardiogenic shock at presentation. The primary endpoint was BARC ≥3 major bleeding. Secondary endpoints included any bleeding (BARC ≥1), hemoglobin drop ≥3 g/dL, all-cause in-hospital mortality, and MACE. Continuous variables were tested for normality using the Shapiro-Wilk test. Normally distributed data are

presented as mean±SD and compared using independent-samples t-test; non-normally distributed data as median (IQR) with Mann-Whitney U test. Categorical variables were compared using Fisher's exact test. A p value <0.05 was considered statistically significant.

Results: Patients with cardiogenic shock were significantly older (69.5±9.2 vs. 59.4±12.6 years, p<0.001), had lower LVEF (37.8±11.2% vs. 44.6±11.2%, p=0.005), worse renal function (eGFR 57.9±20.2 vs. 75.9±15.2 mL/min/1.73m², p<0.001), lower systolic blood pressure (101.2±18.5 vs. 127.1±20.7 mmHg, p<0.001), and higher creatinine (1.45±0.84 vs. 1.03±0.25 mg/dL, p=0.011) compared to non-shock patients. Full-dose tirofiban was administered significantly less frequently in the shock group (50.0% vs. 77.4%, p=0.003). BARC ≥3 major bleeding was significantly more frequent in patients with cardiogenic shock (16.7% vs. 5.6%, p=0.045). All-cause in-hospital mortality (36.7% vs. 2.1%, p<0.001) and MACE (33.3% vs. 4.1%, p<0.001) were markedly higher in the cardiogenic shock group.

Conclusion: Cardiogenic shock is associated with a significantly higher rate of major in-hospital bleeding, mortality, and MACE in ACS patients receiving tirofiban therapy—even when full-dose tirofiban is less frequently administered in this group. The concurrent presence of advanced age, impaired renal function, reduced ejection fraction, and hemodynamic compromise likely contributes to this elevated hemorrhagic and ischemic risk. These findings underscore the need for individualized antithrombotic strategies and heightened clinical vigilance in cardiogenic shock patients undergoing PCI.

Keywords: Tirofiban, acute coronary syndrome, cardiogenic shock, BARC, MACE, glycoproteinIIb/IIIainhibitor

Table 1. Baseline characteristics according to cardiogenic shock

Variable	Cardiogenic shock (n=30)	No shock (n=195)	p value
Demographics and Comorbidities			
Age, years — mean±SD	69.5 ± 9.2	59.4 ± 12.6	<0.001
Male sex, n (%)	26 (86.7%)	166 (85.1%)	1.000†
Hypertension, n (%)	15 (50.0%)	100 (51.5%)	1.000†
Diabetes mellitus, n (%)	14 (46.7%)	66 (33.8%)	0.219†
Current or ex-smoking, n (%)	20 (71.4%)	112 (62.2%)	0.002†
eGFR <60 mL/min/1.73m ² , n (%)	15 (50.0%)	32 (16.4%)	<0.001†
Anticoagulant use at admission, n (%)	3 (10.7%)	4 (2.2%)	0.049†
Cardiac History			
Previous CAD, n (%)	14 (46.7%)	85 (43.8%)	0.844†
Previous ACS, n (%)	11 (36.7%)	66 (33.8%)	0.837†
Previous CABG, n (%)	4 (13.3%)	24 (12.3%)	0.774†
Diagnosis and Presentation			
STEMI, n (%)	24 (80.0%)	142 (72.8%)	0.507†
NSTEMI, n (%)	5 (16.7%)	41 (21.1%)	0.808†
Laboratory Values at Admission			
Admission Hb, g/dL — mean±SD	13.9 ± 2.4	14.7 ± 2.1	0.058
eGFR, mL/min/1.73m ² — mean±SD	57.9 ± 20.2	75.9 ± 15.2	<0.001
LVEF, % — mean±SD	37.8 ± 11.2	44.6 ± 11.2	0.005
Systolic BP, mmHg — mean±SD	101.2 ± 18.5	127.1 ± 20.7	<0.001
Creatinine, mg/dL — mean±SD	1.45 ± 0.84	1.03 ± 0.25	0.011‡
NT-proBNP, pg/mL — mean±SD	13159 ± 13887	2958 ± 6551	0.011‡
Albumin, g/dL — mean±SD	3.81 ± 0.43	3.95 ± 0.37	0.096
Tirofiban Administration			
Full-dose tirofiban, n (%)	15 (50.0%)	151 (77.4%)	0.003†
Median infusion duration, hours	24	24	NS

Data presented as mean±SD or n (%). Independent-samples t-test for continuous variables; † Fisher's Exact Test for categorical variables. ‡ Equal variances not assumed (Levene's test p<0.05). NS: not significant. Green rows: statistically significant (p<0.05). Smoking: n=208 (17 missing). Admission OAC: n=214 (11 missing). NT-proBNP: n=85 (140 missing). Albumin: n=187 (38 missing).

Table 2. Bleeding and clinical outcomes according to cardiogenic shock status

Outcome	Cardiogenic shock (n=30)	No shock (n=195)	p value
BARC ≥3 major bleeding, n (%)	5 (16.7%)	11 (5.6%)	0.045†
Any bleeding (BARC ≥1), n (%)	10 (33.3%)	41 (21.0%)	0.160†
Hemoglobin drop ≥3 g/dL, n (%)	6 (20.0%)	24 (12.3%)	0.253†
Hematoma, n (%)	2 (6.9%)	20 (10.3%)	0.747†
All-cause mortality, n (%)	11 (36.7%)	4 (2.1%)	<0.001†
MACE, n (%)	10 (33.3%)	8 (4.1%)	<0.001†

† Fisher's Exact Test. Green rows: statistically significant (p<0.05). BARC: Bleeding Academic Research Consortium; MACE: Major Adverse Cardiovascular Events (composite of CV death + non-fatal MI + non-fatal stroke + urgent revascularization). Hematoma: n=223 (2 missing).

[OP-41]**Prognostic Value of the CALLY Score for Predicting Contrast-induced Nephropathy in Patients with ST-elevation Myocardial Infarction Undergoing Primary Percutaneous Coronary Intervention**

Alperen Taş, Alp Yıldırım, Müzeyyen Gizem Parmak

Department of Cardiology, Kırşehir Ahi Evran University Training and Research Hospital, Kırşehir

Aim: Contrast-induced nephropathy (CIN) remains an important complication after primary percutaneous coronary intervention (PCI) in patients with ST-elevation myocardial infarction (STEMI) and is associated with increased morbidity and mortality. Early identification of patients at risk for CIN is crucial for preventive strategies. The CALLY score, calculated using C-reactive protein, albumin, and lymphocyte count, reflects systemic inflammation, nutritional status, and immune response. This study aimed to evaluate the predictive value of the CALLY score for the development of CIN in patients with STEMI undergoing primary percutaneous coronary intervention.

Methods: This retrospective study included patients with STEMI who underwent primary PCI. Clinical characteristics, laboratory parameters, and procedural data were collected. Patients were divided into two groups according to the development of CIN. Continuous variables were expressed as mean \pm standard deviation or median (minimum-maximum) according to distribution, and categorical variables were presented as frequencies and percentages. Group comparisons were performed using Student's t-test or the Mann-Whitney U test for continuous variables and the chi-square or Fisher's exact test for categorical variables. Univariable logistic regression analyses were performed to identify predictors of CIN, and variables with $p < 0.1$ were included in the multivariable regression model. Multicollinearity was assessed using variance inflation factor (VIF). Receiver operating characteristic (ROC) curve analysis was performed to evaluate the discriminatory ability of biomarkers, and optimal cut-off values were determined using Youden's index. The DeLong test was used to compare AUC values between CALLY and creatinine.

Results: A total of 679 patients were included in the study, and CIN developed in 105 patients (15.4%). Patients who developed CIN were older and had higher rates of diabetes mellitus and chronic renal failure. They also had

lower left ventricular ejection fraction and higher inflammatory markers. The CALLY score was significantly lower in patients who developed CIN compared with those without CIN. In multivariable logistic regression analysis, serum creatinine and CALLY score were identified as independent predictors of CIN. ROC curve analysis demonstrated that the CALLY score had good predictive ability for CIN (AUC: 0.755; 95% CI: 0.704-0.806) and showed significantly higher discriminatory performance than serum creatinine (AUC: 0.667; 95% CI: 0.608-0.727; DeLong test $p=0.043$). The optimal cut-off value for the CALLY score was 0.49, with 68% sensitivity and 67% specificity.

Conclusion: The CALLY score is a simple and readily available biomarker that independently predicts the development of contrast-induced nephropathy in patients with STEMI undergoing primary PCI. Moreover, it demonstrated better discriminatory performance than serum creatinine. The CALLY score may be a useful tool for early risk stratification and identification of high-risk patients in clinical practice.

Keywords: CALLY score, contrast-induced nephropathy, primary percutaneous coronary intervention, ST-elevation myocardial infarction

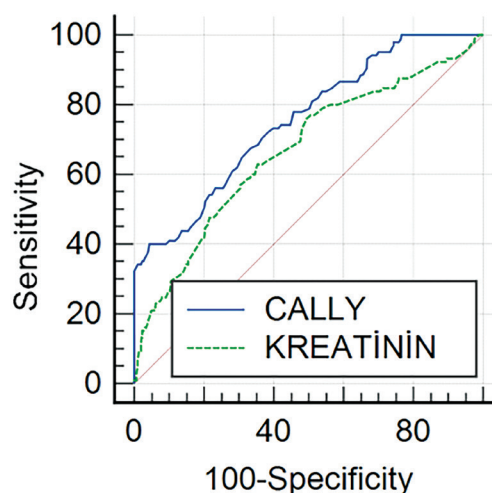


Figure 1. ROC curve

Table 1. Comparison patients without CIN and with CIN

Variables	Patients without CIN, n=574	Patients with CIN, n=105	p
Age	58.93±12.0	61.90±12.63	0.021
Gender (male), n (%)	458 (79.8)	87 (82.9)	0.468
DM, n (%)	134 (23.3)	37 (35.2)	0.010
HT, n (%)	185 (32.2)	42 (40)	0.121
Smoking, n (%)	285 (49.7)	50 (47.6)	0.702
COPD, n (%)	5 (0.9)	2 (1.9)	0.335
CRF, n (%)	7 (1.2)	7 (6.7)	<0.001
CHF, n (%)	28 (4.9)	6 (5.7)	0.718
Contrast amount, mL	242.73±89.06	256.19±94.74	0.159
LV EF, %	46.42±9.48	42.20±12.15	0.002
WBC, 10 ³ /mm ³	11.70 (4.10-46.90)	12.40 (3.33-27.60)	0.023
HGB, g/dL	13.57±1.76	13.23±2.21	0.149
Neutrophils, 10 ³ /mm ³	9.30 (1.10-40.90)	9.81 (1.60-24.50)	0.068
Lymphocytes, 10 ³ /mm ³	1.30 (0.30-9.88)	1.60 (0.20-3.30)	0.025
CRP, mg/L	8 (1-86)	15 (1-311)	<0.001
Aspartat aminotransferaz, U/L	65 (10-3429)	118 (14-1174)	0.003
Alanin aminotransferaz, U/L	29 (8-3512)	40 (12-437)	0.001
Sodium, mmol/L	136.40±3.92	135.75±3.51	0.213
Albumin, g/dL	3.39±0.51	3.42±0.54	0.566
Glucose, mg/dL	139 (53-691)	160 (93-485)	<0.001
Creatinine, mg/dL	0.92±0.31	1.12±0.42	<0.001
Triglycerides, mg/dL	129 (11-848)	143 (44-1312)	0.087
HDL, mg/dL	37 (12-105)	36 (21-67)	0.974
LDL, mg/dL	110 (11-267)	115 (29-264)	0.346
Troponin	6.02 (0.010-440)	15.74 (0.010-50)	<0.001
CALLY	0.60 (0.10-8.37)	0.36 (0.01-1.09)	<0.001
In hospital mortality, n (%)	25 (4.4)	12 (11.4)	0.003
Syptom-to-balloon time, min	60 (30-300)	90 (30-360)	0.002
Follow-up period, days	3.82±2.37	4.16±2.76	0.195

Table 2. Regression for CIN

Variables	Univariable regression	Univariable regression	Multivariable regression	Multivariable regression
	OR (95% CI)	p	OR (95% CI)	p
Age	1.021 (1.003-1.039)	0.021	1.020 (0.997-1.044)	0.086
LVEF	0.960 (0.939-0.981)	<0.001	0.986 (0.961-1.011)	0.276
Creatinine	4.437 (2.497-7.886)	<0.001	3.510 (1.793-6.869)	<0.001
DM	1.787 (1.145-2.787)	0.011	1.485 (0.849-2.595)	0.165
WBC	1.068 (1.022-1.116)	0.004	1.048 (0.989-1.111)	0.111
Aspartat aminotransferaz	1.001 (1.000-1.002)	0.175		
Troponin	1.006 (0.999-1.004)	0.093	1.002 (0.994-1.010)	0.658
CALLY	0.035 (0.013-0.092)	<0.001	0.029 (0.010-0.083)	<0.001
Syptom-to-balloon time	1.004 (1.001-1.006)	0.005	1.002 (0.999-1.006)	0.181

[OP-42]

The Illusion of “Missing Proximal Cap” in Anterior STEMI and a Rare Case Identified by IVUS: “Double-barrel” Coronary Anatomy Characterized by Reverse Tapering and Ostial Hypoplasia

Medeni Karaduman

Department of Cardiology, University of Health Sciences Türkiye, Van Training and Research Hospital, Van

Aim: The separate origin of the left anterior descending artery (LAD) and the left circumflex artery (LCx) from the aorta with distinct ostia is a rare anatomical variation, observed in approximately 0.41% to 0.67% of angiographic series. Particularly in time-sensitive conditions such as ST-segment elevation myocardial infarction (STEMI), this anomaly may present diagnostic and technical challenges by leading to the illusion of a “missing proximal cap.” This case presents how the underlying “double-barrel” anatomy and the associated proximal cap ambiguity—mimicking an “LAD total occlusion” during primary PCI—were resolved through intravascular ultrasound (IVUS) guidance.

Case Report: A 34-year-old male patient presented to the emergency department with anterior STEMI, and primary PCI was indicated. Coronary angiography revealed a totally occluded LAD. During the procedure, the exact origin of the LAD could not be clearly identified. A vessel-like structure was observed in the presumed proximal LAD region, and due to its faint contrast opacification, the focus shifted to this area (Figure 1A-F). The selective engagement of the catheter into only the LCx ostium, without any opacification of the other branch, led to a typical illusion of “LAD total ostial occlusion.” Due to this misleading appearance and opacification pattern, a separate ostium for the LAD was not initially suspected. All subsequent wiring attempts failed as the wire was consistently directed into incorrect vessel segments. Following these repeated failures, IVUS was performed to clarify the lesion anatomy. IVUS examination revealed no proximal stump (cap) or

entry point in the target region (Figure 1G-I). The absence of a cap on IVUS clearly demonstrated that the vessel being interrogated was not the true LAD segment. This finding served as the most critical clue that altered the diagnostic process and raised suspicion of a separate ostium. Immediately thereafter, the catheter was withdrawn into the aorta, and a non-selective aortic root opacification (left sinus root shot) was performed. This maneuver clearly demonstrated that the LAD and Cx ostia were situated side-by-side in the left coronary sinus, resembling a “double-barrel” configuration (Figure 2A). Once the separate LAD ostium was identified, selective engagement and wiring required significant time and multiple attempts due to anatomical challenges. After extensive efforts, the lesion was crossed, and the stage for stent implantation was reached (Figure 2B). Pre-PCI IVUS was utilized again for vessel sizing (Figure 2C-E). In normal anatomy, the LAD diameter is expected to taper gradually from proximal to distal. However, in this case, while the ostial diameter of the separate LAD was approximately 2.8 mm, the diameter of the mid-segment where the lesion was located was found to be 6 mm. Contrary to the “expected” distribution in the literature, a prominent reverse taper (“mismatch”) resembling ostial hypoplasia was detected. A 4.0x18 mm DES was implanted, taking this anatomical mismatch into account (Figure 2F and G). The procedure was successfully completed, and the patient was discharged with a finalized treatment plan.

Conclusion: This case demonstrates that when the LAD cannot be visualized or its ostium cannot be identified during anterior STEMI, coronary artery variations originating from separate ostia should be considered in addition to ostial occlusion. In particular, the absence of a proximal cap during IVUS examination is a critical finding that should alert the operator to potential anatomical variations. In such scenarios, rapid diagnostic maneuvers, such as non-selective aortic root opacification, can facilitate the identification of the correct ostium and help reduce the primary PCI duration. This case highlights that the rare “double-barrel” coronary ostium variant can cause significant technical challenges during primary PCI and that intravascular imaging modalities can provide substantial contributions to defining both the diagnosis and the treatment strategy.

Keywords: Acute coronary syndrome, ambiguous cap, double-barrel coronary ostium, coronary artery anomaly, IVUS

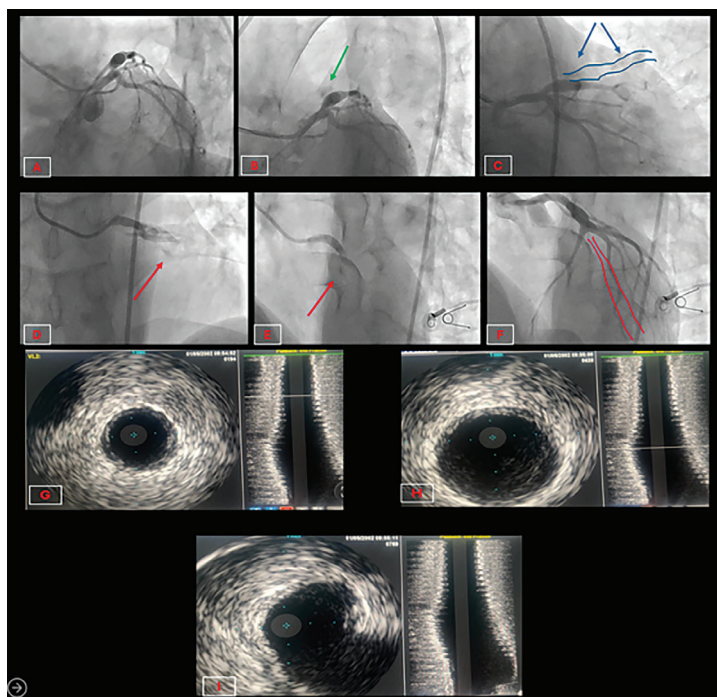


Figure 1. Angiography and IVUS; A) Left caudal view, B) contrast opacification in the area marked with a green arrow, C) the course of the totally occluded vessel is more prominent with contrast opacification indicated by a blue arrow, D and E) contrast opacification in the region marked with red arrows in cranial views, F) estimated arterial course based on contrast opacification is delineated in red, G) distal segment, H) mid-aneurysmal region, I) proximal segment; IVUS imaging performed to locate the cap of the totally occluded artery; no cap was identified during the pull-back from the distal segment toward the LMCA in the vessel initially considered to be the IMA or a diagonal branch

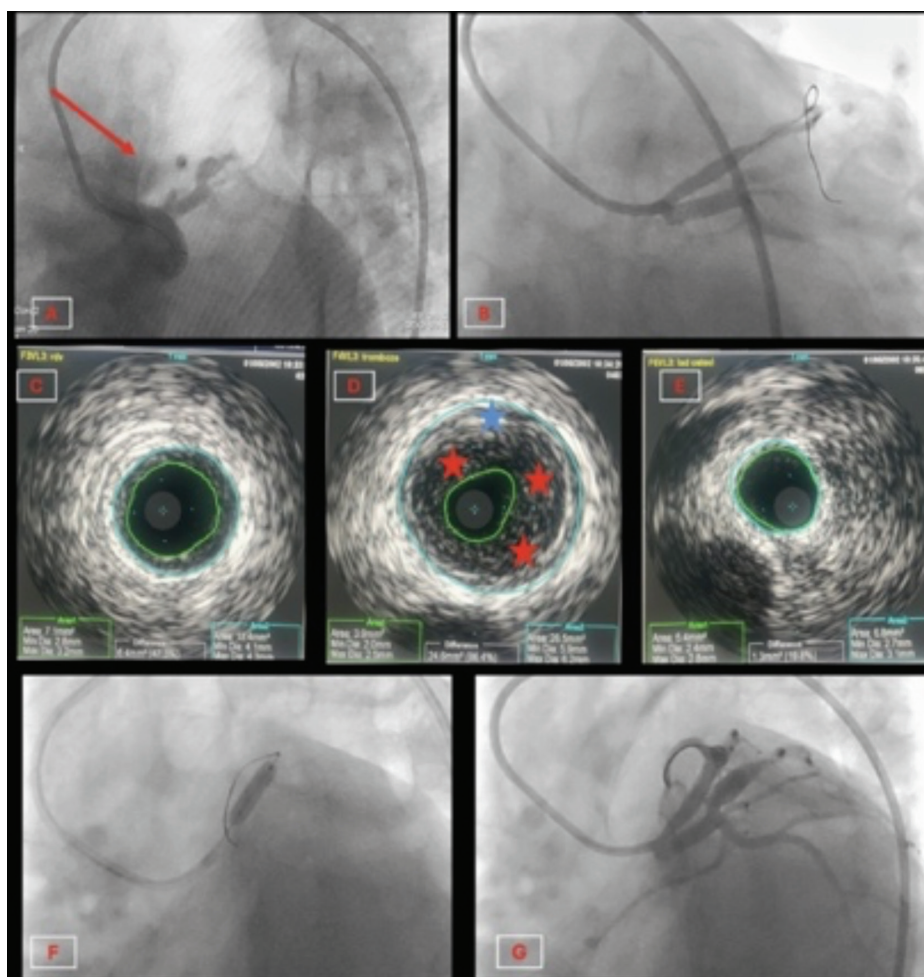


Figure 2. Angiography performed after IVUS; A) Image obtained by withdrawing the catheter shows the LAD originating from a separate ostium, with the proximal segment appearing thrombotic and subtotal, B) Difficult wiring due to the catheter's inability to seat at the LAD ostium, pre-PCI IVUS; C) Post-lesion reference distal diameter (4 mm), D) Diameter of the thrombotic segment (6 mm); the thrombotic area following plaque rupture is indicated by a red star, while the fibrotic plaque is indicated by a blue star, E) Reference diameter of the LAD ostial region (2.7 mm), PCI procedure; F) A 4.0x18 mm DES was implanted into the thrombotic LAD, G) Achievement of TIMI 3 flow following stent implantation

[OP-43]

Radial versus Femoral Access in Patients Aged 80 Years or Older Undergoing Percutaneous Coronary Intervention for Acute Myocardial Infarction

Cemalettin Yılmaz¹, İsmail Ungan¹, Muhammet Mücahit Tiryaki², Ramazan Asoğlu¹

¹Department of Cardiology, Yalova University Faculty of Medicine, Yalova

²Department of Cardiology, Muş State Hospital, Muş

Aim: The optimal vascular access site for percutaneous coronary intervention (PCI) in very elderly patients presenting with acute myocardial infarction (AMI) remains an important clinical issue. Although transradial access has been associated with fewer complications in the general population, evidence in patients aged 80 years or older is limited. This study aimed to compare clinical outcomes between transradial and transfemoral access in elderly patients with AMI undergoing PCI.

Methods: In this retrospective study, consecutive patients aged ≥80 years who underwent PCI for AMI between 2019 and 2024 were analyzed. Patients were divided into two groups according to vascular access site: transradial and transfemoral. The primary outcome was in-hospital cardiac mortality. Multivariable logistic regression analysis was performed to identify independent predictors of in-hospital cardiac mortality.

Results: A total of 118 patients were included in the study, of whom 66 (56%) underwent transradial access and 52 (44%) underwent transfemoral access. Patients in the femoral group were older (84 vs. 83 years, p=0.028). In-hospital cardiac mortality was significantly higher in the transfemoral group compared with the transradial group (27% vs. 5%, p<0.001). In multivariable logistic regression analysis adjusting for age and STEMI presentation, transfemoral access remained independently associated with increased in-hospital cardiac mortality (OR 6.04, 95% CI 1.74-28.15, p=0.005).

Conclusion: In patients aged 80 years or older presenting with AMI, transradial access was associated with lower in-hospital cardiac mortality compared with transfemoral access. These findings suggest that the transradial approach may be a safer vascular access strategy in elderly patients undergoing PCI for AMI.

Keywords: Acute myocardial infarction, elderly patients, radial access

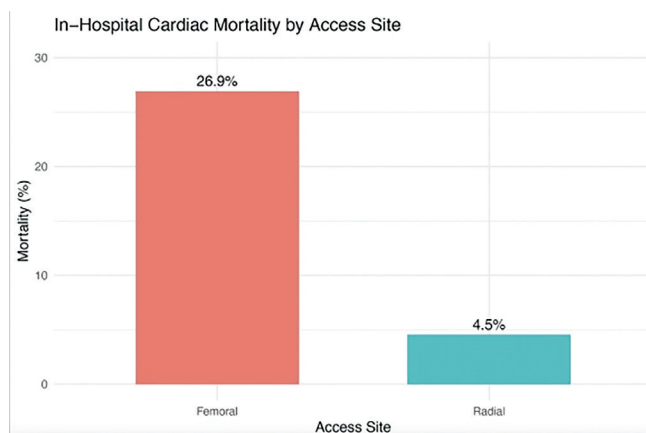


Figure 1. Comparison of in-hospital cardiac mortality between radial and femoral access

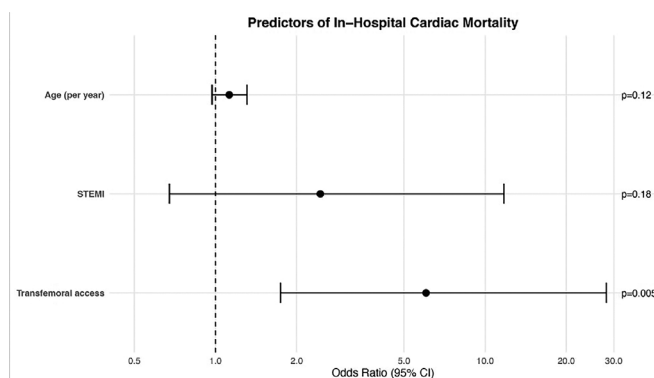


Figure 2. Forest plot of multivariable logistic regression analysis

Table 1. Multivariable logistic regression analysis for predictors of in-hospital cardiac mortality

Variables	OR	95% CI	p-value
Age (years)	1.12	0.97-1.31	0.12
STEMI vs. non-STEMI	2.45	0.67-11.76	0.18
Transfemoral access	6.04	1.74-28.15	0.005

[OP-44]**Complete Resolution of Left Main Coronary Artery Thrombus with Preserved TIMI 3 Flow Following Intensive Antithrombotic Therapy**

İzzatilla Abdulazizov, Şaban Keleşoğlu

Department of Cardiology, Erciyes University Faculty of Medicine, Kayseri

Aim: Acute coronary syndromes secondary to left main coronary artery (LMCA) thrombosis are rare but potentially catastrophic clinical conditions. However, in selected patients, distal coronary flow may be preserved despite a significant thrombus burden, which may allow consideration of alternative treatment strategies. In this case, we aimed to present the successful outcome of an intensive antithrombotic treatment strategy in a patient with a substantial LMCA thrombus burden and preserved distal coronary flow.

Case Report: A 51-year-old male patient presented to the emergency department with chest pain. His medical history was notable for recurrent pulmonary thromboembolism, while genetic testing for hypercoagulability had yielded negative results. Electrocardiography revealed no abnormalities other than sinus tachycardia. Due to a progressive rise in high-sensitivity

troponin levels, non-cardiac causes of troponin elevation were investigated. After exclusion of non-cardiac etiologies, the patient was diagnosed with non-ST-segment elevation myocardial infarction (NSTEMI), and coronary angiography was performed via the femoral artery. Coronary angiography demonstrated a thrombus extending from the LMCA to the ostial left anterior descending artery (LAD) without impairment of distal coronary flow (Figure 1). Distal flow was assessed as TIMI 3. Given the preserved coronary flow and the patient's hemodynamic stability, a conservative medical treatment strategy was preferred over invasive intervention. In addition to dual antiplatelet therapy, intravenous heparin and tirofiban infusions were initiated, and the patient was monitored in the coronary intensive care unit. Tirofiban infusion was continued for 24 hours, while heparin infusion was maintained for 72 hours. Repeat coronary angiography performed three days later demonstrated complete resolution of the LMCA thrombus, with the vessel entirely free of thrombotic material (Figure 2).

Conclusion: Left main coronary artery thrombosis is generally considered a high-risk clinical condition requiring aggressive intervention. Nevertheless, in selected patients with preserved distal coronary flow, intensive antithrombotic therapy may achieve favorable outcomes. This case highlights that medical therapy can be an effective alternative in patients with appropriate clinical and angiographic characteristics.

Keywords: Left main coronary artery thrombosis, antithrombotic therapy, myocardial infarction

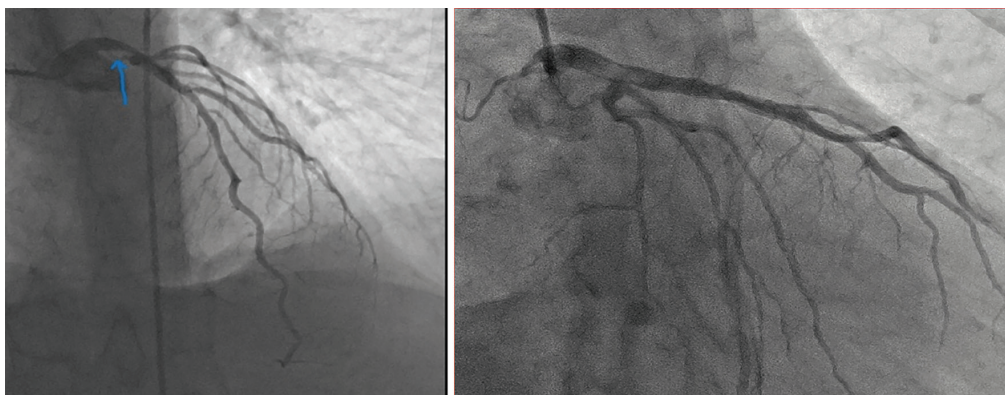


Figure 1. Coronary angiography showed LMCA thrombus in the LAO caudal and AP cranial views

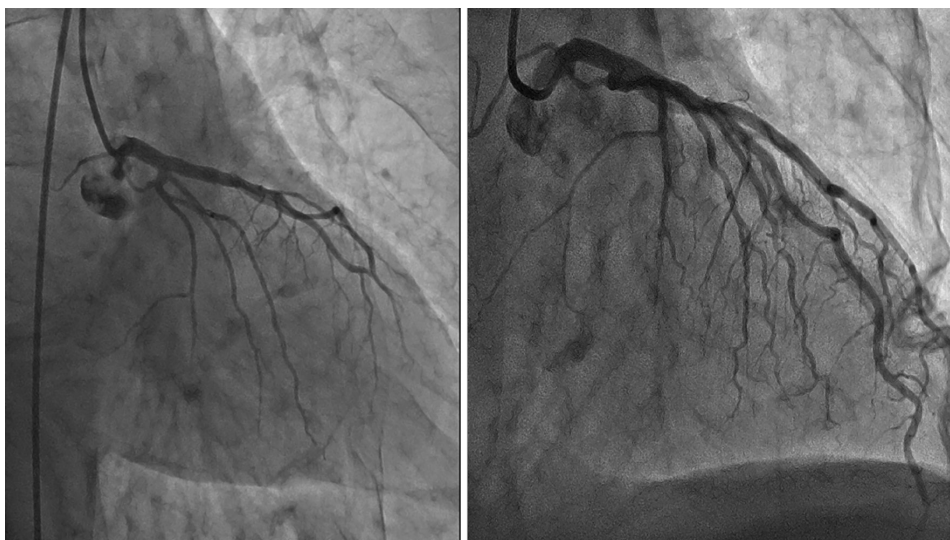


Figure 2. Repeat angiography demonstrated complete thrombus resolution

[OP-45]**Acute Total Occlusion of the Left Main Coronary Artery Presenting with Cardiogenic Shock in a Young Patient: A Successful Emergency PCI Case**

İzzatilla Abdulazizov, Şaban Keleşoğlu

Department of Cardiology, Erciyes University Faculty of Medicine, Kayseri

Aim: Acute total occlusion of the left main coronary artery (LMCA) is a rare but critical clinical condition associated with extremely high mortality due to the large myocardial territory at risk. In patients presenting with cardiogenic shock, early diagnosis and rapid revascularization are lifesaving. In this report, we aimed to present a case of successful emergency percutaneous coronary intervention (PCI) in a young patient with acute LMCA total occlusion presenting with cardiogenic shock.

Case Report: A 53-year-old male patient presented to the emergency department with chest pain. His medical history was notable for a myocardial infarction five years earlier and a previously implanted stent in the proximal segment of the left anterior descending artery (LAD). Electrocardiography demonstrated widespread ST-segment elevation in the anterior leads accompanied by reciprocal ST-segment depression in the inferior leads (Figure 1). Based on the preliminary diagnosis of acute anterior ST-segment elevation myocardial infarction (STEMI), the patient was immediately transferred to the catheterization laboratory for emergency coronary angiography. On admission, arterial blood pressure was measured at 80/50 mmHg, and the patient was in cardiogenic shock. Coronary angiography was performed via the femoral artery. After engagement of the left coronary system with a 7F JL4 guiding catheter, coronary angiography revealed total occlusion of the shaft segment of the LMCA with TIMI 0 distal flow (Figure 2). The lesion was crossed toward the LAD using a 0.014-inch floppy guidewire. Predilatation was subsequently performed with a 2.5×20 mm balloon, resulting in restoration of distal coronary flow. Thereafter, a provisional stenting strategy was employed, and a 3.5×28 mm drug-eluting stent was implanted extending toward the LAD. To achieve optimal stent expansion, proximal optimization technique (POT) was performed using 4.5×12 mm non-compliant balloons.

Due to the patient's cardiogenic shock status, additional wiring of the circumflex artery (Cx) was not attempted. During the procedure, the patient developed ventricular fibrillation twice and was successfully defibrillated back to sinus rhythm. Final angiography demonstrated TIMI 3 flow in the target vessel (Figure 3). Noradrenaline (Steradine) infusion was initiated for inotropic support.

Conclusion: Acute total LMCA occlusion is a rare and life-threatening clinical entity associated with high mortality because of the extensive myocardial territory involved. In patients presenting with cardiogenic shock, rapid diagnosis and emergency percutaneous revascularization are crucial for survival. In the present case, early intervention resulted in successful revascularization and subsequent clinical stabilization. Despite the high mortality risk associated with LMCA occlusion presenting with cardiogenic shock, early and aggressive percutaneous revascularization may significantly improve clinical outcomes.

Keywords: Left main coronary artery occlusion, acute myocardial infarction, cardiogenic shock, percutaneous coronary intervention, emergency revascularization

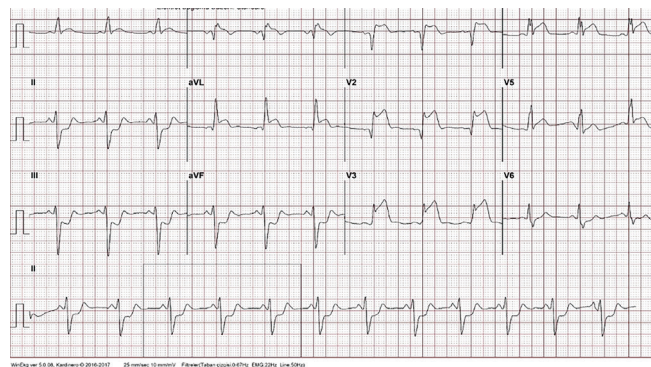


Figure 1. Admission electrocardiogram showing extensive anterior ST-segment elevation with reciprocal inferior ST-segment depression

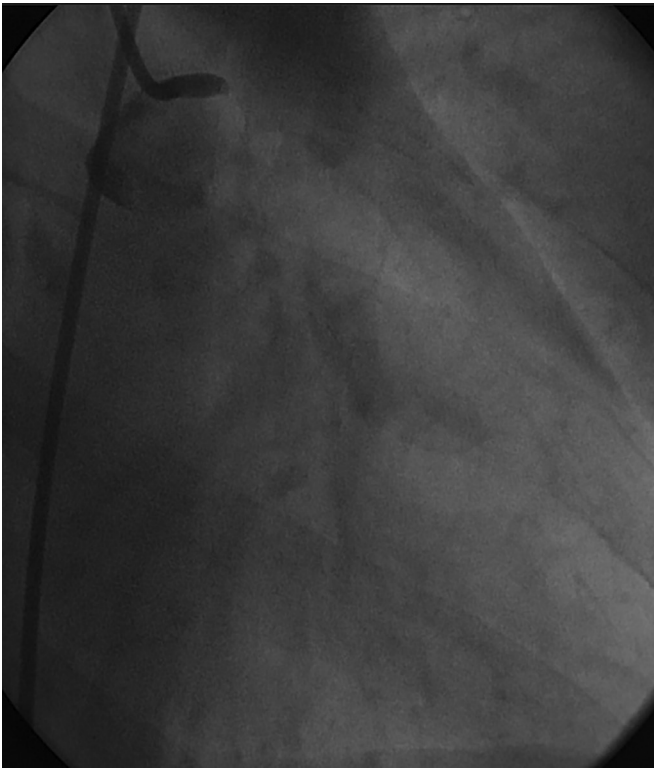


Figure 2. Coronary angiography demonstrating total occlusion of the left main coronary artery

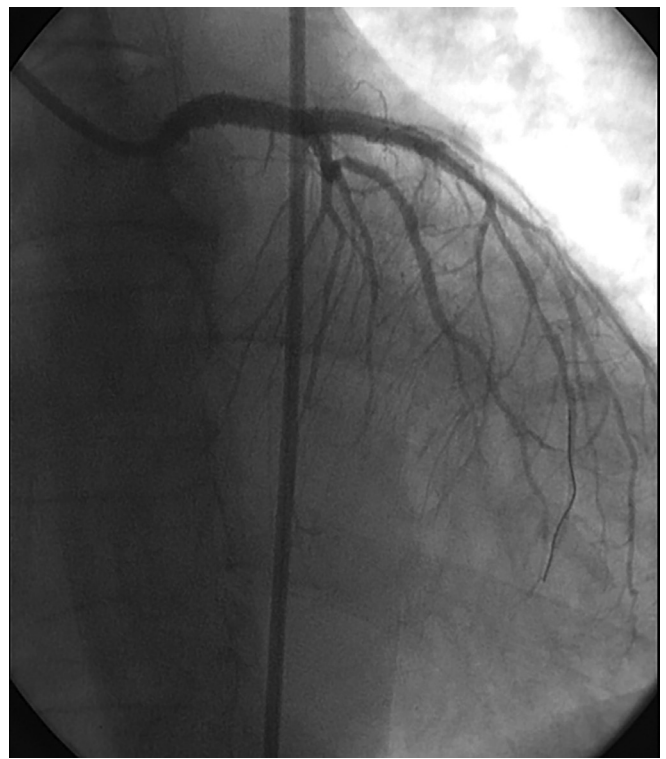

Figure 3. Final coronary angiography showing complete recanalization of the LMCA following successful PCI

[OP-47]

Association of Frontal QRS-T angle and Naples Prognostic Score with Coronary Collateral Circulation

Mehmet Zafer Aydın, Mustafa Gök, Mehmet Kamil Teber, Zülfiye Kuzu

University of Health Sciences Türkiye, Kayseri City Hospital, Kayseri

Aim: Coronary collateral circulation (CCC) plays an important role in reducing the extent of myocardial ischemic injury. While both electrical abnormalities and systemic inflammation have been linked to adverse cardiovascular outcomes, their relative contributions to collateral development are not fully understood. This study aimed to investigate the relationships among the frontal QRS-T angle, the Naples prognostic score (NPS), and CCC.

Methods: This retrospective study included 169 patients who underwent coronary angiography. CCC was evaluated using the Rentrop classification and categorized as poor (0-1) or good (2-3). Frontal QRS-T angle and NPS were assessed. Multivariable logistic regression and receiver operating characteristic (ROC) analyses were performed.

Results: Patients with poor CCC had higher frontal QRS-T angle values compared with those with good CCC. In multivariable analysis, frontal QRS-T angle remained independently associated with poor CCC (OR: 1.01 per degree increase, 95% CI: 1.00-1.02, p=0.011). In contrast, NPS was not associated with collateral status (p=0.770). ROC analysis showed modest discriminative ability for frontal QRS-T angle (AUC: 0.626), whereas NPS demonstrated limited performance (AUC: 0.558).

Conclusion: Frontal QRS-T angle was independently associated with impaired CCC, whereas the NPS showed no significant relationship. These findings suggest that electrical markers may be more relevant than immunonutritional indices in reflecting mechanisms related to collateral vessel development.

Keywords: Coronary collateral circulation, frontal QRS-T angle, Naples prognostic score

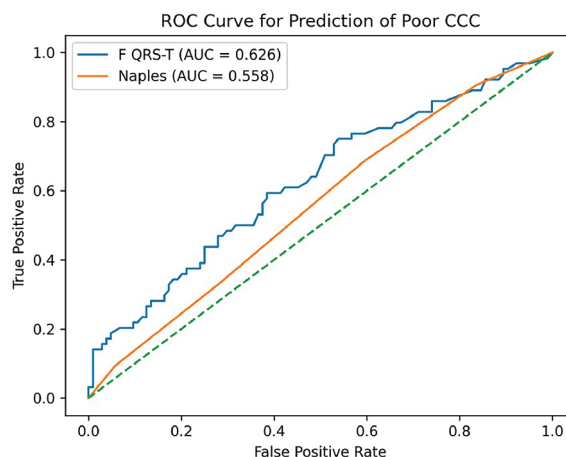


Figure 1. ROC curves of frontal QRS-T angle and Naples score for predicting poor coronary collateral circulation (AUC: 0.626 vs. 0.558)

Table 1. Baseline characteristics of the study population according to coronary collateral circulation status

Variable	Good coronary collateral circulation	Poor coronary collateral circulation	p value
Age	64.0 (58.0-71.0)	67.5 (58.8-74.2)	0.018
Glucose	120.0 (100.8-176.8)	146.0 (113.8-222.5)	0.010
Creatinine	0.9 (0.8-1.1)	1.0 (0.9-1.2)	0.028
GFR	86.5 (69.0-95.2)	77.0 (57.0-91.5)	0.027
F QRS-T	45.5 (18.0-82.5)	64.5 (34.8-115.2)	0.006
Naples	2.0 (1.0-3.0)	2.0 (1.0-3.0)	0.97
Male sex	75.0%	70.3%	0.52
Hypertension	7.7%	7.8%	0.99
Diabetes mellitus	66.3%	43.8%	0.008

Table 2. Multivariable logistic regression analysis for poor coronary collateral circulation

Variable	Adjusted OR	95% CI	p value
Age (per year)	1.01	0.97-1.04	0.754
Male sex	1.10	0.50-2.46	0.807
Diabetes mellitus	1.79	0.83-3.86	0.137
Hypertension	0.65	0.19-2.29	0.504
Glucose (per mg/dL)	1.00	1.00-1.01	0.412
Creatinine (per mg/dL)	2.15	0.85-5.42	0.106
Frontal QRS-T angle (per degree)	1.01	1.00-1.02	0.011
Naples score	1.05	0.76-1.44	0.770

[OP-48]**Coronary Aneurysm Causing Acute Anterior Myocardial Infarction in a Young Patient**

Ahmet Yanik

Medicana International Samsun Hospital, Samsun

A 29-year-old male patient applied to the emergency department with the complaint of typical chest pain and shortness of breath that started for about 2 hours. In the electrocardiogram of the patient, there was approximately ST elevation in leads V1-6. The patient was taken to primary coronary angiography (CAG) with the diagnosis of acute anterior myocardial infarction.

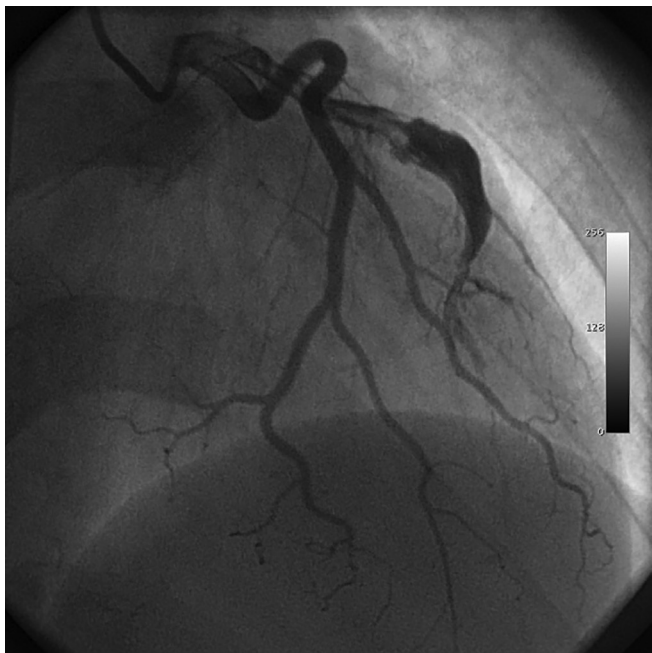


Figure 1. Coronary aneurysm in the mid-LAD artery

In CAG, left anterior descending artery (LAD) was totally occluded in the mid region. LAD lesion was crossed with floppy wire. TIMI II flow was achieved after PTCA with a 2.0x15 mm and 2.5x15 mm balloon. After distal flow was assured, an approximately 20x28 mm giant coronary artery aneurysm was observed in LAD mid region. The patient was recommended coronary artery bypass graft operation. However, percutaneous coronary intervention (PCI) decision was taken because the patient did not accept the operation. Then, 3.0x23 mm and 3.0x27 mm graft-covered stents (Fluency, Bart, USA) were implanted into aneurysmal section. It was observed that the aneurysm was completely closed. The patient was discharged without any complication. In this article, we present a patient with CAA that caused acute anterior myocardial infarction at a young age and successfully performed PCI.

Keywords: Coronary aneurysm, acute anterior myocardial infarction, graft stents

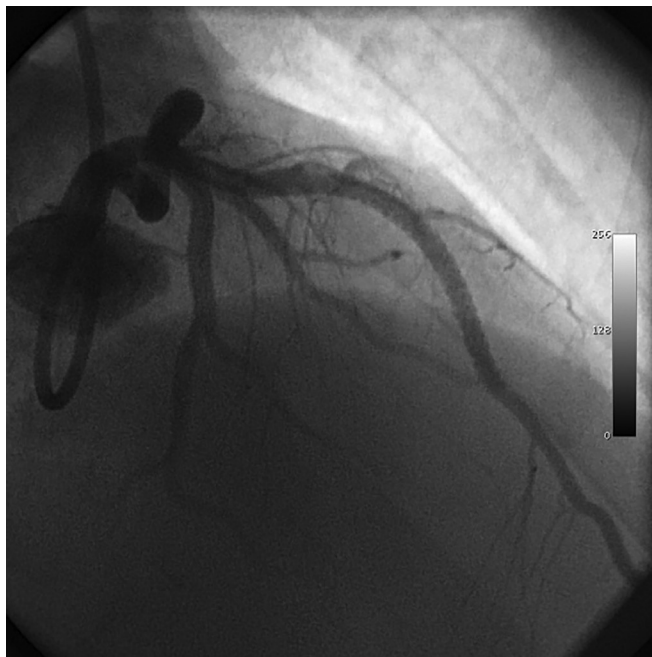


Figure 2. Coronary angiogram after successful graft stent implantation

[OP-49]**Iatrogenic Coronary Dissection Extending to the Aorta and Acute Stent Thrombosis**

Muhammed Ensar Eker, Elif Nur Torlak, Çağlar Alp, Selçuk Öztürk

Kırıkkale University Faculty of Medicine Hospital, Kırıkkale

Iatrogenic coronary artery dissections occurring during elective percutaneous coronary interventions are rare; however, when they arise particularly during interventions involving aorto-ostial lesions, they may lead to severe and life-threatening complications. If not managed promptly and appropriately, these dissections may propagate from the coronary ostium into the aorta, resulting in catastrophic clinical outcomes. Current literature suggests that dissections with limited aortic extension can often be successfully controlled with emergent ostial stent implantation. In the present case, a 64-year-old male patient developed an iatrogenic dissection extending into the aorta during an elective right coronary artery intervention, which was successfully sealed with ostial stenting. However, acute stent thrombosis occurred in the early post-procedural period, necessitating a second interventional session. Acute stent thrombosis, particularly within the first 24 hours, is a serious complication associated with high mortality, and its pathogenesis involves factors such as inadequate stent expansion, mechanical deformation, the presence of dissection, and high thrombus burden. According to the Dunning classification, which is commonly used for iatrogenic coronary-aortic dissections, Type I and Type II dissections are generally confined to the coronary ostium or demonstrate limited aortic extension and can usually be managed with percutaneous approaches. In contrast, Type III dissections exhibit extensive aortic propagation and often require surgical intervention. In this case, a percutaneous strategy was preferred due to the limited extent of the dissection. Aorto-ostial stenting procedures are technically challenging and may be associated with unique complications such as loss of catheter selectivity, stent deformation, and difficulty in re-engagement. In the present case, protrusion of the ostial stent into the aorta complicated coaxial catheter alignment during the second intervention and increased procedural difficulty. In such scenarios, alternative strategies described in the literature include the use of smaller and non-selective catheters, support with guide extension catheters, and the "side-flap" technique, in which a new lumen is created by advancing a balloon through a side cell of the stent. In patients with acute stent thrombosis, rapid revascularization constitutes the cornerstone of treatment, and potent antithrombotic therapies such as intracoronary vasodilators and glycoprotein IIb/IIIa inhibitors improve procedural success. In this case, a successful outcome was achieved with mechanical correction in combination with intracoronary adenosine and tirofiban infusion. In conclusion, iatrogenic coronary dissection and concomitant acute stent thrombosis are rare but complex clinical entities. Early recognition, appropriate selection of percutaneous strategies, and a multidisciplinary team approach are the key determinants of prognosis in these patients.

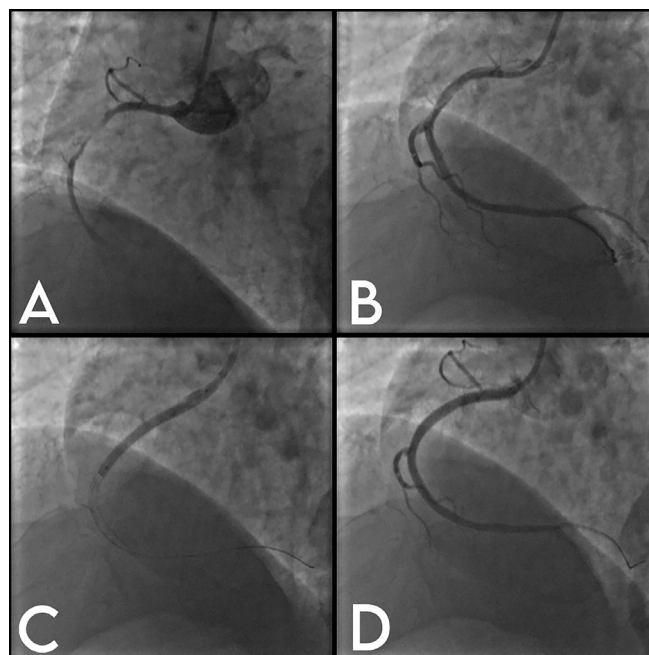


Figure 1. (A) Right coronary artery lesion, (B) coronary dissection extending into the aorta following deep catheter engagement and contrast injection, (C) stent implantation with protrusion into the aorta, (D) final angiographic result

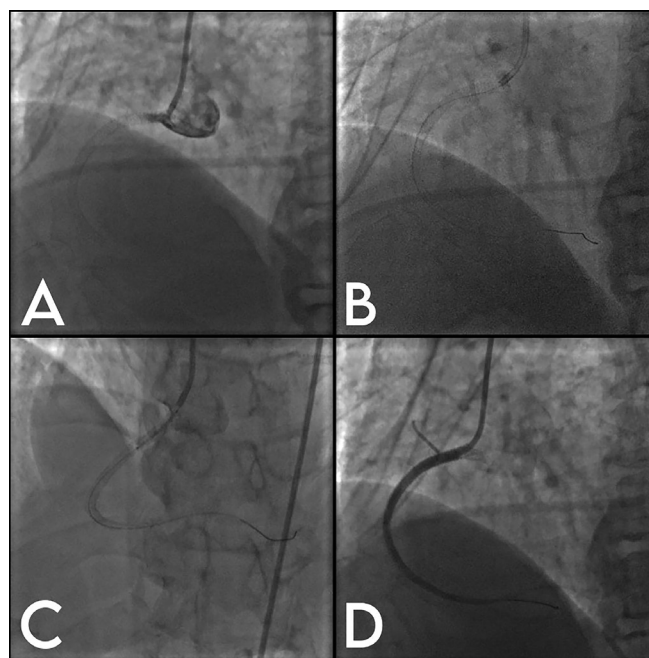


Figure 2. (A) Acute stent thrombosis, (B) side-cell crossing and guidewire passage into the vessel, (C) stent implantation following sequential balloon dilatations of the created neo-lumen, (D) final angiographic result

[OP-51]**Unexpected Acute Stent Fracture During Primary PCI**

Mustafa Gök, Bekir Çalapkorur, Selami Demirelli, Mehmet Kamil Teber, Mehmet Zafer Aydın

University of Health Sciences Türkiye, Kayseri City Hospital, Kayseri

A 43-year-old man with no prior medical history presented with acute retrosternal chest pain for 30 minutes. The electrocardiogram revealed ST-segment elevation in the anterior leads. Emergent coronary angiography demonstrated a 100% thrombotic occlusion of the proximal left anterior descending artery (LAD) (Figure 1a). After predilatation with a 2.0×12 mm Shummei balloon, a 3.5×20 mm Promus Premier drug-eluting stent (DES) (Boston Scientific, Natick, MA, USA) was deployed at 18 atm. Proximal optimization was performed using a 4.5×10 mm Shunmei non-compliant

(NC) balloon at 20 atm. Although TIMI-2 flow was initially restored, real-time fluoroscopy using Cineradiography (ClearStent Live system, Siemens Healthcare, Munich, Germany) revealed focal stent deformity (Figure 1b, c). Intravascular ultrasound (IVUS) was performed for clarification and revealed a proximal LAD hematoma and a Type 3 stent fracture, characterized by multiple strut breaks without complete transection (Figure 1d, Video 1). A 4.0×38 mm DES Promus Premier was subsequently deployed from the left main coronary artery to the LAD and post-dilated with a 4.5×10 mm Simpass NC balloon, resulting in optimal expansion and TIMI-3 flow (Video 2). The patient was discharged on dual antiplatelet therapy, a beta-blocker, an ACE inhibitor, and a statin. At one-month follow-up, he remained asymptomatic. This case demonstrates that stent fracture may occur acutely during primary PCI, even with new-generation DES. IVUS plays a pivotal role in identifying structural stent abnormalities and guiding prompt corrective intervention. In our current patient, a fracture that we thought was after stent overexpansion was observed and successfully treated after imaging with IVUS.

Keywords: Stent fracture, primary percutaneous coronary intervention, fluoroscopic enhancement, intravascular ultrasound

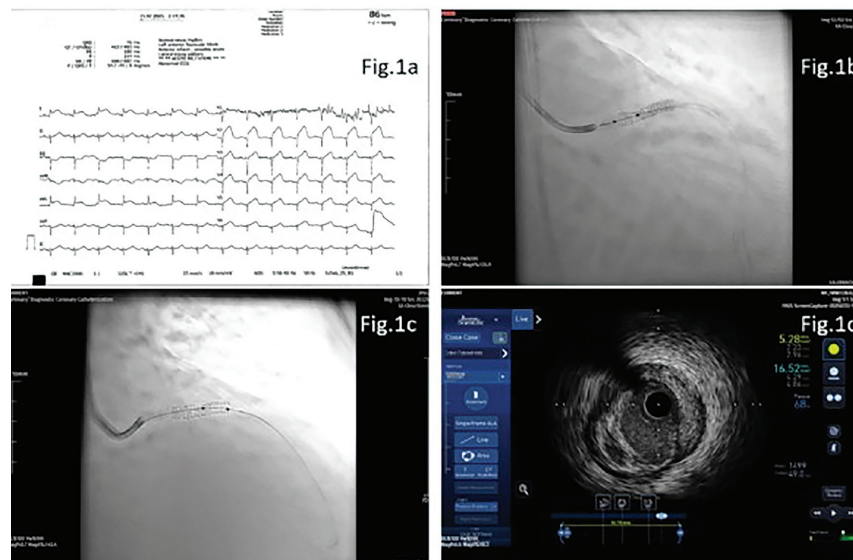


Figure 1.

[OP-52]**Iatrogenic Right Coronary Artery Ostial Dissection During Diagnostic Angiography Successfully Treated with Drug-Eluting Stents**

Sezgin Uzunođlan¹, Behice Hande Őşman Uzunođlan¹, Ođuzhan Abanoz², Esra Danişman², Mahmut Uluganyan²

¹Kırklareli Training and Research Hospital, Kırklareli

²Bezmialem Vakıf University Hospital, İstanbul

A 64-year-old female with hypertension and prior coronary angiography (5 years earlier, report unavailable) presented with chest pain. Blood pressure was 130/60 mmHg, and ECG showed sinus rhythm at 81 bpm without acute ischemic changes. Echocardiography demonstrated preserved left ventricular systolic function (EF 60%) without significant valve disease. Laboratory findings revealed elevated troponin (116 ng/L), LDL cholesterol 165 mg/dL, and TSH 7.29 mIU/L. Myocardial perfusion scintigraphy showed ischemia involving the apical, inferior, and inferoseptal walls (ischemic burden 17%). Coronary angiography via right radial access was performed. During engagement of the right coronary artery (RCA), an ostial dissection developed. Initial attempts to cross the dissection plane with a floppy guidewire were unsuccessful. Sion black wire initially went to subintimal spaces but another sion black wire successfully passed to distal true lumen with pallel wire technique. Angiography demonstrated propagation of the dissection to the mid-RCA segment. To seal the dissection from distal to ostial RCA, two overlapping drug-eluting stents (3.5×38 mm and 4.0×18 mm) were implanted, followed by high-pressure post-dilatation. Final angiography showed complete sealing of the dissection with restoration of TIMI 3 flow and no residual stenosis. The procedure was completed without further complications.

Keywords: Angiography, coronary dissection, complication

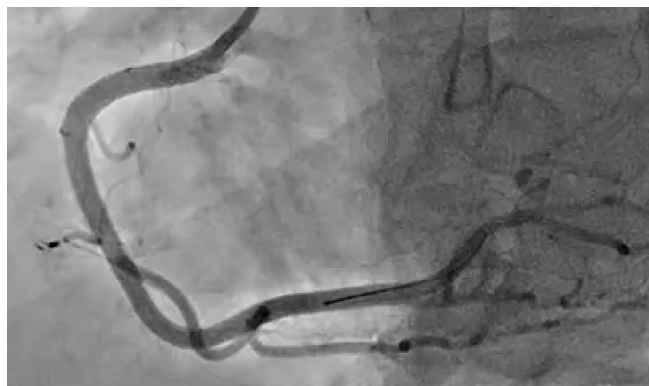


Figure 1. Final image

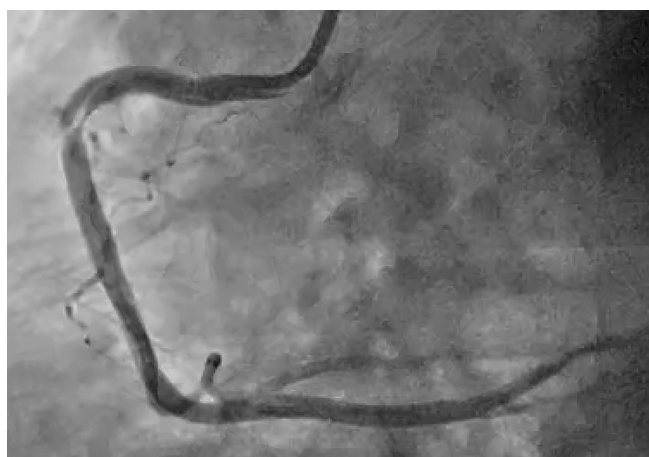


Figure 2. Spiral coronary dissection of RCA

[OP-53]**Dual-Culprit Coronary Thrombosis in STEMI: Simultaneous Occlusion of the Proximal LAD and Circumflex Arteries**

Nihan Bahadır, Fatma Demirci, Fatih Akkaya, İdris Buğra Çerik, Seçkin Dereli, Osman Bektaş, Ahmet Kaya

Department of Cardiology, Ordu University Training and Research Hospital, Ordu

Aim: STEMI usually results from an acute atherothrombotic occlusion in a single coronary artery. Rarely, multiple arteries are affected simultaneously, occurring in about 2-5% of cases. This condition is often associated with severe haemodynamic deterioration, malignant arrhythmias, and cardiogenic shock, and the mortality rate than single-vessel occlusion.

Case Report: A 49-year-old male patient with a history of active cigarette smoking and follow-up for diabetes mellitus presented to the emergency department approximately three hours after the onset of typical retrosternal chest pain. An electrocardiogram showed approximately 2 mm ST-segment elevation in leads V2-V6 and in leads DI and aVL (Figure 1). The patient, hemodynamically stable, received 5000 IU IV heparin, 300 mg oral Aspirin, and 180 mg ticagrelor before emergency coronary angiography. During PPCI, acute thrombotic occlusions with TIMI 0 flow were observed in the proximal LAD and Cx arteries (Figure 2A). The patient had dual thrombotic lesions; revascularisation of the Cx and LAD arteries was planned sequentially. During PPCI, an additional 5000 IU heparin was administered as an intracoronary

bolus. Percutaneous transluminal coronary angioplasty (PTCA) and drug-eluting stent (3.0×24 mm DES) implantation were performed on the proximal LAD lesion, resulting in TIMI III flow without residual stenosis. For the proximal Cx lesion, kissing PTCA was performed on the major OM and lateral Cx, extending from pCx to the major OM, with DES (2.75×20 mm) implantation, achieving TIMI III flow. (Figure 2B and C). Due to a high thrombus burden, abciximab 0.25 mg/kg bolus was administered as a glycoprotein IIb/IIIa inhibitor, followed by intravenous infusion. Post-procedure, the patient was haemodynamically stable, with no angina, ST elevation on EGM, or malignant arrhythmias, and did not require intra-aortic balloon pump support. Echocardiography revealed hypokinesia of the anterior wall, with a left ventricular ejection fraction of 36-40%. Further assessments for hypercoagulability, thrombophilia, or embolic sources did not reveal any significant etiological factors. The patient was discharged with guideline-adherent medical therapy.

Conclusion: Simultaneous multiple coronary artery thrombosis, a rare form of STEMI, can be hard to recognize and may be underreported as some patients die before hospital due to shock or arrhythmias. Most cases involve the right coronary or circumflex artery with the LAD. The pathophysiology of multiple acute coronary thromboses isn't fully explained. Proposed mechanisms include systemic inflammation, hypercoagulability, widespread plaque rupture, catecholamine increase, and coronary embolisation. The optimal strategy for multiple acute thrombotic occlusions isn't well defined, and in most cases, intervention is performed on both lesions in the same session.

Keywords: STEMI, acute coronary syndrome, dual culprit lesion, multiple coronary thrombosis, primary percutaneous intervention

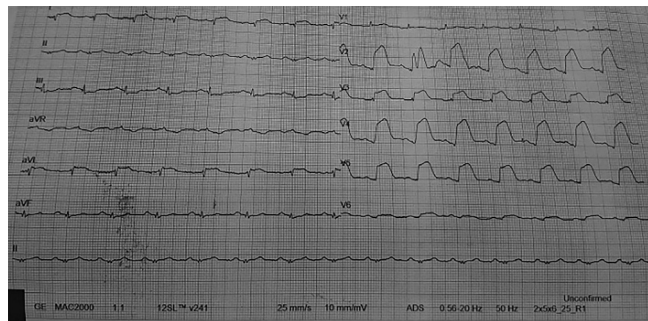


Figure 1. The EGM revealed ST elevations in leads V2-V6 and DI-aVL

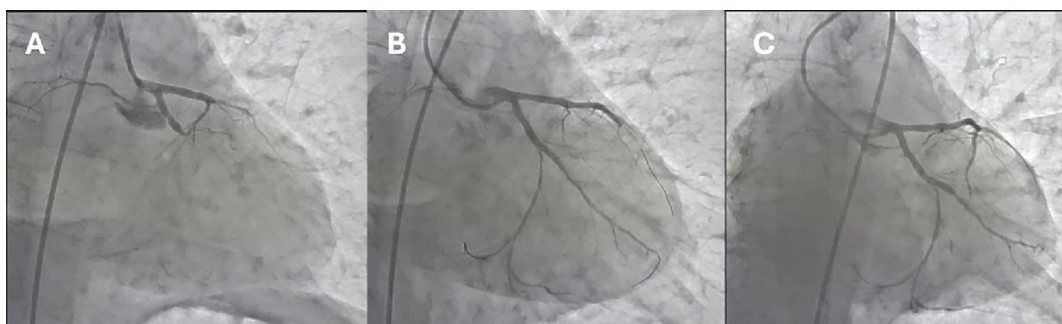


Figure 2. A) Coronary angiogram of the left system showing acute 100% thrombotic occlusion of the left coronary artery and circumflex artery B) Coronary angiogram of the left system showing revascularised major obtuse marginal branch with lateral Cx

[OP-54]**A Case of Type B Aortic Dissection Presenting with Acute Inferior Myocardial Infarction and Its Successful Management**

Veli Küçüksevçili, Burçin Küçüksevçili

Department of Cardiology, Karabük University Training and Research Hospital, Karabük

Aim: Aortic dissection classically presents with sudden onset of chest and back pain. However, in some cases, it can mimic myocardial infarction. Although this is mostly seen in Type A dissections, it has also been reported in type B dissections. Stanford type B aortic dissection includes dissections that start from the distal left subclavian artery and involve the descending aorta, and constitutes approximately 25-40% of all aortic dissections. Our case presented with type B dissection and inferior myocardial infarction, followed by complete revascularization and clinical stabilization with right radial intervention. The importance of rapid clinical diagnosis and right radial intervention in our type B dissection case presenting with inferior myocardial infarction is discussed. In type B dissections, hypotension, increased afterload and catecholamine release can disrupt myocardial oxygen balance and lead to the development of type 2 MI. In our case, the successful management of type B aortic dissection with primary coronary occlusion in the right coronary artery is described.

Case Report: A 56-year-old female patient presented to the emergency department with sudden onset of constricting chest pain. She had no history of chronic diseases. There was a family history of atherosclerotic heart disease at an early age. On physical examination, her heart rate was 75 beats/min and arterial blood pressure was 120/70 mmHg. ECG showed ST segment elevation in the inferior derivations (D2, D3, aVF). Bedside transthoracic echocardiography revealed inferior LV wall hypokinesia with an EF of 45% (M-mode). No pathology was observed in the ascending aorta. The patient was diagnosed with inferior MI and given loading doses of 70 U/kg UFH, 180 mg Ticagrelor, and 300 mg ASA before being taken to the catheterization laboratory. A right femoral approach was performed. A 7FJR4 guiding catheter was advanced through a 0.035-inch guide wire, but the guide wire could not be advanced into the descending thoracic aorta, and a radiocontrast image was obtained (Figure 1). A bedside transthoracic echocardiography was repeated after observing findings consistent with dissection in the descending thoracic aorta. No pathology was observed in the ascending aorta or at the level of the sinus of valsalva. An urgent consultation was made with the cardiovascular surgery clinic, and thoracic CT angiography was performed without delay to visualize the extent of the dissection. A dissection flap extending from the end of the aortic arch to the level of the iliac bifurcation was observed. No pathology was seen at the ascending aorta and aortic arch levels. The diagnosis of type B aortic dissection was confirmed, but due to the persistence of the patient's

constricting chest pain and ECG findings, it was concluded that the current clinical presentation could not be explained by type B aortic dissection. The patient was taken back to the catheterization laboratory. Since the dissection line was seen to extend from the distal left subclavian artery to the level of the iliac bifurcation on thoracic CT angiography, a right radial approach was planned. A 5FJR4 guiding catheter was placed at the RCA ostium. The RCA artery was observed to be occluded proximally (culprit lesion). Successful percutaneous coronary intervention was performed on the RCA artery, and full patency was achieved. Left system imaging showed no critical lesions in the LMCA, LAD, and CX arteries. Laboratory results showed Creatinine: 0.8 mg/dL, Urea: 29 mg/dL, Troponin: <0.010, CRP: 6.2 mg/dL, D-dimer: 1980 µg/L, Hgb: 12.1 g/dL, WBC 9.6x10⁹/L. The patient was admitted to the coronary intensive care unit for monitoring. The patient remained stable during follow-up and was referred to the cardiovascular surgery clinic. A control CT angiogram showed no progression along the dissection line, leading the cardiovascular surgery clinic to decide on medical follow-up. A control CT scan revealed a LV EF of 55% and minimal aortic insufficiency. No pathology was observed in the ascending aorta or pericardial area. Following clinical follow-up, the patient was discharged with a treatment plan including ASA 100 mg 1x1 orally, ticagrelor 90 mg 2x1 orally, ramipril 2.5 mg 1x1 orally, bisoprolol 5 mg 1x1 orally, and atorvastatin 40 mg 1x1 orally. The clinical presentation of Type B dissection is not always typical. Rarely, it may present with myocardial infarction. Although this is more common in type A dissections with coronary ostium involvement, in type B dissections, hypotension, increased afterload, and catecholamine release can disrupt myocardial oxygen balance, leading to the development of Type 2 MI. Therefore, the troponin elevation and ECG changes seen in these patients may not always indicate primary coronary occlusion. Our case presented with type B dissection and primary coronary occlusion. Although Type 2 MI is usually seen in Type B dissections through indirect mechanisms, the possibility of direct coronary occlusion, as in our case, should be considered. In similar cases, the selection of the peripheral intervention area by observing the extent of the dissection line with rapid radiological imaging is important.

Conclusion: Stanford type B aortic dissection presenting with myocardial infarction is rare but clinically high-risk. In these cases, myocardial ischemia usually develops through secondary hemodynamic and metabolic mechanisms rather than primary coronary occlusion. Therefore, aortic dissection should always be considered in the differential diagnosis, especially in patients exhibiting atypical clinical features or those whose presentation is not entirely consistent with classic acute coronary syndrome. Anticoagulant and thrombolytic therapies administered to patients mistakenly diagnosed with acute coronary syndrome can lead to dissection progression and increased mortality. Therefore, early and accurate diagnosis is critically important. The use of rapid imaging techniques and a multidisciplinary approach in suspected cases play a decisive role in patient management. In conclusion, although the presentation of type B dissection with MI is rare, clinicians need to be highly aware of this possibility. Early diagnosis and appropriate treatment strategies can significantly improve prognosis.

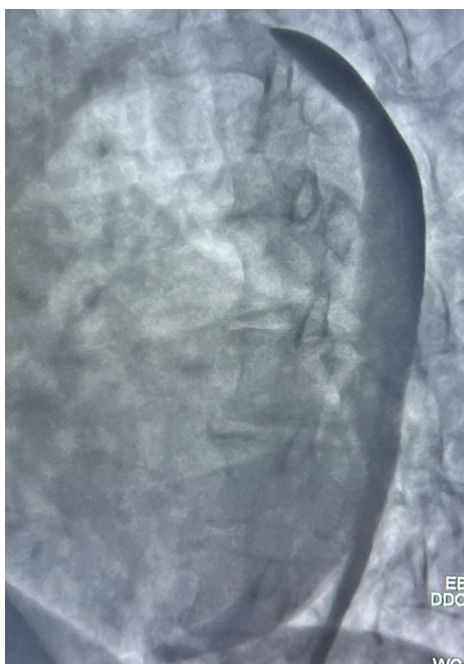


Figure 1. Angiographic image of type B aortic dissection

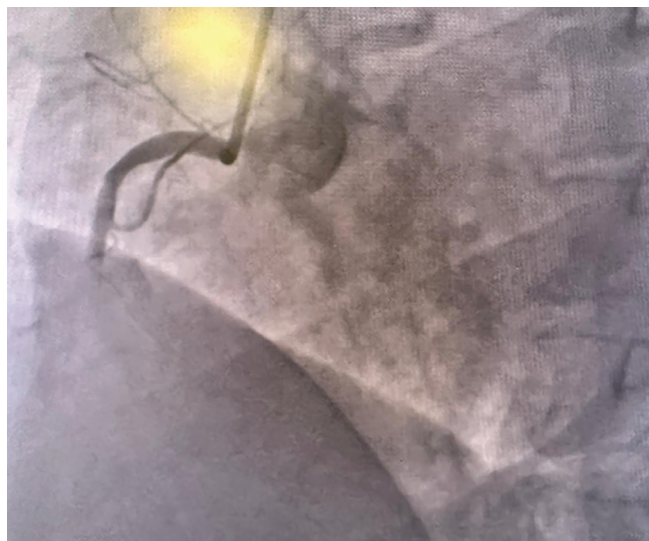

Figure 3. Primary occluded RCA artery

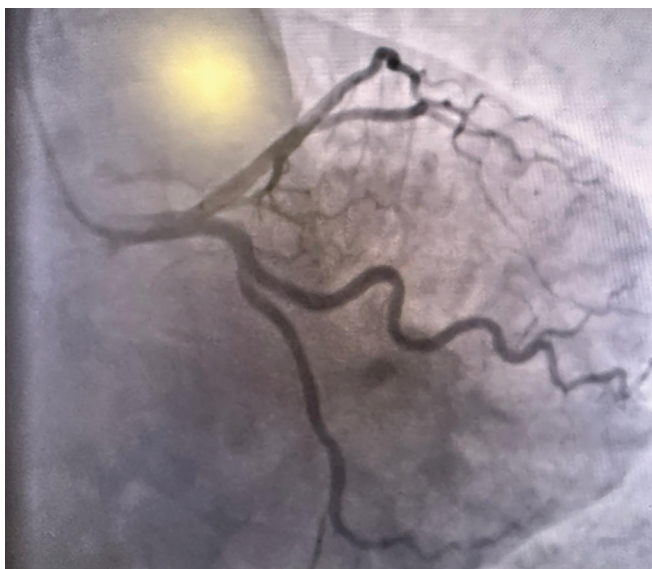

Figure 2. LAD and CX artery coronary angiographic image

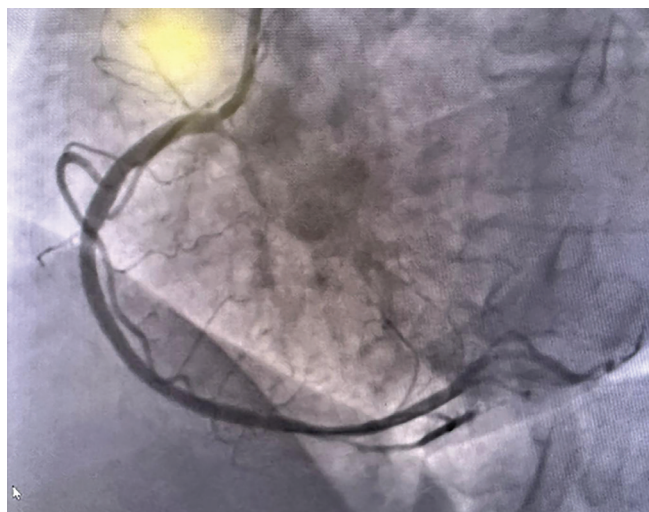


Figure 4. RCA artery after percutaneous coronary intervention

[OP-55]**Unexpected Culprit: Proximal Right Coronary Artery Occlusion Mimicking Anterior STEMI—A Case Report**

Müzeyyen Gizem Parmak, Alperen Taş, Alp Yıldırım

Department of Cardiology, Kırşehir Ahi Evran University Faculty of Medicine, Kırşehir

Aim: Acute coronary syndromes (ACS), particularly ST-segment elevation myocardial infarction (STEMI), require rapid and accurate diagnosis for timely reperfusion. In these patients, rapid diagnosis and timely life-saving percutaneous coronary intervention (PCI) are of critical importance. Electrocardiography (ECG) is the primary diagnostic tool that provides immediate information regarding myocardial ischemia. Traditionally, ST-segment elevation in the precordial leads (V1-V6) indicates anterior myocardial infarction typically caused by occlusion of the left anterior descending (LAD) artery. In contrast, ST-segment elevation in inferior leads (II, III, aVF) usually indicates inferior myocardial infarction caused by right coronary artery (RCA) occlusion. These typical electrocardiographic patterns, often supported by reciprocal ST-segment depression, and their angiographic correlations guide acute management and pre-angiographic clinical decision-making in patients with myocardial infarction. However, patient-specific variations in coronary anatomy may lead to atypical electrocardiographic patterns, resulting in significant diagnostic challenges and delays in life-saving reperfusion therapy. This case report describes a rare and instructive case of a 73-year-old female patient presenting with ST-segment elevation in anterior precordial leads (V1-V4). Despite ST-segment elevation in anterior leads, coronary angiography demonstrated a patent LAD artery and total occlusion of the proximal RCA. This discrepancy between electrocardiographic findings and the culprit artery makes this case particularly noteworthy. This case report describes the clinical course, analyzes the atypical and misleading ECG-angiography correlation, discusses the underlying mechanisms of precordial ST-segment elevation in RCA occlusion, and emphasizes the importance of a careful and comprehensive diagnostic approach in STEMI patients presenting with atypical electrocardiographic findings.

Case Report: A 73-year-old female patient with a history of chronic kidney disease requiring hemodialysis (3 sessions per week), atrial fibrillation, and coronary artery disease presented to the emergency department with new-onset epigastric pain radiating to the back. On admission, her vital signs were as follows: blood pressure 152/80 mmHg, heart rate 85 beats per minute, and oxygen saturation 97% on room air. The admission ECG demonstrated atrial fibrillation with 1 mm ST-segment elevation in lead aVR, marked ST-segment elevation in leads V1-V4, and ST-segment depression with T-wave inversion in inferior leads (II, III, and aVF). Typical chest pain and electrocardiographic findings were consistent with acute anteroseptal STEMI, and the patient was urgently transferred to the catheterization laboratory for coronary angiography. Coronary angiography demonstrated: 40% stenosis in the proximal LAD and a long 60% stenosis in the mid LAD segment; 30-40% stenosis in the mid circumflex artery and 40-50% stenosis distal to the obtuse marginal branch. The RCA was found to be totally thrombotically occluded in the proximal segment with retrograde distal filling from the left coronary system. Primary PCI of the RCA was performed during the same session. Sequential balloon dilatations were performed using 2.0×12 mm and 2.5×15 mm balloons. Due to inadequate restoration of flow, intracoronary tirofiban was administered. Subsequently, sequential dilatations were performed using 3.0×15 mm non-compliant balloons in the proximal RCA and within the mid-RCA stent segment. Promus 2.75×32 mm and Promus 3.0×28 mm drug-eluting stents were then implanted in an overlapping fashion. Due to suspected dissection in the mid RCA, an additional Promus 3.0×20 mm stent was implanted. Post-dilatations were subsequently performed. TIMI-3 flow was achieved in the RCA. The patient's clinical condition improved, chest pain resolved, and ECG findings normalized. The patient was admitted to the intensive care unit for medical management, with elective LAD PCI planned. An additional hemodialysis session was planned following the

procedure. Follow-up ECG obtained after PCI demonstrated greater than 70% resolution of ST-segment elevation in precordial leads V1-V4. Chest pain resolved. Dual antiplatelet therapy and low-molecular-weight heparin were initiated in the hemodynamically stable patient. On admission, CK-MB level was 1 U/L and high-sensitivity troponin-I level was 35.4 ng/L. Peak CK-MB reached 117.7 U/L and peak high-sensitivity troponin-I reached 127,789.3 ng/L during follow-up. Follow-up echocardiography demonstrated an LVEF of 50%, ascending aorta diameter of 37 mm, biatrial enlargement, mild aortic regurgitation, moderate mitral regurgitation, and moderate eccentric tricuspid regurgitation. The hospital course was uneventful. The patient was discharged in stable condition after four days with optimized medical therapy. Classically, electrocardiographic findings of RCA occlusion include ST-segment elevation in leads II, III, and aVF. Simultaneous ST-segment elevation in both inferior and precordial leads may occasionally be observed; however, isolated ST-segment elevation in precordial leads due to RCA occlusion is an uncommon clinical presentation. In acute coronary syndrome, ECG is essential for identifying the infarct-related artery, determining the type of myocardial infarction, guiding clinical decision-making and treatment strategy, predicting prognosis, and enabling timely reperfusion therapy. Traditionally, ST-segment elevation in precordial leads indicates occlusion of the LAD artery. However, in our case, RCA occlusion resulted in atypical ST-segment elevation in leads V1-V4. While RCA occlusions typically present with ST-segment elevation in inferior leads, precordial ST elevation is rarely observed in such cases. Possible mechanisms underlying this ECG pattern include a co-dominant coronary system, isolated right ventricular myocardial infarction, and as observed in our patient, compromised blood supply to the right ventricular outflow tract (RVOT) due to involvement of the conus branch of the RCA. The conus branch of the RCA supplies the right ventricular outflow tract. Occlusion of this branch may result in isolated RVOT infarction. Electrically, the RVOT is represented by the anterior precordial leads V1-V4 on the ECG. This may produce ST-segment elevation in anterior precordial leads without inferior ST-segment elevation. This atypical pattern may mimic anterior myocardial infarction despite a patent LAD artery and may represent a diagnostic pitfall for clinicians. Our case describes a patient presenting with anterior ST-segment elevation, elevated cardiac troponin levels, and angiographic evidence identifying the right coronary artery as the culprit vessel. Coronary angiography revealed that the culprit lesion was located in the proximal segment of the right coronary artery. In a patient with right coronary dominance and preserved right ventricular function, involvement of the conus branch within the lesion segment likely affected the myocardial territory supplying the right ventricular outflow tract, resulting in an atypical electrocardiographic presentation. This diagnostically challenging presentation highlights the importance of a comprehensive and systematic evaluation in complex clinical scenarios in order to ensure that life-saving percutaneous coronary intervention can be performed without delay. As demonstrated in our case, when no culprit lesion is identified in the left coronary system in a patient presenting with ST-segment elevation in the anteroseptal leads, prompt evaluation of the right coronary artery should also be considered.

Conclusion: Electrocardiography is a crucial tool for predicting the location of the culprit artery in acute coronary syndrome, particularly in STEMI. Although ST-segment elevation in anterior leads is usually associated with LAD occlusion, proximal RCA occlusion may rarely produce a similar electrocardiographic pattern. This case reminds clinicians to consider atypical presentations of STEMI. Not all precordial ST-segment elevations indicate LAD occlusion. It also emphasizes the importance of integrating ECG findings with clinical presentation and imaging modalities such as coronary angiography. Because conventional ECG-angiographic correlations may sometimes be misleading and may result in delayed diagnosis and reperfusion.

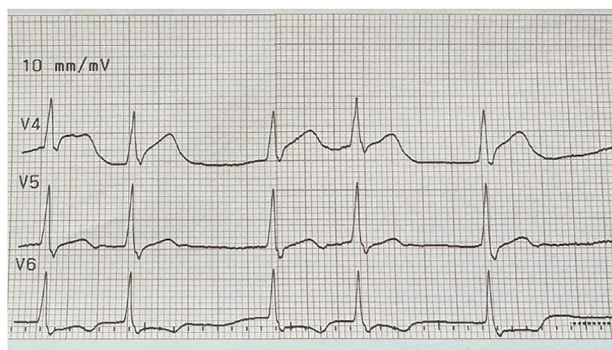
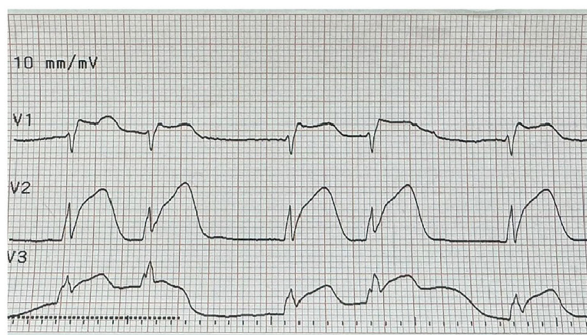
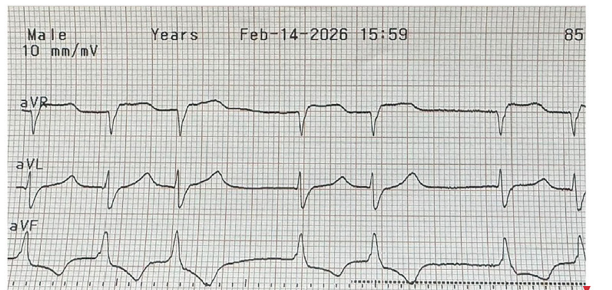
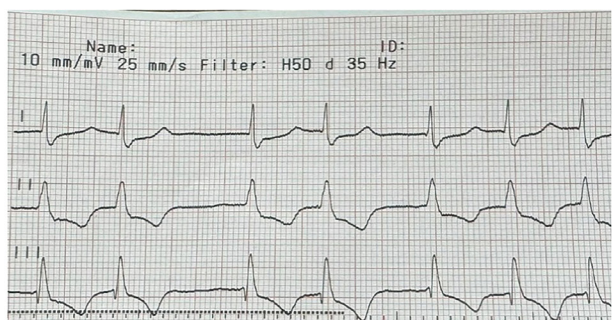


Figure 1. The admission electrocardiogram demonstrated atrial fibrillation rhythm, 1 mm ST-segment elevation in lead aVR, marked ST-segment elevation in leads V1–V4, and ST-segment depression with T-wave inversion in leads II, III, and aVF

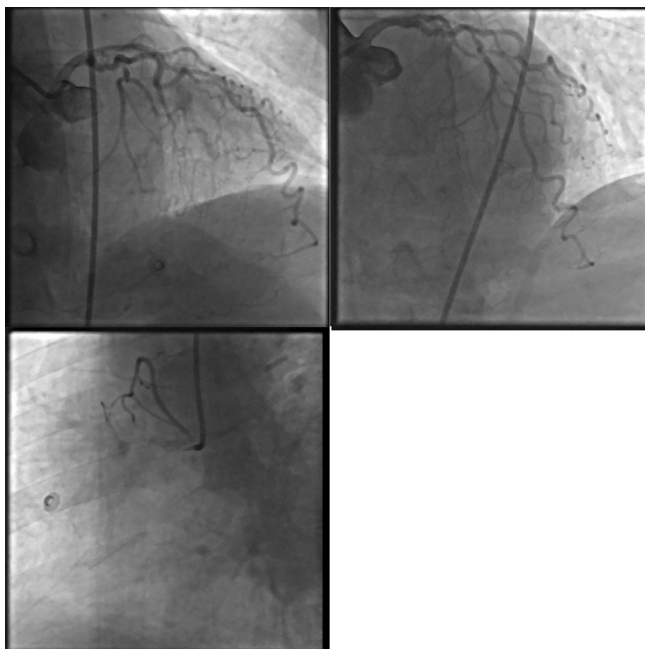


Figure 2. Coronary angiography demonstrated a 40% stenosis in the proximal LAD and a long 60% stenosis in the mid LAD. A 30-40% stenosis was observed in the mid circumflex artery, and a 40-50% stenosis distal to the obtuse marginal branch. The proximal right coronary artery was found to be thrombotically occluded, with retrograde distal filling from the left coronary system

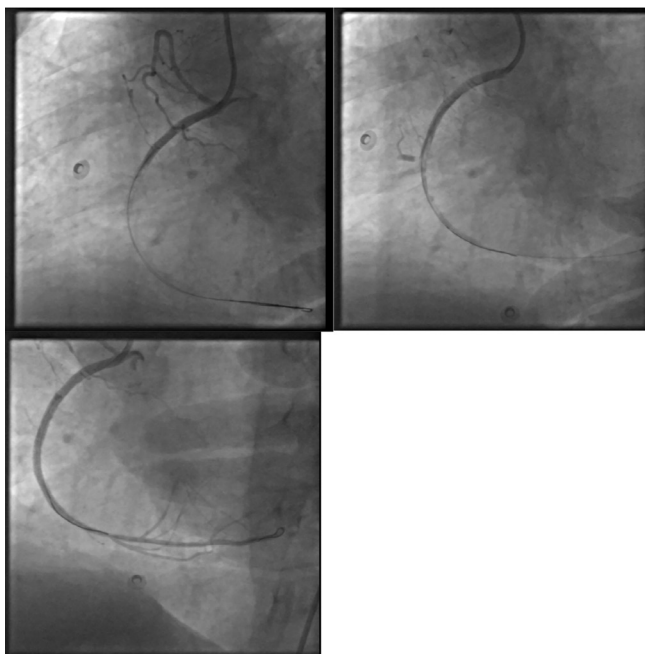


Figure 3. TIMI grade 3 flow was achieved in the right coronary artery following the intervention. The patient's clinical condition improved and chest pain resolved

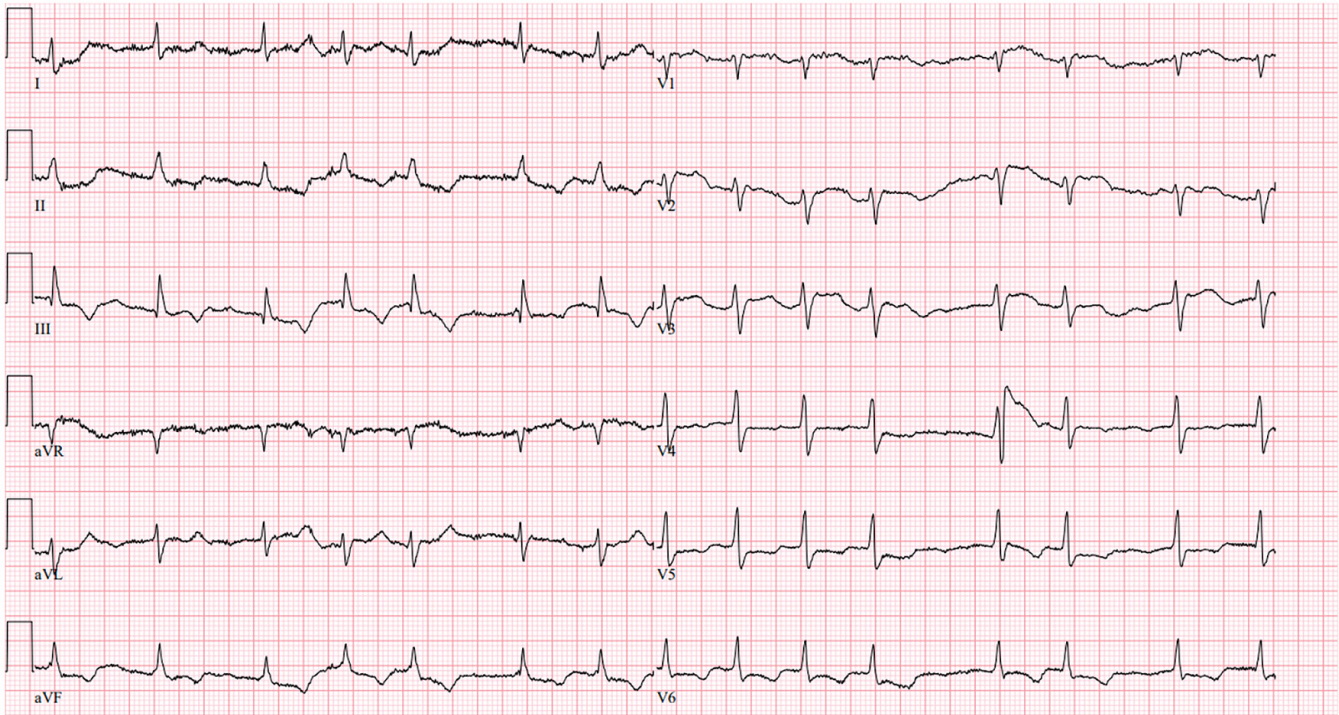


Figure 4. The post-procedural electrocardiogram demonstrated normalization of the ST segments

[OP-56]

Left Ventricular Lateral Wall Pseudoaneurysm After Acute Myocardial Infarction: A Rare Case Report

Müzeyyen Gizem Parmak, Erdoğan Sökmen

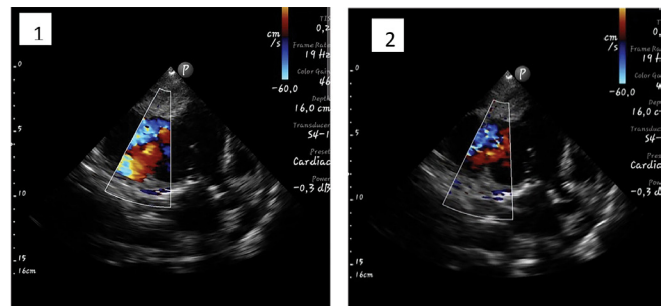
Department of Cardiology, Kırşehir Ahi Evran University Faculty of Medicine, Kırşehir

Case Report: A 79-year-old female patient with a known history of diabetes mellitus, hypertension, coronary artery disease, and chronic heart failure underwent coronary angiography on September 19, 2025, due to acute myocardial infarction (MI). Coronary angiography revealed a total occlusion in the proximal left circumflex artery (LCx), for which percutaneous coronary intervention (PCI) was performed. The patient later presented to the emergency department with complaints of chest and back pain. Medications: Acetylsalicylic acid, clopidogrel, atorvastatin, ramipril, metoprolol, spironolactone, isosorbide mononitrate, and trimetazidine hydrochloride. Vital signs on admission: Blood pressure: 110/60 mmHg; Heart rate: 90 bpm; Oxygen saturation: 92% (on supplemental oxygen). Physical examination: Decreased breath sounds were noted at the left lung base, with rales present in the middle and lower zones. The abdomen was soft, non-tender, and non-distended, with normal bowel sounds and no guarding or rebound tenderness. Peripheral pulses were palpable bilaterally, and mild bilateral lower-extremity edema was observed. Laboratory findings: WBC: $8.52 \times 10^3/\mu\text{L}$, Hb: 12.9 g/dL, platelet: $183 \times 10^3/\mu\text{L}$, creatinine: 1.3 mg/dL, troponin I: 85 ng/L \rightarrow 84 ng/L, CK-MB: 4.4 $\mu\text{g/L}$. Thoracic CT findings: Cardiomegaly and bilateral pleural effusion were observed. Ground-glass opacities were more prominent in the perihilar regions, accompanied by interlobular septal thickening in both lungs. Due to persistent chest pain, transthoracic echocardiography (TTE) was performed, which demonstrated a left ventricular ejection fraction (LVEF) of 35%. The posterolateral wall was aneurysmal, and a 2.3 cm defect consistent with a pseudoaneurysm was identified in the lateral wall. Approximately 30 mm of pericardial effusion was noted. The right heart chambers appeared normal. On color Doppler imaging, a bidirectional turbulent flow was visualized along the lateral wall of the left ventricle, findings consistent with a left ventricular pseudoaneurysm (Figures 1-4). The patient was subsequently referred to a tertiary cardiac surgery center for definitive surgical management. Left ventricular (LV) pseudoaneurysm is a rare complication, occurring in less than 0.1% of patients following myocardial infarction (MI). In the absence of surgical intervention, the condition carries a mortality rate of up to 48%. LV pseudoaneurysm results from a myocardial rupture contained by the pericardium and differs from a true aneurysm in that it lacks myocardial tissue within its wall. The most common symptoms are chest pain and dyspnea. In rare cases, the condition may present with persistent pericarditis. Approximately 3% of patients may experience sudden cardiac death, while 12-25% remain asymptomatic. The most frequent etiologic factors are myocardial infarction and cardiac surgery. Reported risk factors include advanced age, female sex, hypertension, and inferior or lateral wall MI. The most common sites of involvement are the postero-inferior wall, followed by the posterolateral and anterior walls; in contrast, true LV aneurysms are more often located in the anterior or apical regions. Patients with LV pseudoaneurysm typically present within two months after MI. Physical examination findings are usually non-specific; a systolic murmur or friction rub may occasionally be heard. Electrocardiography (ECG) often lacks specific diagnostic features, though bradycardia, junctional rhythm, or ischemic changes may be present. On chest radiography, a convexity or mass-like contour adjacent to the cardiac silhouette may be observed. Because of the nonspecific clinical presentation, diagnosis is often challenging. However, the risk of rupture in pseudoaneurysm cases reaches approximately 30-45%, making rapid diagnosis crucial. Transthoracic echocardiography (TTE), as a non-invasive and widely available imaging modality, serves as the first-line diagnostic tool in suspected cases. A neck-to-cavity ratio of <0.5 , along with bidirectional turbulent flow at the neck or pulsed-wave Doppler, strongly supports the diagnosis of LV pseudoaneurysm. Due to limited visualization of the inferior wall

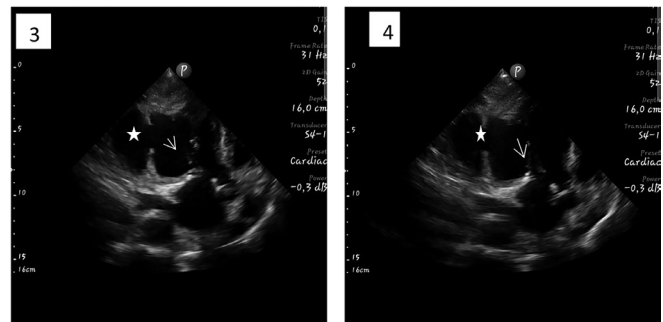
with TTE, transesophageal echocardiography (TEE) may provide additional diagnostic detail when required. Cardiac magnetic resonance imaging (MRI) can aid in defining the pseudoaneurysm's location, extent, and relation to surrounding structures. Although it is non-invasive and free from ionizing radiation, its limited availability remains a constraint. Nevertheless, cardiac MRI has demonstrated 100% sensitivity and 83% specificity in differentiating pseudoaneurysms from true aneurysms. Cardiac computed tomography (CT) is another non-invasive imaging option that can provide three-dimensional anatomical and functional information on the myocardium and pericardium. Its limitations include radiation exposure, contrast use, and restricted accessibility. Left ventriculography, though rarely performed, can be used for diagnosis and has an accuracy rate of approximately 85%. However, it is not routinely recommended because of the potential risk of thrombus dislodgement. Once the diagnosis of LV pseudoaneurysm is confirmed, management includes hemodynamic stabilization and urgent surgical repair. The risk of rupture is significantly higher than the operative risk, and medical management alone is associated with mortality rates approaching 50%. In hemodynamically unstable patients, inotropic support and, when necessary, temporary mechanical circulatory support should be provided. Surgical treatment is generally performed on an emergency basis and consists of resection of the pseudoaneurysm with closure of the LV wall defect, either directly or with the use of a patch.

Conclusion: Left ventricular pseudoaneurysm is a rare complication following myocardial infarction. The absence of specific clinical features and the subtlety of symptoms make diagnosis challenging. Although infrequent, LV pseudoaneurysm is a life-threatening condition. Early recognition through clinical suspicion and the use of non-invasive imaging modalities such as transthoracic echocardiography (TTE) is essential, as timely diagnosis and surgical repair significantly reduce mortality.

Keywords: Left ventricular pseudoaneurysm, myocardial infarction, echocardiography, cardiac rupture, cardiac surgery, chest pain



Figures 1, 2. Color Doppler imaging demonstrating bidirectional shunt flow and turbulent flow along the lateral wall of the left ventricle.



Figures 3, 4. Transthoracic echocardiographic (TTE) images showing the pseudoaneurysm located in the lateral wall of the left ventricle. The asterisk (*) indicates the pseudoaneurysm, while the arrow (→) points to the left ventricle.

[OP-57]**Cerebellar Stroke Following Saphenous Vein Graft Stenting: A Thromboembolic Complication**

Ahmet Özsipahi, Ali Gökhan Özyıldız, Hakan Duman

Department of Cardiology, Recep Tayyip Erdoğan University Faculty of Medicine, Rize

Case Report: A 65-year-old male with type 2 diabetes mellitus and a history of CABG presented with chest pain and dyspnea. Elevated troponin levels prompted coronary angiography under the preliminary diagnosis of acute coronary syndrome. Angiography revealed occlusion of the native coronary arteries; the left internal mammary artery (LIMA) to left anterior descending (LAD) graft was patent; the diagonal SVG was patent, while the SVGs to the obtuse marginal branch and the right coronary artery were occluded as stumps. Following medical stabilization, elective PCI with stent implantation was performed at the target lesion. Owing to suspicion of intra-graft thrombus migration, the patient was monitored in the intensive care unit. During follow-up, he developed nausea and vertigo. Cranial diffusion-weighted magnetic resonance imaging (DW-MRI) demonstrated diffusion restriction in the right cerebellar hemisphere, consistent with acute ischemic infarction. Following neurological consultation, hypertonic saline was administered together with dual antiplatelet therapy (acetylsalicylic acid plus clopidogrel). His symptoms resolved, and he was discharged after a brief inpatient observation without any neurological sequelae. Embolization of thrombus and atheromatous debris during SVG PCI may lead not only to distal coronary embolism but also, in rare cases, to cerebral embolism. Posterior circulation strokes often manifest with non-specific symptoms such as nausea, vertigo, and imbalance, which can delay recognition. Therefore, early neuroimaging is of critical importance whenever new neurological symptoms develop after PCI.

Conclusion: Cerebellar infarction following elective SVG stenting is a rare but serious thromboembolic complication. Preprocedural assessment of embolic risk and heightened postprocedural clinical vigilance in high-risk graft interventions may improve patient outcomes.

Keywords: Stroke, obtuse marginal, percutaneous coronary intervention, saphenous vein graft, cerebellar infarction, stenting

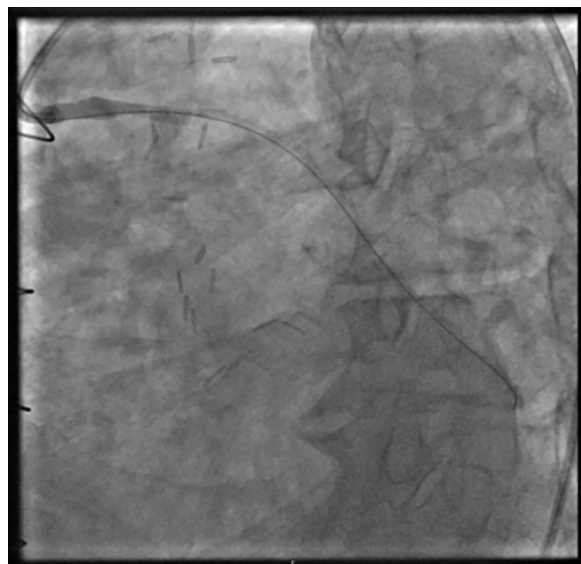


Figure 1. Angiography saphenous vein graft (SVG)

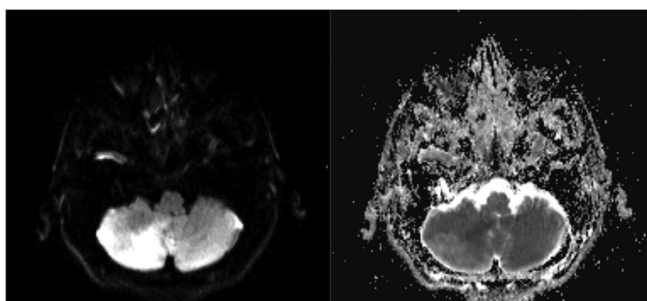


Figure 2. Serebellar enfarkt MRI

[OP-58]**Invert Provisional Approach and DK-Culotte Salvage Strategy for LAD-D1 Medina 0,0,1 Bifurcation Lesion in Acute Anterolateral STEMI**

Aydın Can Ulusoy, Nisanur Kol, Metin Çoksevrim

Department of Cardiology, Ondokuz Mayıs University Faculty of Medicine, Samsun

Aim: Coronary bifurcation lesions are one of the complex anatomical subgroups that pose technical challenges in interventional cardiology practice, particularly in the context of acute ST-elevation myocardial infarction (STEMI). While isolated side branch lesions with Medina 0,0,1 morphology are generally managed with a provisional strategy, unexpected involvement of the main branch in an acute thrombotic environment can alter the intervention plan. In this case, a 44-year-old male patient with no known comorbidities presented with anterolateral STEMI. Coronary angiography revealed a Medina 0,0,1 lesion at the left anterior descending artery (LAD)-first diagonal branch (D1) bifurcation. Initially, an invert provisional approach was preferred; however, due to the development of significant residual stenosis and dissection in the main branch (LAD) during the procedure, a double kissing (DK) culotte technique with two stents was used. The procedure was successfully completed, and the patient was discharged without complications. This case demonstrates that even in isolated side branch lesions in the context of STEMI, dynamic anatomy may necessitate a transition to complex techniques with two stents. Coronary bifurcation lesions account for approximately 15-20% of patients undergoing percutaneous coronary intervention (PCI). The basic principle in the management of these lesions is to prefer a single-stent provisional strategy whenever possible. However, in the context of acute myocardial infarction, thrombus burden, vasospasm, and plaque instability complicate anatomical assessment and may necessitate a change in strategy during the procedure. According to the Medina classification, lesions 0, 0, and 1 are bifurcation lesions involving only the side branch ostium. This morphology can generally be addressed by preserving the main branch and stenting the side branch. The invert provisional approach stands out as a rational strategy in cases where the dominant and clinically significant side branch is prioritized. However, in acute STEMI, worsening of the main branch after side branch stenting may necessitate a switch to two-stent techniques. This case report discusses the management of a Medina 0,0,1 lesion at the LAD-D1 bifurcation in a young patient presenting with anterolateral STEMI, and the transition process from invert provisional to DK-culotte technique.

Case Report: A 44-year-old male patient presented to the emergency department with chest pain that had started approximately two hours prior. His medical history did not include hypertension, diabetes mellitus, hyperlipidemia, or smoking. There was no family history of early-onset coronary artery disease. Physical examination revealed a blood pressure of 130/80 mmHg and a heart rate of 88/min. No extra sounds were detected on cardiac auscultation.

Electrocardiography and Laboratory

A 12-lead ECG showed ST elevation in leads I, aVL, and V2-V5; reciprocal ST depression was present in the inferior leads. The findings were consistent with anterolateral STEMI. Cardiac troponin levels were slightly elevated at admission.

The patient was admitted to the catheterization laboratory with an indication for primary PCI.

Coronary Angiography Findings

- A 7F guide catheter was inserted through the left femoral artery. Imaging of the left coronary system showed:
 - The left main coronary artery was normal.
 - No significant atherosclerotic lesions were observed in the proximal and middle segments of the LAD.
 - A total lesion was present at the ostium of the first diagonal branch (D1).

- The main branch current of LAD was TIMI 3, and the current of D1 was TIMI 0.

- The bifurcation lesion was evaluated as 0, 0, 1 according to the Medina classification.

Entrepreneurial Strategy and Transaction Details**1. Strategy Selection: Invert Provisional**

An inverted provisional approach was preferred because the lesion involved only the D1 ostium and the diagonal branch was of large caliber and clinically significant.

- LAD and D1 were each crossed with “0.014” coronary wires.
- First, a drug-eluting stent of appropriate diameter and length was placed in the D1 lesion.
- A kissing balloon was planned after stent implantation.

2. Taking the Major More Seriously

In the LAD segment after D1 stent implantation:

- Current slowdown,
- Possible dissection line view.

This condition was monitored. It was thought to have developed due to stent protrusion, carina shift, and plaque redistribution. At this stage, it was determined that continuing with only the kissing balloon would be insufficient, and the decision was made to switch to a two-stent strategy.

DK-Culotte Technique Application

The DK-culotte technique with two stents was preferred. The reason for this is:

- The fact that the side branch was already stented,
- Development of a significant lesion in the main branch,
- Aiming for a symmetrical metal distribution.

Steps to Follow

- LAD has been rewired.
- The first kissing balloon dilation was performed.
- A drug-eluting stent of appropriate diameter was implanted in the LAD.
- D1 has been rewired.
- A second kissing balloon was applied.
- Proximal optimization technique (POT) was performed.

In the Final Angiogram:

- LAD and D1 current TIMI 3,
- Residual stenosis <10%,
- There was no evidence of dissection or distal embolization.

The procedure was completed without complications.

Hospital Course

- The patient was monitored in the coronary intensive care unit.
- Hemodynamic stability was maintained.
- ST segment regression was observed on the ECG.
- Troponin levels peaked and then declined.
- Echocardiography revealed hypokinesia in the anterolateral segment; LVEF was measured at 45%.

The patient was discharged on day 2 without complications after dual antiplatelet therapy (aspirin + potent P2Y12 inhibitor), high-dose statin, and standard STEMI treatment.

Coronary bifurcation lesions are one of the most technically challenging subgroups of interventional cardiology, particularly in the context of acute coronary syndrome (ACS). In the STEMI setting, a culprit lesion usually contains ruptured plaque and dense thrombus; this can lead to a different appearance of the angiographic stenosis degree and dynamic changes in anatomy during the procedure.

The 2018 ESC/EACTS myocardial revascularization guidelines emphasize that the basic approach in bifurcation lesions is provisional stenting; however,

they state that preparation for a change in strategy should be made in acute coronary syndromes. The consensus documents of the European Bifurcation Club (EBC) also state that two-stent techniques should not be the initial strategy, but should be applied without delay if main branch flow loss, dissection, or significant residual stenosis develops during the procedure.

1. The Dynamic and Unpredictable Nature of Bifurcation PCI in STEMI

In the context of STEMI, thrombus load and inflammatory activation can increase plaque redistribution and carina shift. Acute worsening of the main branch after side branch stenting is associated with carina displacement, plaque shift or dissection. In the study by Song et al., it was shown that side branch occlusion after main branch stenting can negatively affect clinical outcomes; it was stated that the main mechanism for this is mostly plaque redistribution. When the same mechanism is considered in the opposite direction, it explains the worsening of the main branch after side branch intervention. Intravascular imaging studies have shown that angiographic evaluation in bifurcation lesions often does not reflect the true plaque burden. Therefore, an anatomy that initially appears as “Medina 0,0,1” in the context of STEMI may functionally transform into a bifurcated lesion after intervention.

2. Invert Provisional Strategy in Medina 0,0,1 Lesions

Medina 0,0,1 morphology describes lesions that only include the side branch ostium. In elective cases, a single-stent strategy is usually sufficient, and routine use of two-stent techniques is not recommended. The BBC ONE study showed that complex two-stent strategies were associated with more periprocedural myocardial infarction and complications compared to the simple provisional approach. Similarly, the CACTUS study reported that the routine two-stent approach did not provide clinical superiority. In light of these data, the initial choice of the invert provisional approach is consistent with guidelines and randomized trial results. However, in the context of acute STEMI, the strategy may need to be evolved during the procedure due to the thrombotic and unstable plaque structure. In this case, significant worsening of the LAD ostium developed after side branch stenting, and the need for a two-stent technique arose.

3. The Enlargement of the Main Branch and Transition to Two-Stent Techniques

Severe deterioration of the main branch after side branch stenting is explained by four main mechanisms:

- Karina shift
- Record redistribution
- Stent protrusion
- Dissection

This pathophysiology is particularly pronounced in STEMI patients with high thrombus burden. EBC consensus documents emphasize that switching to

two-stent techniques should not be delayed when residual stenosis or flow impairment of more than 70% develops in the main branch.

Among two stent techniques in complex bifurcations, DK-crush and culotte stand out. In the DKCRUSH-III study, it was shown that the DK-crush technique provided lower target lesion revascularization compared to the classic culotte. The DKCRUSH-V study, on the other hand, demonstrated the superiority of DK-crush over the provisional strategy in distal left main bifurcations.

However, most of these studies cover the real (Medina 1,1,1) and especially the left major bifurcations. In non-left major, symmetric LAD-D1 bifurcations, the culotte technique provides the advantage of homogeneous metal distribution and ostial coverage.

The DK-culotte modification incorporates a two-stage kissing balloon application in addition to the classic culotte technique and optimizes stent apposition. In two-stent strategies, the application of final kissing and proximal optimization technique (POT) is critical for long-term results.

In this case:

- The side branch was already stented.
- The main rupture had significantly worsened during the procedure.
- The vessel diameters were symmetrical.
- Therefore, the DK-culotte was chosen as an anatomically and technically rational rescue strategy.

4. Clinical and Strategic Implications

This phenomenon conveys three important messages:

- 1-In the context of STEMI, Medina 0,0,1 lesions are not static; they can transform into a two-branched complex lesion during treatment.
- 2-Invert provisional is a suitable initial strategy, but the operator should be prepared for techniques with two stents.
- 3-In the presence of main branch flow loss or severe residual stenosis, the optimized two-stent technique should be applied without delay.
- 4-Therefore, in bifurcation PCI, an approach that “evolves according to anatomy” is safer and more rational than “one correct technique”.

Conclusion: In the context of acute anterolateral STEMI, Medina 0,0,1 LAD-D1 bifurcation lesions can initially be managed with a single-stent inverted provisional strategy. However, the possibility of major branch deterioration due to thrombotic and unstable plaque formation should be considered. In this case, optimized dual-stent techniques such as the DK-culotte offer an effective solution in terms of both angiographic and clinical success. This case highlights the importance of a “flexible and anatomically evolving strategy” approach rather than a “single correct strategy” in bifurcation PCI.

Keywords: STEMI, bifurcation lesion, Medina 001, invert provisional, DK-culotte, diagonal branch

[OP-59]**VR Eleve MI Developing After Bentall Operation**Göktuğ Uğurluoğlu¹, Said İsmailler²¹Akçakoca State Hospital, Düzce²Düzce State Hospital, Düzce

Aim: Bentall surgery is a complex open-heart surgery in which aortic aneurysm, aortic valve diseases, and sometimes coronary artery bypass grafting (CABG) procedures are treated simultaneously, removing the damaged aortic root and valve and replacing them with an artificial graft. Approximately 18% of all percutaneous coronary interventions (PCIs) are performed in patients who have previously undergone CABG surgery, and approximately 6% of all PCIs are performed on saphenous vein grafts; this shows that the need for revascularization after CABG is common. There are various difficulties in selective imaging and treatment of bypass grafts. In this case report, we wanted to demonstrate the difficulties experienced in the visualization and treatment of occlusion seen from bypass grafts in the early period after Bentall surgery.

Case Report: A 48-year-old female patient who came to the emergency department with chest pain was consulted to us after elevation in the augmented voltage right lead and widespread depression in the other leads were observed in the ECG. The patient's history shows that he underwent emergency surgery with an ascending aortic aneurysm 2 months ago. In the operation, it was seen that ascending aorta replacement, aortic valve replacement, and 3 vessel bypass grafts were performed. Hemoglobin and international normalized ratio (INR) values were quickly checked. The patient had a high INR and underwent imaging from the left radial artery. Many catheters (IMA, AR, left 3.5 JL, right 3.5-4JR) were tried, but the grafts could not be selectively fitted. Thereupon, non-selective images were taken with a pressurized auto-injector device through pigtail. In the right graft, 80% lesions were seen in the ostium, and in the left graft, 98% lesions were seen in the anastomosis line. As the procedure was prolonged and the patient's pain decreased, the patient was taken to the cardiovascular surgery and cardiology council for emergency surgery. It was decided to be transferred to the center operated in the council. The operated center did not accept the patient because it was a very high-risk procedure and recommended angiography again. When no results were obtained in other consulted centers, the patient underwent femoral increasing intervention. The left graft was seated from the femoral artery with a 3.5 JR catheter. The lesion was passed with a floppy wire and a double floppy wire was used for support. 2.0*20 percutaneous transluminal coronary angioplasty was performed on 98% lesions. Then, the 3.0*23 DES process was successfully applied.

Conclusion: Saphenous vein graft occlusion is common in patients who have undergone CABG surgery. Difficulties encountered while imaging saphenous grafts cause increased radiation exposure of the operator, increased opaque material exposure of the patient and prolongation of the procedure. In this case, despite anatomical difficulties, saphenous vein graft occlusion was successfully treated with percutaneous intervention using different intervention sites and catheters.

Keywords: Bentall operation, Aortic elevation, AVR, CABG

[SS-62]**Successful Revascularization and Complication Management in a Patient with Very Difficult Chronic Total Occlusion**Abdullah Özçelik¹, Ahmet Seyfeddin Gürbüz²¹Mardin Training and Research Hospital, Mardin²Necmettin Erbakan University, Meram Faculty of Medicine Hospital, Konya

Aim: Chronic total occlusion (CTO) is defined as complete occlusion of the coronary artery lumen for more than 3 months, with thrombolysis in myocardial infarction 0 flow distal to the occlusion. Successful CTO percutaneous coronary intervention (PCI) improves patients' angina symptoms, restores exercise capacity, increases left ventricular ejection fraction, and reduces the need for coronary artery bypass surgery (CABG). CTO PCI procedures are more complex and difficult than routine PCI procedures. The risk of developing complications is higher in these complex and difficult procedures compared to routine PCI procedures. Complications of CTO PCI procedures include coronary artery perforation, cardiac tamponade, stent, clot and air embolization, acute vascular occlusion, coronary artery dissection, coronary no-reflow, insertion site and bleeding complications (hematoma, dissection, retroperitoneal bleeding, etc.), and contrast nephropathy. Preventing, diagnosing, and treating these complications early is of great importance.

Case Report: Serious complications such as death, stroke, myocardial infarction, and emergency heart surgery occur in 2 out of every 1000 patients (0.2%) with conventional stent procedures, while they occur in 20 out of every 1000 patients (2%) with CTO procedures. Because the CTO procedure takes a relatively longer time, radiation damage, contrast-induced kidney damage, and coronary artery perforation are more common compared to conventional stenting. Our CTO patient was a 60-year-old male with diabetes mellitus, hypertension, and coronary artery disease. The patient had a normal ejection fraction and exertional angina. The patient had previously undergone one unsuccessful left anterior descending artery (LAD) CTO attempt (Figures 1 and 2). The J-CTO score was 3. A Corsair-pro microcatheter, double-lumen Recross microcatheter, Gaia Second, Gaia Third, and Gladius EX 14 CTO wires were used. An antegrade approach with a parallel wire technique was used to descend into the lumen. Full patency was achieved by stenting the LAD and its diagonal branch using a double kissing (DK) crush technique. Upon observing a dissection image at the stent level, it was evaluated as a bridge collateral dissection (Figure 3), and a graft stent was implanted in that area (Figure 4). During intensive care unit monitoring, pericardial effusion and cardiac tamponade developed. Emergency pericardiocentesis was performed. On the 3rd day of ward monitoring, pericardial effusion was observed again, prompting a control coronary angiography. No dissection image was seen. In a patient whose pericardial effusion worsened during follow-up and who developed cardiac tamponade, pericardiocentesis was unsuccessful, so the pericardial fluid was surgically drained through a minimally invasive subcostal incision as an emergency procedure. The pericardial effusion did not recur during follow-up. The patient was discharged on the 7th day.

Conclusion: In conclusion, the very challenging LAD CTO lesion was successfully treated using the parallel wire technique, and the bifurcation lesions were stented using the DK crush technique. Complications were detected early and treated successfully. The patient was discharged without complications. There were no issues at the 1st and 3rd month follow-ups. The patient's exertional angina had completely resolved.

Keywords: CTO, antegrade, parallel wire, bifurcation, dissection, tamponade

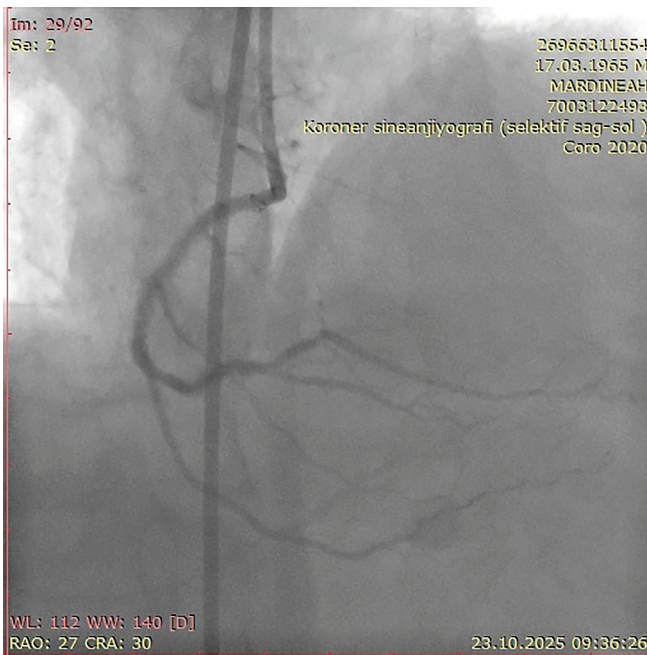


Figure 1. Right system baseline image
RAO: Right anterior oblique, CRA: Cranial

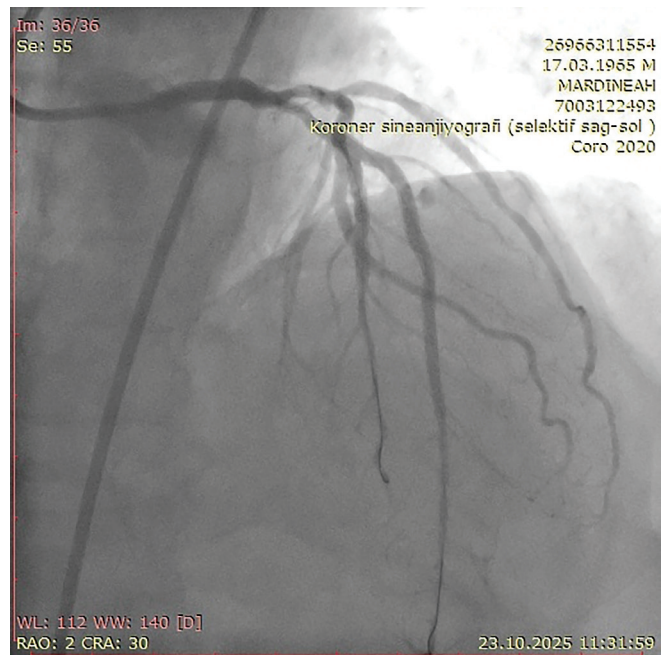


Figure 3. Bridge collateral dissection
RAO: Right anterior oblique, CRA: Cranial

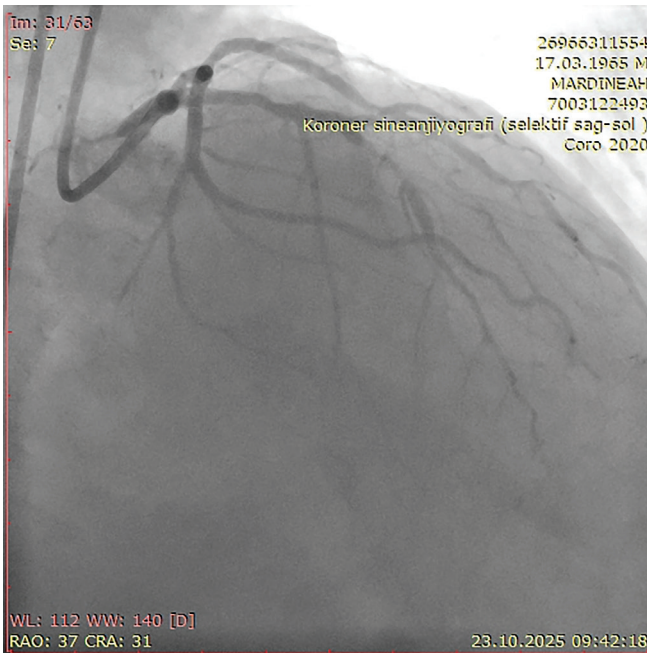


Figure 2. Left system baseline image
RAO: Right anterior oblique, CRA: Cranial

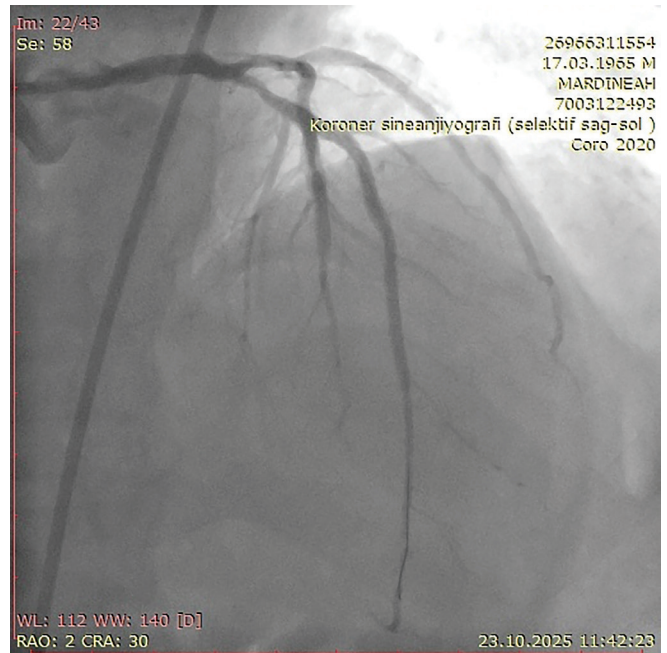


Figure 4. Final angiography image
RAO: Right anterior oblique, CRA: Cranial

[OP-63]**A River That Cannot Flow: Antegrade PCI of a Tortuous RCA CTO**

İlker Gül, Ecem Gürses, Oktay Şenöz, İlhan Koyuncu, Ahmet Anıl Başkurt, Yusuf Demir

Department of Cardiology, Bakırçay University Çiğli Training and Research Hospital, İzmir

Aim: Chronic total occlusion (CTO) of the right coronary artery (RCA) presents significant challenges, particularly in tortuous vessels with microchannels. Careful procedural planning, appropriate device selection, and intraprocedural support strategies are essential for procedural success. In patients with reversible ischemia, CTO revascularization can improve myocardial perfusion and clinical outcomes.

Case Report: A female patient was admitted with a diagnosis of non-ST elevation myocardial infarction. Percutaneous coronary intervention (PCI) was successfully performed in the proximal left anterior descending artery. Evaluation of the RCA CTO was planned based on myocardial perfusion imaging (MPI). One month later, MPI revealed reversible ischemia in the inferior territory, with an ischemic burden of 18%. After discussing procedural risks with the patient and her relatives, RCA CTO PCI was scheduled. The patient was on acetylsalicylic acid and clopidogrel; therefore, no loading doses were administered. An AL-I guiding catheter was engaged at the RCA ostium. Intracoronary administration of 5000 IU unfractionated heparin was performed. Using microcatheter support, a Fielder XT-R guidewire was advanced through microchannels and successfully crossed the CTO lesions. Two distinct CTO segments—proximal and distal—were identified. Intraluminal position in the distal vessel was confirmed with contrast injection via the microcatheter. Sequential percutaneous transluminal coronary angioplasty was performed using 1.2×20 mm, 2.0×20 mm, and 2.5×25 mm non-compliant balloons. Drug-eluting stents (3.0×38 mm and 3.5×23 mm) were deployed from the distal segment up to the RCA ostium, followed by post-dilatation with a 3.5×20 mm non-compliant balloon. Final angiography demonstrated TIMI III flow without complications.

Conclusion: This case illustrates that in the presence of reversible ischemia, CTO revascularization is a reasonable and effective strategy. Tortuous CTOs with microchannels can be successfully navigated using a Fielder XT-R wire with adequate microcatheter and guiding catheter support. Minimal calcification contributed to procedural success. Careful preprocedural planning, optimal device selection, and intraprocedural support are critical factors in achieving successful CTO PCI outcomes.

Keywords: Coronary tortuosity, chronic total occlusion, antegrade revascularization

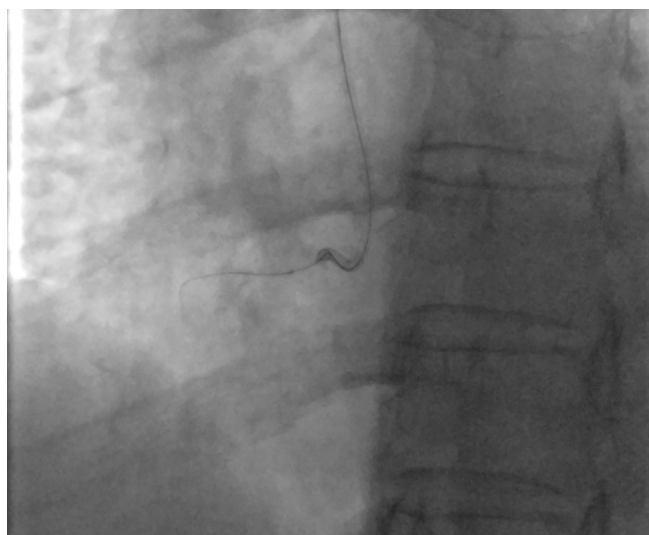


Figure 1.

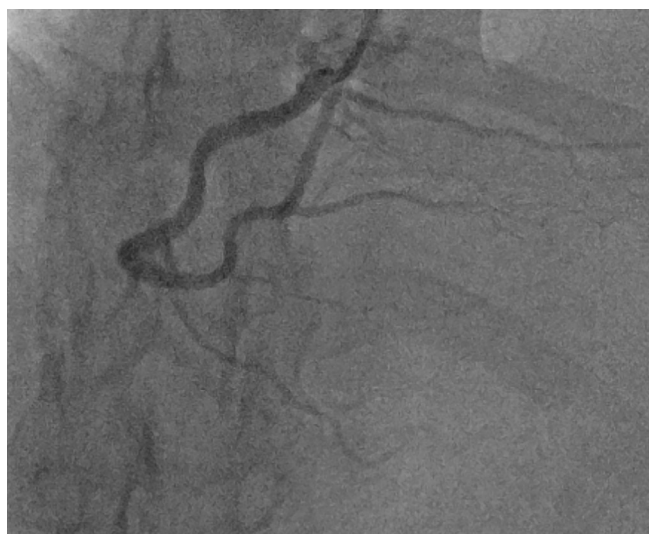

Figure 2.

[OP-64]**Case Report: Retrograde LAD Osteal CTO Intervention and Saphenous Vein Graft “Silencing” Post-CABG**

Rıdvan Yurt¹, Iskan Zengin¹, Eralan Abibulaev², Ramazan Ozan³, Cuma Süleymanoğlu⁴, Bilal Alcalı⁵

¹University of Health Sciences Türkiye, Kayseri City Hospital, Kayseri

²Memorial Kayseri Hospital, Kayseri

³Ağrı Training and Research Hospital, Ağrı

⁴University of Health Sciences Türkiye, Osmaniye Training and Research Hospital, Osmaniye

⁵Kahramanmaraş State Hospital, Kahramanmaraş

Aim: This case report details a complex percutaneous coronary intervention in a young male patient who presented with persistent exertional angina two months after coronary artery bypass grafting (CABG). Due to a suboptimally placed Saphenous Vein Graft (SVG) and a chronic total occlusion (CTO) of the left anterior descending (LAD), a retrograde approach via the SVG was employed to restore native flow, followed by the strategic ‘silencing’ of the competitive graft.

Case Report: A young male patient with a history of LAD osteal 100% CTO, circumflex artery plaque, and 70% mid-right coronary artery (RCA) stenosis underwent CABG. Post-operatively, the patient reported persistent symptoms. Despite intensifying medical therapy with Ranolazine 500 mg bis in die and Isosorbide Mononitrate, the patient’s exertional angina remained. A follow-up coronary angiography was performed, revealing a normal left main coronary artery (LMCA), 100% LAD osteal CTO, and a patent SVG-to-RCA PD graft. However, the SVG-to-LAD anastomosis was found to be connected to a

diseased segment (70% stenosis) of the LAD, leaving several proximal diagonal and septal arteries ischemic. Procedural Description: 1) RCA intervention: Using a 7F JR4 guiding catheter, a 3.0x32 mm Boston stent was implanted into the RCA. Proximal optimization (POT) was performed with a 3.5x15 mm NC balloon, achieving TIMI 3 flow. 2) Retrograde LAD CTO intervention: Given the anatomy—specifically the anastomosis site and the presence of five side branches (2 diagonal, 3 septal) above it—a retrograde LAD osteal CTO procedure was initiated via the SVG. A 7F EBU 3.5 catheter engaged the LMCA, and a 7F JR4 engaged the SVG-to-LAD. A Finecross microcatheter was advanced through the SVG to the distal segment of the LAD CTO. The distal cap was penetrated with a Gaia Second wire. To ensure true-to-true lumen re-entry, an Ultimatebros 3 wire was used for drilling into the distal LMCA. Re-entry was facilitated using a GuideLiner in the LMCA. Although a “tip-in” was attempted with an antegrade Finecross, the microcatheter could not cross the LAD ostium. Consequently, the wire was trapped in the EBU using a 2.0x20 mm balloon, and the retrograde microcatheter was advanced into the EBU. Externalization was successfully completed with an RG3 wire. 3) Revascularization and graft management: Following antegrade predilatations (1.0x12 mm and 2.0x20 mm), a 3.0x32 mm Boston stent was implanted from the LAD ostium to the LMCA (crossover technique). POT was performed with a 3.5x15 mm NC balloon in the LAD and a 4.5x8 mm NC balloon in the LMCA (at 22 ATM). Post-stenting, TIMI 2 flow was observed, but competitive flow from the SVG was noted. To optimize native flow and eliminate competition, the SVG was ‘silenced’. After predilatation with a 2.0x20 mm balloon, a 2.5x21 mm Begraft (covered stent) was implanted at the anastomosis. High-pressure post-dilatation followed with a 2.5x15 mm NC balloon. The procedure concluded with TIMI 3 flow in the native LAD and its branches.

Conclusion: This case highlights the efficacy of the retrograde CTO technique via bypass grafts to restore native circulation in complex post-CABG patients. Strategic ‘silencing’ of competitive grafts using covered stents can be essential to ensure optimal perfusion of side branches and long-term patency of the native vessel.

[OP-66]**Successful Native IMA PCI via a Totally Occluded Aorta-Saphenous-IMA Graft**

Oğuz Kılıç, Serdal Bay

Karaman Training and Research Hospital, Karaman

Aim: A 64-year-old male patient with a history of triple coronary artery bypass grafting (CABG ×3) performed in 2012 had subsequently undergone three post-CABG coronary angiographies. In 2022, he underwent two percutaneous coronary interventions (PCI) targeting the aorta-saphenous vein-internal mammary artery (IMA) graft.

Case Report: The patient was re-admitted with complaints of exertional angina (canadian cardiovascular society class III) and exertional dyspnea. Diagnostic evaluation revealed a reduction in left ventricular ejection fraction. Consequently, diagnostic coronary angiography was performed, demonstrating total occlusion of the aorta-saphenous vein-IMA graft, with the IMA being retrogradely filled via the right coronary artery. Myocardial perfusion scintigraphy was subsequently performed, revealing 28% ischemia. Based on these findings, a chronic total occlusion PCI of the IMA was planned. During the procedure, retrograde subintimal tracking was achieved in the native IMA via the totally occluded aorta-saphenous vein-IMA graft using a Corsair Pro XS microcatheter for support, along with Gladius EX guidewire, Gaia Third guidewire, and Conquest Pro 12 guidewire. However, entry into the true lumen could not be achieved.

Conclusion: Subsequently, an antegrade approach was initiated using Corsair Pro XS microcatheter support, and the Gladius EX guidewire was advanced. A reverse controlled antegrade and retrograde tracking (reverse CART) technique was performed. After repeated attempts, the antegrade guidewire successfully entered the distal true lumen. Following re-wiring, the procedure was completed via the antegrade approach, resulting in successful recanalization with full restoration of vessel patency.

Keywords: CTO, IMA, POST-CABG

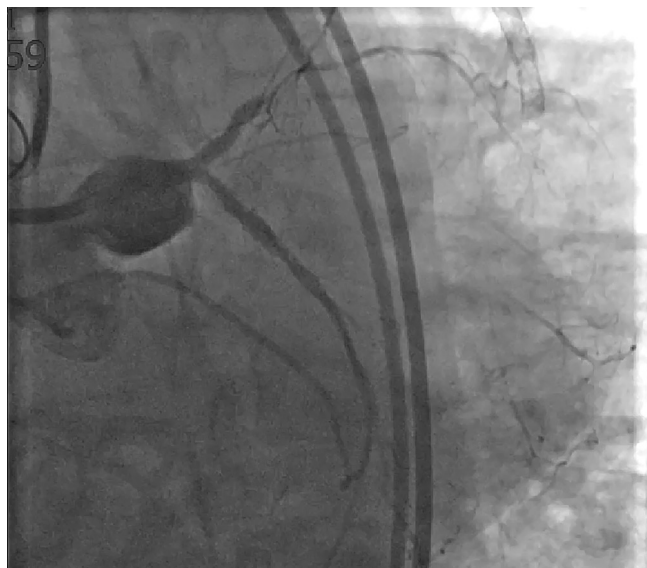

Figure 2.

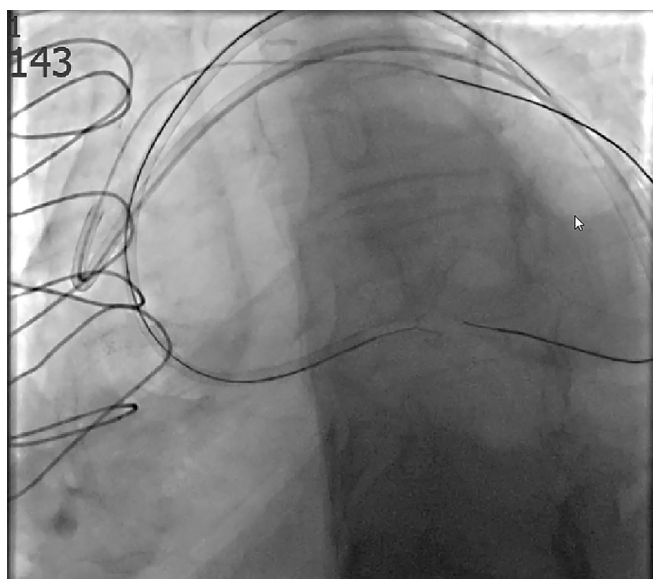


Figure 1.

[OP-67]**Retro-in-Retro: Sequential Retrograde Recanalization of an Occluded Diagonal Enabling Distal LAD CTO PCI**Haşim Tüner¹, Fatih Kahraman², Ömer Göktekin³¹Department of Cardiology, İstanbul Arel University Memorial Bahçelievler Hospital, İstanbul²Department of Cardiology, Kütahya Health Sciences University Training and Research Hospital, Kütahya³Memorial Bahçelievler Hospital, İstanbul

Aim: Percutaneous coronary intervention (PCI) of chronic total occlusions (CTO) remains one of the most technically demanding procedures in interventional cardiology, particularly in the presence of long calcified lesions and poor distal vessel quality. When antegrade strategies fail, retrograde techniques through collateral circulation may provide an effective alternative approach. Sequential retrograde strategies utilizing intermediate branches may offer additional solutions in highly complex CTO anatomies.

Case Report: A 49-year-old male with a history of renal transplantation presented with exertional angina despite optimal medical therapy. His medical history was also notable for diabetes mellitus, hypertension, and chronic immunosuppressive therapy. Coronary angiography demonstrated multivessel coronary artery disease including previously treated heavily calcified left circumflex artery disease with patent stents, distal right coronary artery disease, and a long, heavily calcified proximal left anterior descending artery (LAD) CTO with poor distal vessel quality (Figure 1). Initial antegrade

attempts to cross the LAD CTO using multiple guidewires were unsuccessful due to the length of the occlusion, severe calcification, and suboptimal distal vessel visualization. Therefore, a retrograde strategy was pursued. Epicardial collateral channels originating from the LCx coronary artery were used to access an occluded diagonal branch using a microcatheter and guidewire system (Figure 2). The diagonal branch was successfully crossed retrogradely and externalization was achieved using an RG3 guidewire. Balloon angioplasty with a non-compliant balloon was then performed to restore antegrade flow within the diagonal branch. Following successful recanalization of the diagonal branch, the same pathway enabled a second retrograde wire passage from the diagonal branch into the distal LAD, representing a sequential “Retro-in-Retro” crossing (Figure 2). Reverse CART technique was subsequently performed to establish connection between the retrograde and antegrade systems. Intravascular ultrasound was used to evaluate lesion morphology and guide procedural optimization. The lesion was prepared using non-compliant balloons followed by implantation of a 3.5 × 38 mm drug-eluting stent. Additional high-pressure post-dilatation was performed to optimize stent expansion. Adjunctive lesion modification with cutting balloon angioplasty and drug-coated balloon therapy was applied to further optimize the final angiographic result. Final angiography demonstrated successful recanalization of the LAD CTO with restoration of TIMI 3 flow and no significant residual stenosis (Figure 1).

Conclusion: The “Retro-in-Retro” strategy, involving sequential retrograde recanalization of an occluded diagonal branch followed by distal LAD CTO crossing, may represent a novel and effective bailout technique in highly complex CTO anatomies. In selected cases where antegrade crossing fails and distal vessel quality is limited, this approach may broaden the spectrum of retrograde CTO strategies and facilitate successful revascularization.

Keywords: CTO, retrograde, epicardial, diagonal, recanalization, reverse CART

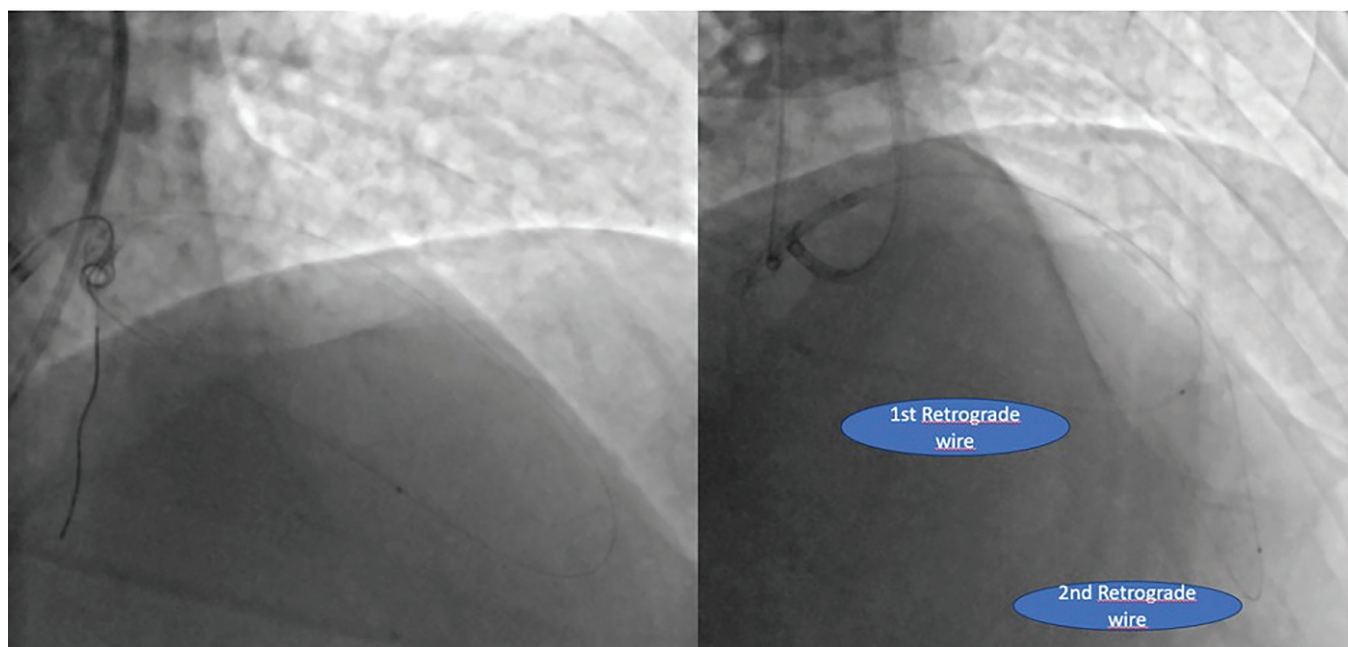


Figure 1. Both LCx to diagonal and diagonal to left anterior descending artery epicardial collaterals crossing

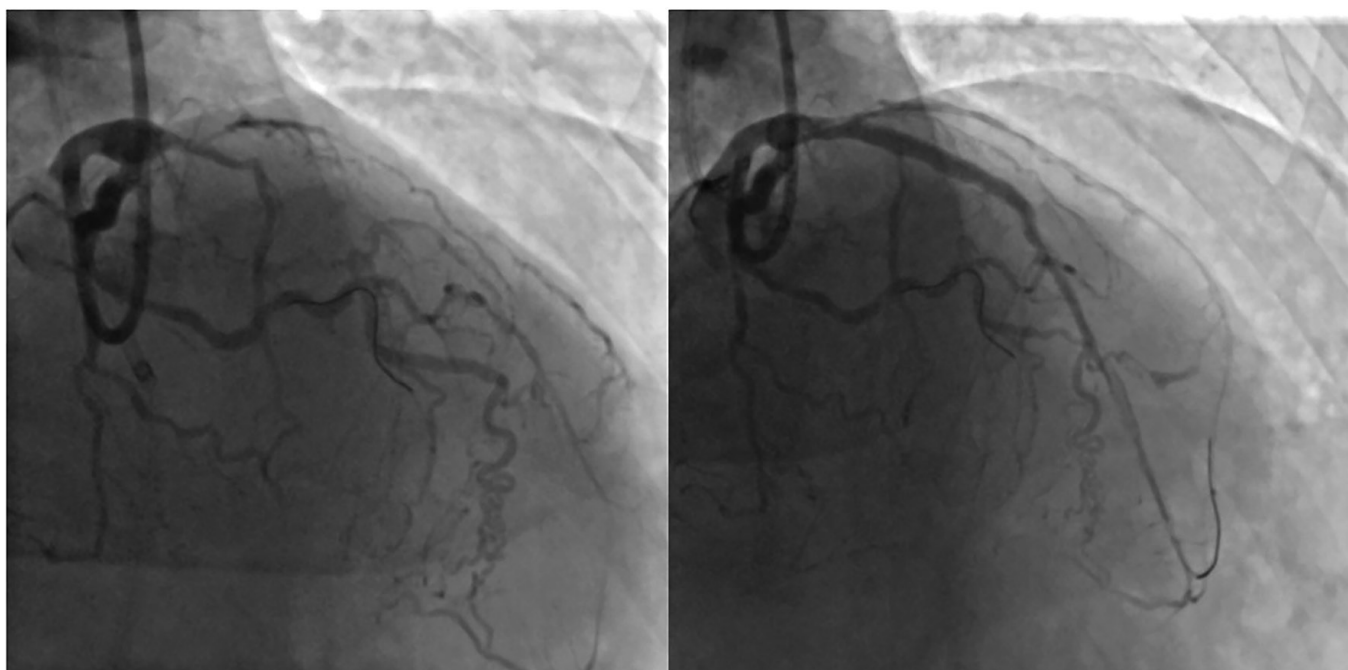

Figure 2. Baseline and final result

[OP-68]

Retrograde Septal Approach With Snare Externalization in Ostial LAD CTO

Mustafa Tunahan Öz, Adnan Kaya

Department of Cardiology, Bahçeşehir University Faculty of Medicine, İstanbul

Aim: Chronic total occlusion (CTO) of the ostial left anterior descending artery (LAD) represents one of the most technically demanding coronary interventions due to the absence of a proximal landing zone and the risk of aortic dissection. Retrograde techniques via septal collaterals can facilitate safe wire crossing when antegrade strategies are challenging.

Case Report: A 57-year-old male presented with reduced exercise capacity. Coronary CT angiography performed for evaluation of exertional symptoms demonstrated suspected critical stenosis in the LAD. The patient had a history of active smoking and alcohol use but no diabetes mellitus or hypertension. Diagnostic coronary angiography confirmed an ostial LAD CTO. The patient was scheduled for elective CTO percutaneous coronary intervention one week later. Dual radial access was obtained. A guiding catheter was positioned in the left main artery via the left radial approach, while the circumflex artery (Cx) was engaged via the right radial approach to facilitate retrograde access. A septal collateral channel from the Cx to the LAD was crossed successfully. Using a Gaia 2 guidewire, the LAD ostial CTO was crossed retrogradely and advanced into the ascending aorta. The wire was then captured using a snare in the aorta, allowing externalization and conversion of the system to an antegrade configuration. Following wire externalization, the CTO segment was successfully recanalized and treated with standard PCI techniques.

Conclusion: This case highlights the effectiveness of a septal retrograde approach combined with snare-assisted wire externalization in the treatment of complex ostial LAD CTO lesions, providing a safe and effective strategy when antegrade crossing is not feasible.

Keywords: CTO, ostial left anterior descending artery, retrograde PCI

[OP-70]

Difficult Lesions in the Endovascular Treatment

Uğur Cetingök

University of Health Sciences Türkiye, Ankara Etlik City Hospital, Ankara

Aim: Endovascular interventions are a standard treatment approach for patients suffering chronic limb threatening ischemia. This approach however can be complicated in some cases owing to difficult anatomy of the lesion that hinders successful crossing and recanalization of the diseased artery. In this study, we discussed the definition of difficult lesions in arterial diseases and the techniques and devices that increase success in endovascular treatment.

Methods: Between 2023 and 2025, 212 symptomatic patients (185 male, mean age 67 years) with peripheral arterial disease was performed percutaneous endovascular treatment. Patients were classified, according to guidewire crossing difficulty into four categories (easy, moderate, hard and failed). The crossing difficulty was correlated with the Trans-Atlantic Inter-Society Consensus Document (TASC II) classification.

Results: Technical success, defined as perceived antegrade true lumen or subintimal crossing, was achieved in 96.7%. 92 of cases were deemed easy, 71 moderate, 42 hard and 7 were failed attempts. The success rate for difficult lesions was 85.7%. Factors affecting success were the location of the lesion, the type of lesion, and the length of the lesion. The factors that increase the success of the procedure in difficult lesions are the selection of the appropriate access site, the use of appropriate guidewires, and the use of re-entry devices.

Conclusion: Successful endovascular revascularisation strongly depends on efficient lesion crossing for which a large variety of guidewires, a variety of catheters or balloons is available. In addition, the selection of the access site, lesion crossing techniques and experience are important factors that increase success in difficult lesions.

Keywords: Difficult lesions, endovascular treatment, peripheral vascular disease

[OP-71]**Endovascular Salvage Following Failed Surgical Thrombectomy: Successful Percutaneous Transluminal Angioplasty in a Case of Acute Limb Ischemia**

Izzatilla Abdulazizov, Orhan Ulaş, Şaban Keleşoğlu

Department of Cardiology, Erciyes University Faculty of Medicine, Kayseri

Aim: Acute limb ischemia is a serious clinical condition characterized by a sudden decrease in limb perfusion due to arterial occlusion and may result in limb loss and increased mortality if treatment is delayed. Although surgical thrombectomy has traditionally been considered the standard treatment approach for embolic acute limb ischemia, inadequate revascularization may occur in the presence of underlying atherosclerotic lesions or subacute thrombotic occlusions. In this report, we aimed to present the clinical outcome achieved with successful percutaneous transluminal angioplasty (PTA) in a patient with acute limb ischemia in whom adequate revascularization could not be achieved despite surgical thrombectomy.

Case Report: A 78-year-old male patient presented to an outside medical center with severe left leg pain lasting approximately 18 hours. Doppler ultrasonography and computed tomography angiography demonstrated absence of flow beginning at the level of the superficial femoral artery (SFA) in the left lower extremity, with findings suggestive of arterial occlusion. The patient subsequently underwent surgical thrombectomy. However, due to failure to achieve adequate distal flow and lack of clinical improvement following the procedure, the patient was referred to our center for advanced endovascular treatment. On admission to our institution, pulses of the popliteal artery, posterior tibial artery, and dorsalis pedis artery in the left lower extremity were absent. Marked pallor and coldness of the affected extremity were also noted. According to the Rutherford classification, the clinical presentation was consistent with class II acute limb ischemia. Digital subtraction angiography of the left lower extremity was performed via right femoral artery access. Angiography revealed a long-segment total occlusion extending from the proximal segment of the left iliac artery to the popliteal artery segment (Figure 1). The lesion was classified as TASC II type D. After unsuccessful antegrade crossing attempts, retrograde access was obtained through the left SFA, and the lesion was successfully crossed retrogradely using a guidewire (Figure 2). Following wire externalization with the assistance of a microcatheter, advancement through the lesion was achieved over the guidewire. Subsequently, percutaneous transluminal angioplasty was performed sequentially from the popliteal artery segment using 5.0×120 mm, 5.0×150 mm, and 6.0×150 mm balloons. An 8.0×27 mm stent was implanted at the ostial segment of the left iliac artery. Final angiography demonstrated successful restoration of distal flow (Figure 3). During follow-up, marked clinical improvement was observed, including warming of the extremity and improvement in skin color. The patient was discharged uneventfully after two days of inpatient monitoring.

Conclusion: Acute limb ischemia is a vascular emergency requiring prompt intervention and may lead to severe morbidity if treatment is delayed. In cases where surgical thrombectomy fails, endovascular treatment using a retrograde approach may serve as an effective salvage revascularization strategy.

Keywords: Acute limb ischemia, surgical thrombectomy, percutaneous transluminal angioplasty, endovascular treatment, peripheral artery disease

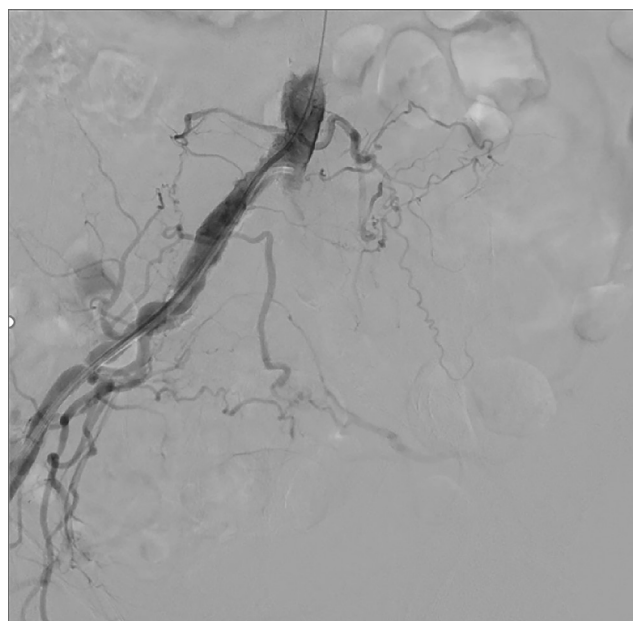


Figure 1. Angiographic image demonstrating total occlusion of the left iliac artery

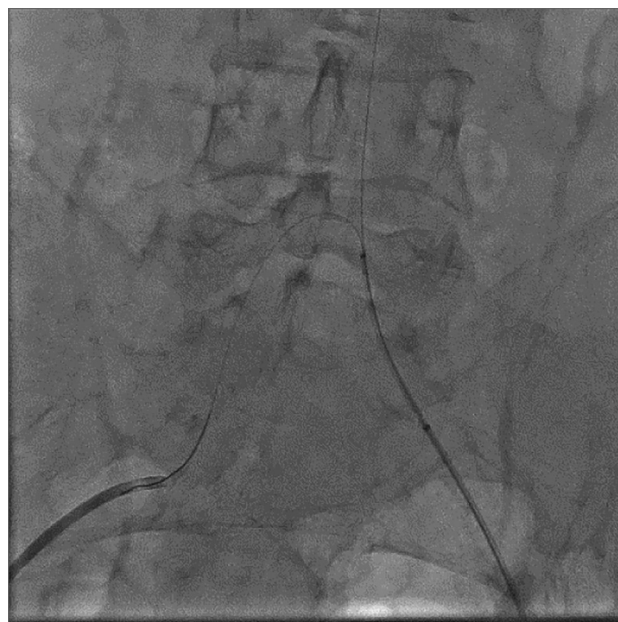


Figure 2. Successful retrograde guidewire crossing of the occluded segment through the left superficial femoral artery

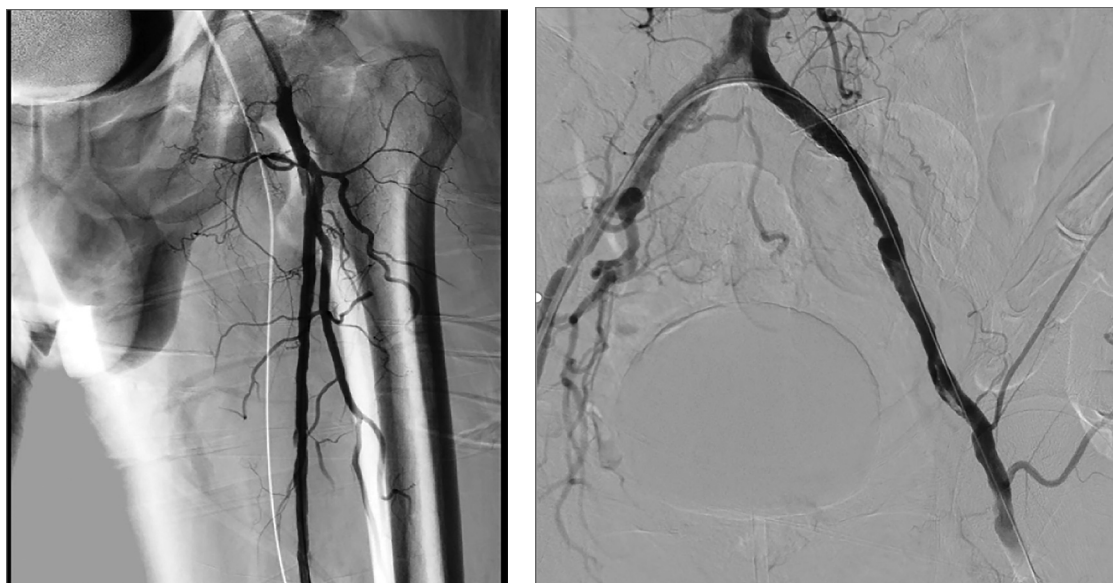

Figure 3. Final angiography showing successful endovascular revascularization with restoration of distal arterial flow to the left lower extremity

[OP-72]

Endovascular Treatment of Subclavian Artery Perforation Secondary to Gunshot Injury

Ahmet Can Çakmak¹, Betül Sarıbrıyık², Şevval Özdemir³

¹Clinic of Cardiology, Pamukova State Hospital, Sakarya

²Clinic of Cardiology, Yenikent State Hospital, Sakarya

³Clinic of Cardiology, Sakarya Training and Research Hospital, Sakarya

Aim: Subclavian artery injuries are rare among thoracic vascular traumas; however, they may lead to life-threatening complications. The majority of these injuries occur following penetrating trauma and frequently require emergent surgical intervention. Nevertheless, surgical management may be contraindicated in certain patients because of anatomical complexity, associated traumatic injuries, and hemodynamic instability. In recent years, endovascular approaches have increasingly been utilized as an alternative to surgery with favorable outcomes. Herein, we present a rare case of traumatic left subclavian artery perforation secondary to a gunshot injury that was successfully treated with percutaneous covered stent implantation in a patient deemed unsuitable for surgical repair.

Case Report: A 28-year-old female patient was urgently transferred to the catheterization laboratory because of traumatic left subclavian artery perforation following a gunshot injury. On clinical examination, brachial and radial pulses were absent. Due to concomitant thoracic injuries and hemodynamic instability, the patient was considered high risk for emergent surgical intervention. A 7F sheath was inserted via the left femoral artery. Selective cannulation of the left subclavian artery was performed using a 7F Judkins Right 4 (JR4) guiding catheter. Angiographic imaging demonstrated proximal total occlusion of the left subclavian artery with active contrast extravasation from the distal segment (Figure 1). The lesion was crossed using a 0.014-inch floppy guidewire. Subsequently, the catheter was advanced distally over the

wire, and true lumen position was confirmed angiographically (Figure 2). Predilatation was performed with a 5 x 120 mm balloon catheter (Figure 3), followed by successful implantation of a 7 x 59 mm covered stent (Figure 4). Final angiography demonstrated restoration of distal flow and complete sealing of the perforation without residual contrast leakage (Figure 5). The patient remained hemodynamically stable after the procedure and was transferred to the cardiovascular surgery department for further follow-up.

Discussion: Although subclavian artery injuries have traditionally been managed surgically, surgical exposure of the intrathoracic segment is technically demanding and associated with considerable morbidity and mortality. In the literature, endovascular treatment has emerged as a highly effective alternative with high technical success and low complication rates in traumatic subclavian artery injuries. In a series reported by Bergamin et al. (2020), covered stent implantation achieved technical success rates exceeding 90% in the treatment of subclavian artery injuries. Similarly, du Toit et al. (2008) demonstrated that endovascular management is a safe and effective option in patients unsuitable for surgery. In the present case, complete vascular integrity and distal reperfusion were successfully restored with percutaneous covered stent implantation in a patient who was not a suitable candidate for open surgical repair. The procedure was completed without complications. This case highlights that endovascular treatment may represent a rapid, effective, and minimally invasive alternative to surgery in traumatic subclavian artery perforations when favorable anatomical conditions are present.

Conclusion: Traumatic subclavian artery injuries are rare but potentially fatal vascular emergencies. In patients unsuitable for surgery, percutaneous covered stent implantation may provide rapid hemorrhage control and restoration of distal perfusion, representing an effective and safe therapeutic option. When performed in experienced centers, this approach may serve as a life-saving alternative in selected patients.

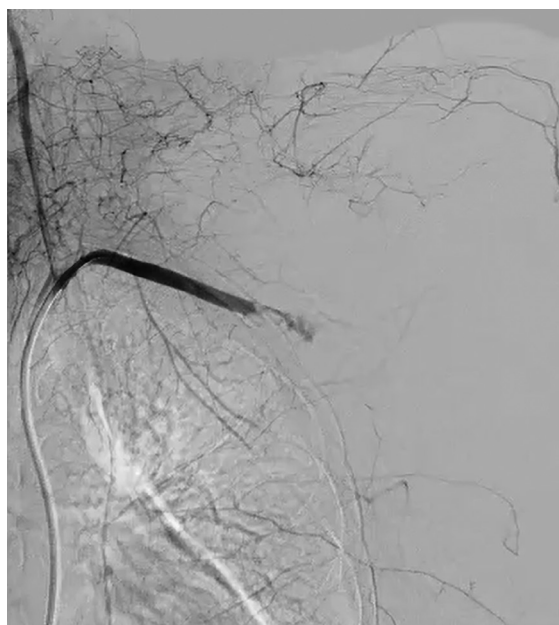


Figure 1. Proximal total occlusion of the left subclavian artery and active contrast extravasation in the distal segment

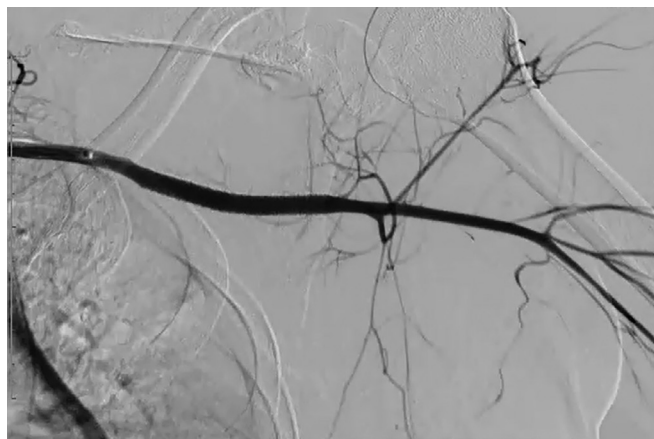


Figure 2. Post-procedural control angiography showing restored distal flow and closure of the perforation

[OP-73]

Retrograde Popliteal Approach for Successful Revascularization in Superficial Femoral Artery Occlusion with an Ambiguous Proximal Cap

İlker Gül, Ecem Gürses, Fuat Gündoğdu, Zeynep Emren, Oktay Şenöz

Department of Cardiology, İzmir Bakırçay University Çiğli Training and Research Hospital, İzmir

Aim: Chronic total occlusion (CTO) of the superficial femoral artery (SFA) can pose significant technical challenges, especially when the proximal stump is ambiguous or unclear. Retrograde popliteal access is a recognized alternative strategy for crossing difficult lesions and achieving successful revascularization in peripheral artery disease.

Case Report: A 58-year-old male patient with a history of diabetes mellitus and active smoking presented with severe claudication. He reported that

walking approximately 200 meters caused intense pain relieved by rest, which recurred with further ambulation. Doppler ultrasonography demonstrated monophasic flow in the left lower extremity. Computed tomography angiography revealed absence of flow in the left SFA, and the patient was scheduled for peripheral angiography with possible angioplasty. Initial angiography was performed via contralateral right femoral artery access; however, the proximal SFA stump was ambiguous and could not be crossed. Imaging demonstrated that the SFA and popliteal artery could be visualized distal to Hunter's canal. Based on these findings, a retrograde approach via the popliteal artery was planned. Under angiographic guidance, retrograde popliteal access was obtained. Using a 0.035-inch hydrophilic wire supported by a 4.0x60 mm balloon, the lesion was successfully traversed up to the main femoral artery. Confirmation of true lumen entry was performed via contrast injection through the balloon. Sequential percutaneous transluminal angioplasty (PTA) was performed using 4.0x60 mm and 6.0x150 mm balloons, each inflated for a minimum of 5 minutes to optimize vessel expansion. Post-procedural angiography demonstrated optimal luminal patency without evidence of dissection or rupture. The procedure was completed successfully, and the patient tolerated it without complications.

Conclusion: In patients with peripheral artery CTO and an ambiguous SFA proximal stump, retrograde popliteal access can provide a safe and effective route for revascularization. Careful stepwise technique, prolonged balloon inflation, and intraprocedural confirmation of true lumen entry are critical to procedural success. This approach allows restoration of blood flow in complex lesions that are otherwise inaccessible via antegrade access.

Keywords: Peripheral arterial disease, popliteal access, retrograd revascularization, percutaneous transcatheter angioplasty

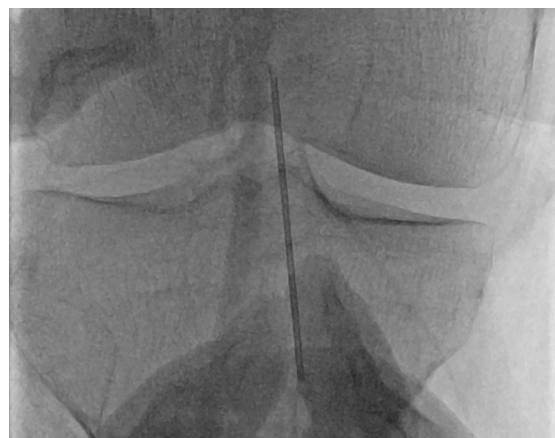

Figure 1.

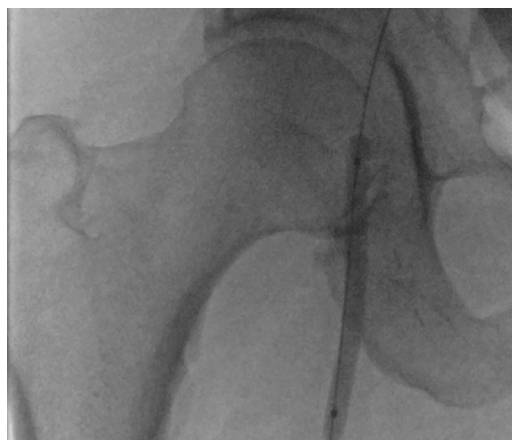

Figure 2.

[OP-74]**Endovascular Treatment of Right Brachiocephalic Artery Stenosis Using an Antegrade-retrograde Hybrid Approach with Cerebral Protection: A Case Report**

Mehmet Arslan, Emine Gazi, Esra Duman Acar

Department of Cardiology, Çanakkale Onsekiz Mart University Faculty of Medicine, Çanakkale

Aim: The brachiocephalic artery is a major aortic arch branch supplying the right common carotid and right subclavian arterial territories. Atherosclerotic stenosis in this segment may present with upper-extremity ischemic findings, an inter-arm blood pressure difference, reversed vertebral artery flow, and vertebrobasilar symptoms. In symptomatic proximal supra-aortic trunk lesions, endovascular therapy is used as a less invasive alternative to open surgery in suitable anatomy. However, because the lesion is close to the right carotid circulation, the risk of cerebral embolization is a key determinant of procedural strategy. The decision to intervene should be based not only on the degree of stenosis, but also on symptoms, hemodynamic significance, and cerebral/upper-extremity perfusion. Main indications include: vertebrobasilar insufficiency or subclavian steal phenomenon: dizziness, vertigo, syncope, diplopia, imbalance, and reversed flow in the ipsilateral vertebral artery. Upper-extremity ischemic findings: arm claudication, coldness, paresthesia, weak pulses, or a marked right-left arm blood pressure difference. Symptomatic high-grade stenosis, subtotal stenosis, or occlusion consistent with the clinical findings. A proximal supra-aortic trunk lesion associated with transient ischemic attack, stroke, or retinal ischemia. Risk of coronary-subclavian/innominate steal in patients with an existing or planned internal mammary artery graft. High-grade lesions showing progression with new symptoms or hemodynamic deterioration. In the present case, the indication for intervention was established by the coexistence of long-standing dizziness attacks, reversed flow in the right vertebral artery, parvus et tardus flow in the right common carotid artery, a marked inter-arm blood pressure difference, and critical/subtotal stenosis of the right brachiocephalic artery.

Case Report: A 56-year-old woman presented with chest pain, dizziness, and palpitations. On physical examination, blood pressure was 85/55 mmHg in the right arm and 145/60 mmHg in the left arm; right radial and brachial pulses were weak. Electrocardiography and echocardiography showed no significant abnormalities. Computed tomography aortography performed at an outside center showed no evidence of dissection. Coronary angiography, performed with a preliminary diagnosis of acute coronary syndrome, revealed no significant coronary artery disease. Doppler ultrasonography demonstrated parvus et tardus flow in the right common carotid artery and reversed flow

in the right vertebral artery. Upper-extremity/aortic arch imaging identified critical/subtotal stenosis at the level of the right brachiocephalic trunk. Endovascular intervention was planned because of the patient's long-standing dizziness, previously treated as vertigo, together with the hemodynamic findings.

A 6F Terumo sheath was inserted into the right radial artery and a 7F sheath into the right femoral artery. A 6F JR4 guiding catheter was advanced from the right radial artery to the right carotid level, and a 6F pigtail catheter was advanced from the femoral artery to the level of the right brachiocephalic trunk. First, a 6-mm Proender carotid protection filter was deployed in the right internal carotid artery via the radial route. The lesion was then crossed from the radial route with a second floppy wire into the aorta, followed by predilatation with 4.5x20 mm and 5.0x15 mm balloons. Subsequently, the lesion was crossed antegradely from the femoral route with a 0.035-inch hydrophilic wire; a 7F Terumo Destination catheter was positioned, and after 6x80 mm balloon dilatation, a 9x17 mm Medtronic Visipro stent was implanted. Final angiography demonstrated optimal patency, and the procedure was completed without complications. The patient was discharged after initiation of dual antiplatelet therapy. At the second month after the procedure, the right-left arm blood pressure difference had markedly decreased and dizziness attacks had resolved. This case demonstrates that brachiocephalic artery stenosis may present with non-specific symptoms and highlights the diagnostic value of an inter-arm blood pressure difference. Reversed flow in the right vertebral artery and parvus et tardus flow in the right common carotid artery supported the hemodynamic significance of the lesion. The primary aim of the procedural strategy was to reduce the risk of carotid embolization during the initial manipulation of the subtotal lesion. Therefore, a protection filter was first placed in the right internal carotid artery via the radial retrograde route; after predilatation, stenting was completed using the femoral antegrade approach. Distal balloon, double-filter, and retrograde filter techniques have been reported for cerebral protection during innominate artery interventions. Although current evidence is based mainly on retrospective series and case reports, endovascular treatment of symptomatic subclavian/innominate artery lesions has been reported to be feasible with high technical success. In this case, the filter-first hybrid approach contributed to an uncomplicated result by providing both cerebral protection and adequate stent support.

Conclusion: Right brachiocephalic artery stenosis is a rare but clinically important pathology that may present with dizziness and upper-extremity hypoperfusion. In critical/subtotal lesions, establishing carotid protection at the beginning of the procedure may reduce embolization risk. In this case, successful and uncomplicated revascularization was achieved with femoral antegrade stenting following radial retrograde filter placement.

Keywords: Brachiocephalic artery stenosis, innominate artery, subclavian steal syndrome, cerebral embolic protection, endovascular stenting

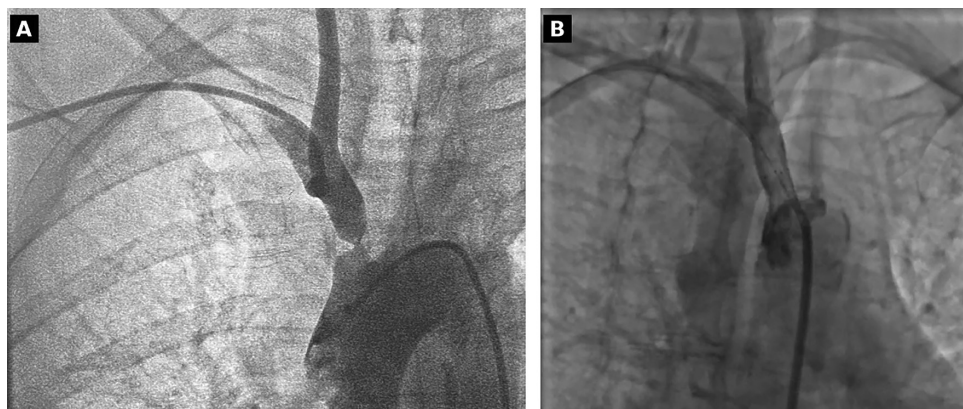


Figure 1. Angiographic images: (A) critical/subtotal stenosis of the right brachiocephalic artery; (B) optimal patency after stent implantation

[OP-75]**A case of Biomimics Self-expandable Stent Implantation for Superficial Femoral Artery Total Occlusion: 6th Month Result**

Yusuf Emre Gürel, Mustafa Kürşat Tigen

Department of Cardiology, Marmara University Faculty of Medicine, Istanbul

Fifty-eight year old female patient with a history of coronary artery disease and diabetes mellitus visited our outpatient clinic, complaining severe intermittent claudication in the right lower extremity. Physical examination showed no pulse on the right popliteal artery and below-the-knee arteries. Arterial Doppler ultrasonography (USG) revealed monophasic flows in the left posterior tibial (PTA) and anterior tibial arteries (ATA). Peripheral angiography demonstrated, total occlusion in the right superficial femoral artery (SFA) and collateral filling to the left PTA, ATA and peroneal arteries. Percutaneous intervention was planned. We accessed through left femoral artery with 6F sheath, and 6F sheathless catheter was advanced to the right SFA by crossover technique. Total occlusion in distal SFA was crossed anterogradely using 0.035 hydrophilic wire and peripheral microcatheter support and control angiogram revealed that wire is intraluminal at the level of popliteal artery. Repeated dilations were performed with 5.0x150 mm balloon. After that, control angiogram demonstrated flow-limiting dissection in distal SFA and 6.0x125 biomimics stent implantation was performed. She was discharged without any procedure-related complication next day. 3th month follow-up showed no symptom. However she described typical intermittent claudication again in 6th month follow up. Peripheral angiography showed in-stent restenosis in biomimics stent but not total occlusion and total occlusion in native vessel in mid and proximal part of the SFA. SFA was revascularized again using repeated balloon dilation and patient was discharged. Although MIMICS-2 trial and MIMICS-3D registry demonstrate that its unique, self-expanding nitinol design promotes swirling flow, reducing shear stress and improving patency in SFA interventions, further studies are needed to confirm this results.

Keywords: Chronic total occlusion, self-expandable stent, superficial femoral artery

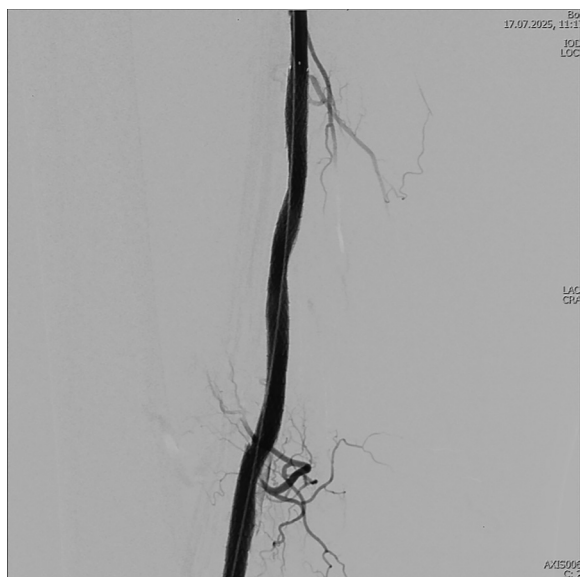

Figure 1.

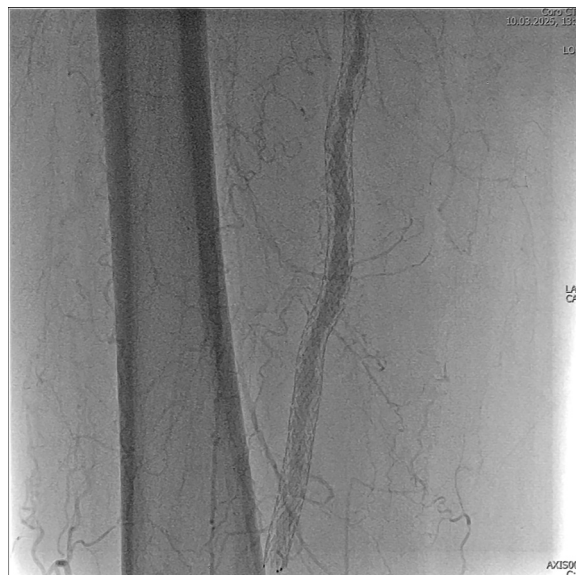


Figure 2.

[OP-77]**A Rare Case of Common Femoral Artery Aneurysm Treated Endovascularly**

Burcu Özyazgan, Fatih Yılmaz, Murat Esin

Clinic of Cardiology, University of Health Sciences Türkiye, Antalya City Hospital, Antalya

Aneurysms may develop anywhere in the body, with 4.6% of all cases occurring in peripheral arteries. A common femoral artery aneurysm is a rare pathology of the vascular system. The femoral artery is the second most common site for true peripheral artery aneurysms and the most common site for pseudoaneurysms. This article describes the endovascular treatment of a patient presenting with a right femoral artery aneurysm.

Keywords: Aneurysm, endovascular, peripheral artery disease

[OP-78]**Treatment of Massive Pulmonary Thrombosis After Recovery from COVID-19 Infection with the EkoSonic™ Endovascular System (EKOS®)**

Uğur Çetingök

University of Health Sciences Türkiye, Ankara Etlik City Hospital, Ankara

Aim: The disease, which is caused by the SARS-CoV-2 virus and called COVID-19 infection, at the end of 2019 rapidly spread around the world, causing the death of millions of people. Thrombosis incidence is high (31%) in patients requiring intensive care. Options for the current treatment of pulmonary embolism (PE); anticoagulation, fractionated heparin infusion or low molecular weight heparin (LMWH), thrombolytics, and catheter-directed thrombolysis. In this article, we discuss the unique multiple thrombosis events following recovery from COVID-19 infection and our treatment strategy for pulmonary thrombosis.

Methods: A 49-year-old male patient has palpitation, dyspnea, chest pain, anxiety, hypotension, hoarseness and coldness of the left hand. We learned from the patient's history he had fever, cough and myalgia symptoms and a positive polymerase chain reaction test for COVID-19 two months ago and was treated as an outpatient. But thrombosis of the superior mesenteric artery occurred one month after the COVID-19 infection and bowel resection

was performed. During his evaluation, sinus tachycardia (144 beats/min), hypotension (80/55 mmHg), and tachypnea (30/min) were detected. Oxygen saturation (SpO₂) was 86% room air. A CT scan revealed ground-glass opacities in the right upper lobe related to the previous COVID-19 pneumonia. CT pulmonary angiography (CTPA) showed a massive thrombus in the right pulmonary artery. The PE severity index score was calculated to be 149. The EkoSonic™ Endovascular System (EKOS) was used for the treatment of pulmonary thrombosis.

Results: Symptoms regressed rapidly within an hour. The arterial blood gas values improved (pO₂ 97 mmHg, pCO₂ 34 mmHg, pH 7.47) and SpO₂ was measured at 99%. Control CTPA was performed at the 12th hour of the EKOS treatment. The right pulmonary artery and anterior truncus were totally cleared. Thrombus fragments in the posterior ascending artery and the common basal arteries were observed. The treatment was continue for another 6 hours. Control pulmonary angiography was performed at the 18th hour of the EKOS treatment. The thrombi in the pulmonary artery and its branches had completely dissolved.

Conclusion: The standard treatment for PE is intravenous heparin or LMWH and followed by oral anticoagulants. The massive PE and submassive PE that causes RV failure can be treated with systemic thrombolytic treatment. Rapid evaluation of the patient by PERT and immediate treatment of PE according to its severity are very important in high-risk PE. Ultrasound accelerated thrombolysis is a safe and effective treatment in COVID-19-related pulmonary thrombosis.

Keywords: Catheter-directed thrombolysis, COVID-19 infection, EKOS

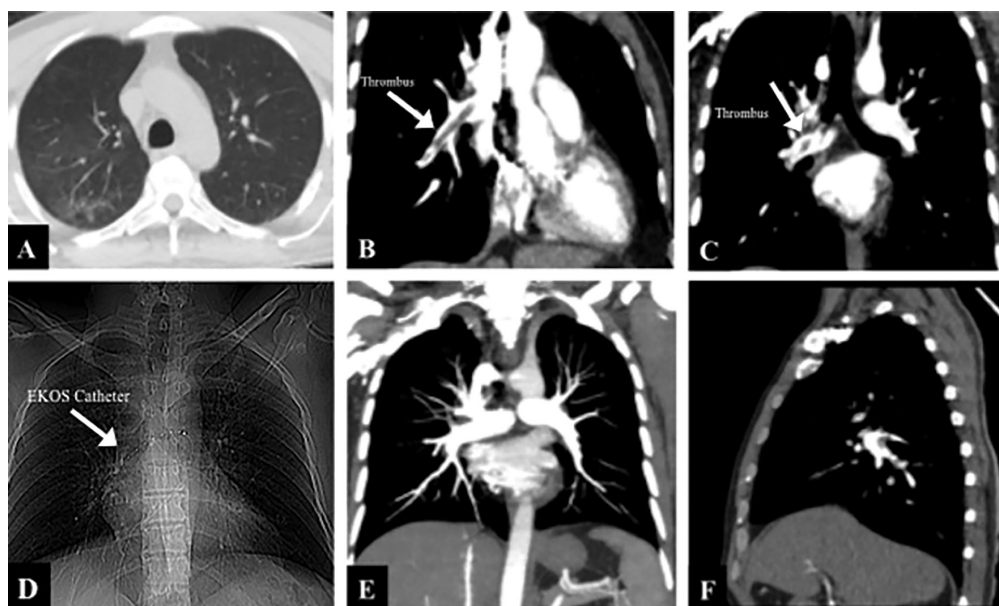

Figure 1. EKOS treatment for PE

EKOS: The EkoSonic™ Endovascular System, PE: Pulmonary embolism

[OP-79]**Preprocedural Inflammatory Markers Predict MACE but Not Permanent Pacemaker Requirement After Transcatheter Aortic Valve Implantation**

Deniz Dilan Naki Tekin

University of Health Sciences Türkiye, Başakşehir Çam and Sakura City Hospital, Istanbul

Aim: Systemic inflammation is increasingly recognized as an important determinant of adverse cardiovascular outcomes after transcatheter aortic valve implantation (TAVI). However, its role in predicting conduction disturbances requiring permanent pacemaker implantation (PPM) remains unclear. This study aimed to evaluate the association between preprocedural inflammatory markers and both major adverse cardiovascular events (MACE) and PPM after TAVI.

Methods: A total of 152 patients undergoing TAVI were retrospectively analyzed. Preprocedural inflammatory markers including neutrophil-to-lymphocyte ratio (NLR), systemic immune-inflammation index (SII), and C-reactive protein (CRP) were evaluated. Patients were stratified according to the occurrence of post-procedural pacemaker implantation (P. PACE) and MACE. Continuous variables were expressed as median (IQR) and compared using the Mann-Whitney U test. Receiver operating characteristic (ROC) analysis was performed to determine predictive performance and optimal cut-off values.

Results: 1. Patient characteristics

A total of 152 patients were included in the study. The median age was 78 years (IQR 71-83), and the median BMI was 28.3 kg/m² (IQR 24.5-32.1). Baseline demographic and clinical characteristics are summarized in Table 1. Among the cohort, 59.2% were male, and 40.8% were female. Comorbidities were common: hypertension (86.8%), hyperlipidemia (75.0%), diabetes mellitus (53.9%), smoking (82.2%), coronary artery disease (65.8%), pulmonary arterial hypertension (92.8%), bundle branch block (83.6%), renal failure (81.6%), chronic obstructive pulmonary disease (79.6%), cerebrovascular events (93.4%), and atrial fibrillation (27.0%).

2. Biomarker analysis by P. PACE

Comparison of NLR, SII, and CRP between patients with and without P. PACE showed no statistically significant differences: this suggests that baseline inflammatory markers were similar regardless of P. PACE status.

3. Biomarker analysis by MACE

In contrast, patients who experienced MACE events had significantly higher levels of NLR, SII, and CRP compared to those who did not: these results indicate a strong association between elevated inflammatory markers and the occurrence of MACE.

4. Predictive performance of biomarkers

ROC analysis was performed to assess the discriminative ability of NLR, SII, and CRP for predicting MACE. The optimal cut-off values, along with sensitivity, specificity, and AUC, are summarized below: the NLR demonstrated the highest AUC, followed closely by SII, suggesting excellent predictive performance for identifying patients at risk of MACE. Among the study population, no significant differences were observed in NLR, SII, or CRP levels

between patients with and without P. PACE (all $p > 0.05$). In contrast, patients who experienced MACE had significantly higher inflammatory marker levels compared to those without MACE (NLR: 4.89 vs. 2.16; SII: 1207 vs. 462; CRP: 27.8 vs. 4.8; all $p < 0.001$). ROC analysis demonstrated excellent discriminative ability for MACE prediction, with NLR showing the highest performance (AUC: 0.913), followed by SII (AUC: 0.867) and CRP (AUC: 0.821). An NLR cut-off value of 3.17 yielded 84.8% sensitivity and 89.1% specificity.

Conclusion: Preprocedural systemic inflammatory markers are strongly associated with MACE after TAVI, with NLR demonstrating the highest predictive performance. However, these markers do not predict permanent pacemaker requirement, suggesting that inflammatory burden influences ischemic outcomes rather than conduction system disturbances.

Keywords: Inflammation major adverse cardiovascular events, neutrophil-to-lymphocyte ratio, systemic immune-inflammation index, transcatheter aortic valve implantation

Table 1. Baseline clinical characteristics

Variable	Value
Age (years)	78 (57-93)
BMI (kg/m ²)	28.3 (17.6-46.9)
Male sex	90 (59.2%)
Hyperlipidemia	114 (75.0%)
Hypertension	132 (86.8%)
Diabetes mellitus	82 (53.9%)
Smoking	27 (17.8%)
Coronary artery disease	100 (65.8%)
Pulmonary hypertension	11 (7.2%)
Bundle branch block	25 (16.4%)
Renal failure	28 (18.4%)
COPD	31 (20.4%)
Cerebrovascular disease	10 (6.6%)
Atrial fibrillation	41 (27.0%)

BMI: Body mass index, COPD: Chronic obstructive pulmonary disease

Table 2. ROC analysis for prediction of MACE

Variable	Cut-off	Sensitivity (%)	Specificity (%)	AUC
NLR	3.17	84.8	89.1	0.913
SII	851.36	72.7	89.1	0.867
CRP	12.60	78.8	84.0	0.821

NLR showed the highest discriminative ability with an AUC of 0.91
 ROC: Receiver operating characteristic, MACE: Major adverse cardiovascular events, AUC: Area under the curve, NLR: Neutrophil-to-lymphocyte ratio, SII: Systemic immune-inflammation index, CRP: C-reactive protein

[OP-80]**Acute Type A Aortic Dissection Following Transcatheter Aortic Valve Implantation in Bicuspid Aortic Valve Stenosis**

Şükriye Uslu, Nermin Bayar, Şakir Arslan

Clinic of Cardiology, University of Health Sciences Türkiye, Antalya Training and Research Hospital, Antalya

Aim: Iatrogenic aortic dissection developing during transcatheter aortic valve implantation (TAVI) is a rare but fatal complication.

Case Report: A 77-year-old female patient presenting with progressive dyspnea and syncope was found to have severe bicuspid aortic stenosis (valve area: 0.4 cm²) and ascending aortic dilatation (48 mm). TAVI was planned for the frail patient, who was deemed at high surgical risk for aortic valve and ascending aortic replacement (STS score 5.2%), and preoperative evaluations were performed. For the high-risk TAVI procedure, the right femoral artery was cannulated, and a single ProGlide was placed in a neutral position. The aortic valve was crossed with an AL1 catheter, and a Safari wire was placed in the ventricle. Predilatation and sizing were performed with a 25 mm balloon on the valve, which had severe calcification and a bicuspid structure. Subsequently, a 27.5 mm myval transcatheter heart valve (THV) was implanted in an appropriate position. Control aortography revealed no aortic regurgitation; however, a dissection originating from the right sinus was observed in the ascending aorta. An emergency computed tomography (CT) scan was planned for the hemodynamically stable patient. Upon observing an ascending aortic diameter of 50 mm, a dissection flap extending from the ascending aorta to the aortic arch and its branches, and filling defects in the brachiocephalic and right common carotid arteries on the CT scan, an urgent cardiovascular consultation was requested. The patient was taken to surgery with a diagnosis of Stanford type A dissection, where it was observed that the THV struts had dissected the aorta at the level of the right coronary ostium. The native valve and THV were resected, and a conduit prepared with a mechanical valve and tube graft was implanted, along with a saphenous vein bypass to the right coronary artery. The patient, who failed to achieve hemodynamic stabilization during intensive care follow-ups, was lost.

Conclusion: It is known that TAVI-related iatrogenic aortic dissection, a rare but fatal complication, is more frequently seen in cases with aortic aneurysm. It should be kept in mind that the TAVI procedure is also high-risk, especially in patients with a heavily calcified bicuspid valve and aortic aneurysm.

Keywords: TAVI, transcatheter aortic valve implantation, aortic dissection, aortic aneurysm, bicuspid valve

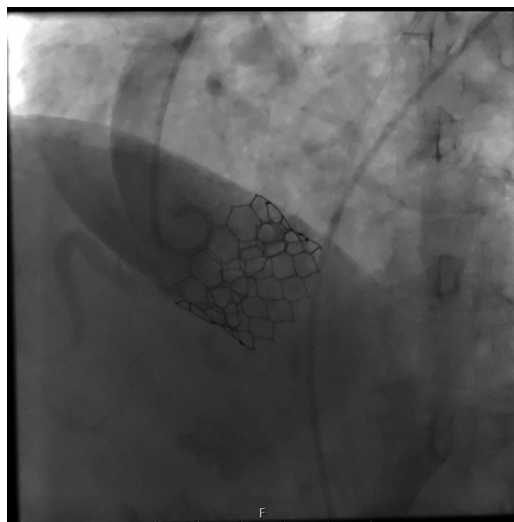


Figure 1. Dissection flebi

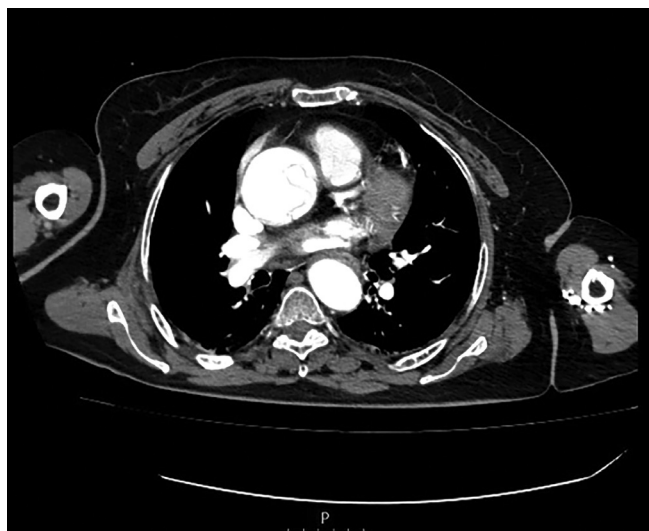


Figure 2. Ascending aortic dissection flap

[OP-81]**Predictors of Mortality in Diabetic Patients Undergoing Transcatheter Aortic Valve Implantation**Emre Paçacı¹, Abdullah Yıldırım², Emre Sezici², Gülüzar Traş³, İbrahim Halil Kurt²¹Clinic of Cardiology, University of Health Sciences Türkiye, Osmaniye Training and Research Hospital, Osmaniye²Clinic of Cardiology, University of Health Sciences Türkiye, Adana City Training and Research Hospital, Adana³Clinic of Cardiology, University of Health Sciences Türkiye, Mersin City Education and Research Hospital, Mersin

Aim: Diabetes mellitus is a common comorbidity in patients undergoing transcatheter aortic valve implantation (TAVI) and is often associated with adverse clinical outcomes. However, the specific factors predicting mortality within the diabetic subgroup remain poorly defined. This study aimed to evaluate the clinical and laboratory parameters that predict mortality in diabetic patients treated with TAVI.

Methods: This single-center retrospective study included patients diagnosed with diabetes mellitus who underwent TAVI. Clinical, laboratory, and echocardiographic data were retrieved from institutional electronic health records. Patients were categorized into two groups based on 1-year mortality status, and their clinical characteristics were compared. Cox regression analysis was performed to identify independent predictors of mortality.

Results: A total of 173 diabetic patients who underwent TAVI were included in the study. During the follow-up period, mortality occurred in 24 patients. Patients in the mortality group exhibited significantly higher STS scores, lower hemoglobin and albumin levels, and lower platelet counts. In the multivariate Cox regression analysis, hemoglobin level was identified as an independent predictor of mortality (HR: 0.71, 95% CI: 0.54-0.94, $p=0.015$).

Conclusion: Lower hemoglobin levels were found to be an independent predictor of mortality in diabetic patients undergoing TAVI. Additionally, lower platelet counts were observed in patients who reached the mortality endpoint. These findings suggest that hemoglobin levels, in particular, may carry significant prognostic value in the management and risk stratification of diabetic TAVI patients.

Table 1. Comparison of baseline clinical and laboratory characteristics according to mortality status in diabetic patients

Variables	Alive (n=149)	Deceased (n=24)	p value
Age, years	74.5±7.5	76.6±5.9	0.139
Gender, male, n (%)	53 (35.6)	9 (37.5)	0.855
BMI kg/m ²	26.9±4.4	27.3±5.6	0.671
STS PROM score, %	8.0±3.7	9.9±4.3	0.026
Hemoglobin, g/dL	11.7±1.3	11.0±1.6	0.020
Total cholesterol, mg/dL	182.3±46.5	176.3±40.4	0.550
GFR, mL/min/1.73m ²	71.4±21.0	62.0±28.3	0.132
Platelet count, ×10 ³ /μL	237.9±84.4	192.1±82.15	0.014
Albumin, g/L	37.3±5.05	34.5±3.8	0.009
Left ventricular ejection fraction, %	52.5±11.1	50.3±11.5	0.368
Hypertension, n (%)	123 (82.6)	20 (83.4)	0.925
Hyperlipidemia, n (%)	42 (28.2)	6 (25)	0.746
Coronary artery disease, n (%)	93 (62.4)	17 (70.8)	0.426
Prior atrial fibrillation, n (%)	19 (12.8)	4 (16.7)	0.600
eSPAP, mm Hg	36.9±11.1	41.1±12.9	0.136

e-SPAP: Estimated systolic pulmonary artery pressure, STS PROM: Society of thoracic surgeons predicted risk of mortality, BMI: Body mass index

Table 2. Cox regression analysis for mortality prediction

Variables	Hazard ratio	95% CI	p value
Age, years	0.97	0.90-1.03	0.345
STS PROM score	1.08	0.97-1.20	0.151
Hemoglobin	0.71	0.54-0.94	0.015
Platelet count	1.008	1.001-1.015	0.016
Albumin	0.95	0.90-1.00	0.055
Left ventricular ejection fraction	1.00	0.96-1.03	0.920

[OP-82]**Balloon Shaft Rupture During Myval TAVI: A Rare Complication and Successful Bailout Strategy**

Ali Rıza Akyüz, Selim Kul

Clinic of Cardiology, University of Health Sciences Türkiye, Ahi Evren Thoracic and Cardiovascular Surgery Training and Research Hospital, Trabzon

Aim: Balloon-expandable valves such as the Myval transcatheter heart valve have become reliable tools in transcatheter aortic valve implantation (TAVI), offering favorable hemodynamic results and ease of deployment. However, unexpected device-related complications-though rare-can arise and require immediate resolution. We present a case of delivery balloon shaft rupture during Myval implantation and describe the technical steps for a successful bailout.

Case Report: An 83-year-old male with a history of coronary artery disease was referred to our institution for symptomatic severe aortic stenosis. Transthoracic echocardiography revealed an aortic valve area of 0.57 cm² and a mean transvalvular gradient of 70 mmHg. Computed tomography demonstrated an annulus area of 475 mm² with an area-derived diameter of 24.5 mm and significant annular calcification. After heart team discussion, transfemoral TAVI with a 24.5 mm Myval valve (Meril Life Sciences, India) was planned. A Safari wire was positioned in the left ventricle, and the Myval system was advanced. During rapid ventricular pacing, balloon inflation failed-suggesting balloon shaft rupture (Figure 1A). The undeployed valve and balloon system were gently pulled back into the descending aorta (Figure

1B). Attempts to detach the ruptured balloon from the valve using standard maneuvers, including hydrophilic wire passage via AL2 catheter support, were unsuccessful. To facilitate balloon release, 1 mg of propofol diluted in 10 mL of saline was injected through the ruptured balloon to reduce friction. Next, the delivery catheter was flexed and the valve was advanced with a pigtail catheter, successfully disengaging the balloon. However, the ruptured balloon could not be recaptured into the sheath and was removed together with the system (Figure 1C). A second 24.5 mm Myval valve was prepared. Prior to implantation, the native valve was predilated with a 20 mm balloon. Deployment was performed under fluoroscopic guidance at the annular level using anatomical landmarks and calcifications (Figure 1E). Final aortography showed no paravalvular leak or aortic regurgitation. The access site was closed with a Perclose ProGlide system. Delivery system failure during TAVI is a rare but potentially serious event. While most literature describes issues with valve positioning, embolization, or annular rupture, balloon shaft rupture has not been widely reported, particularly with the Myval system. In this case, an innovative combination of chemical lubrication with diluted propofol and mechanical maneuvers enabled device separation. This case also demonstrates that reusing the same valve for descending aorta implantation is feasible and safe. Operators should be aware of potential mechanical failure during inflation, and be prepared with alternative solutions including wire redirection, catheter flexion, and in rare cases, complete system removal.

Conclusion: Balloon shaft rupture during TAVI is extremely rare. Prompt recognition and application of creative bailout techniques can prevent serious complications and ensure procedural success. Sharing such unique experiences may help guide other operators in managing similar events.

Keywords: Transcatheter aortic valve replacement, myval, balloon rupture, TAVI complication, bailout technique

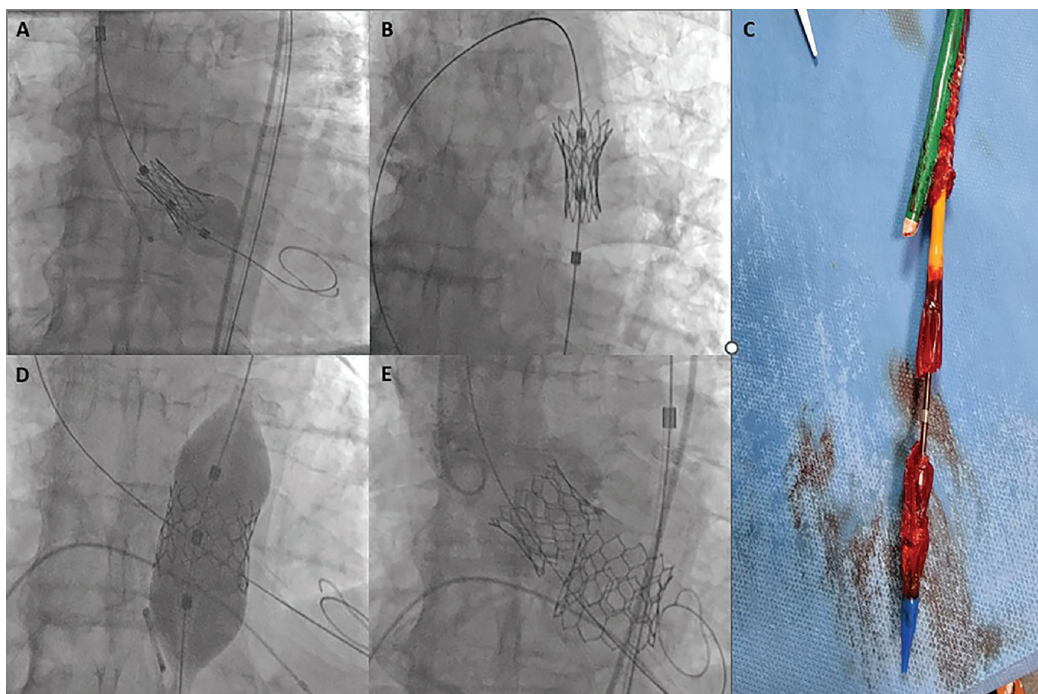


Figure 1. (A) Balloon shaft rupture after attempted inflation. (B) Valve pulled into the descending aorta. (C) Ruptured balloon seen after system removal. (D) Implantation of the first valve in descending aorta using a 27.5 mm balloon. (E) Second valve deployed successfully at annular level

[OP-84]**Successful Transfemoral TAVI in a Patient with Bicuspid Aortic Valve, Low-Flow Low-Gradient Aortic Stenosis, and Severe Peripheral Artery Disease**

Metin Çoksevim¹, Ali Can Özdemir¹, Meliye Hatun Başer¹, Ömer Kertmen², Mahmut Şahin¹

¹Department of Cardiology, Ondokuz Mayıs University Faculty of Medicine, Samsun

²Department of Cardiology, Amasya Üniversitesi Faculty of Medicine, Amasya

Aim: Determining the optimal treatment strategy for patients presenting with advanced aortic stenosis (AS) and severe left ventricular dysfunction is challenging due to the high mortality risk. In particular, cases involving low-flow low-gradient (LF-LG) AS, bicuspid aortic valve (BAV) anatomy, and concomitant advanced peripheral artery disease (PAD) may present significant technical difficulties for transcatheter aortic valve implantation (TAVI). In this report, we aimed to present a successful transfemoral TAVI procedure in a patient with low ejection fraction (EF), complex PAD, and borderline cardiogenic shock.

Case Report: A patient with a history of coronary artery bypass graft (CABG) surgery, atrial fibrillation (AF), diabetes mellitus, and ischemic dilated cardiomyopathy was admitted to our clinic in a decompensated state with borderline hypotension. The electrocardiogram revealed AF with a rapid ventricular response. Transthoracic echocardiography showed a left ventricular ejection fraction (LVEF) of 20%. All cardiac chambers were dilated, with the left ventricle being severely affected (69/62 mm). The septum, anterior wall, and apex were akinetic, while other segments were hypokinetic. The aortic valve was severely calcified, with a peak velocity of 2.6 m/s, a mean gradient of 23 mmHg, and an aortic valve area (AVA) of 0.4 cm², suggesting LF-LG severe AS. Additionally, mild mitral regurgitation and moderate tricuspid

regurgitation were present. The pulmonary artery pressure was calculated at approximately 45 mmHg. The patient was admitted to the coronary care unit due to advanced heart failure, and positive inotropic and diuretic therapies were initiated. An aortic valve calcium score of 3200 (Figure 1) supported the diagnosis of severe AS. Dobutamine stress echocardiography revealed a peak velocity >4 m/s, a mean gradient (Pmean) of 44 mmHg, and an AVA of 0.5 cm² at maximum dose. A stroke volume index (SVi) increase of >20% was observed. TAVI protocol computed tomography identified BAV (Type 0) anatomy and severe peripheral artery disease, including a total occlusion of the left iliac artery (Figure 1). Following evaluation by the Heart Team, transcatheter treatment was planned due to very high surgical risk. The patient's EuroSCORE II was calculated at 27.8%, and the STS score was over 12%.

Conclusion: The procedure was performed in the catheterization laboratory under mild sedation, attended by anesthesia, cardiovascular surgery, and cardiology teams. A temporary pacemaker was placed via the right femoral vein. Due to severe PAD, percutaneous closure was planned using a single Proglide device via the left femoral artery, and a hydrophilic safety wire was placed in the left superficial femoral artery for potential complications (Video 1). Subsequently, a 14F long sheath was advanced into the abdominal aorta. Hemodynamic monitoring and aortic root imaging were performed via bilateral radial artery access (Video 2). The aortic valve was crossed using an AL2 catheter, and an extra-stiff guidewire was positioned in the left ventricle. Predilatation was performed with a 25 mm balloon prior to valve implantation (Video 3). Following predilatation, the patient rapidly became hemodynamically unstable, and cardiac arrest occurred. During this critical stage, a 30.5 mm Myval (Meril Life Sciences) transcatheter heart valve was implanted under rapid pacing. Hemodynamic stability was achieved after brief cardiopulmonary resuscitation, and the patient did not require intubation (Videos 4-5). Control aortography confirmed optimal valve positioning with no paravalvular leak (Video 6).

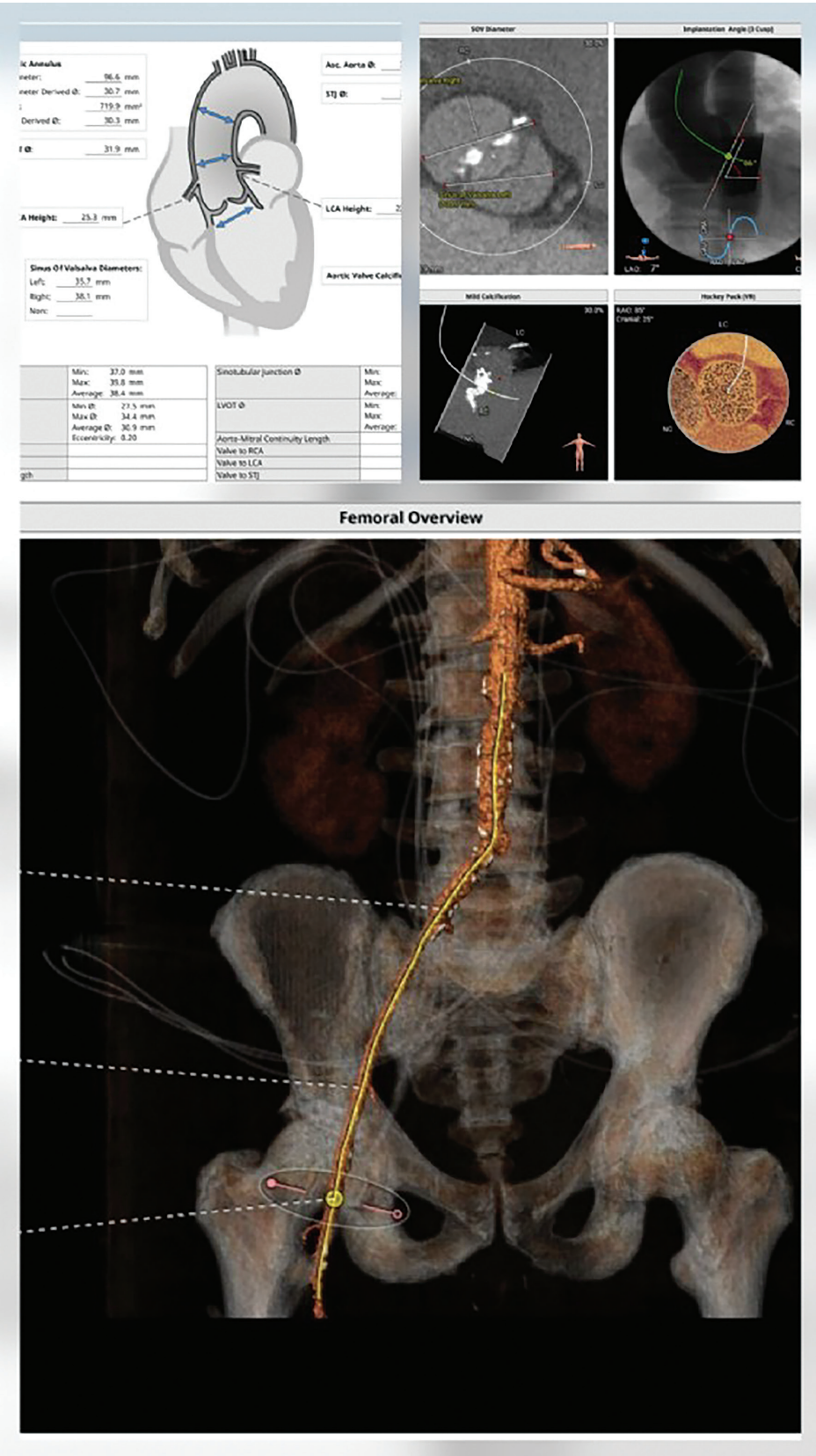


Figure 1. Computed tomography scans

[OP-85]

A One-Year Single-Center Experience in Pacemaker and ICD Implantations: Comparison of Patient Characteristics and Short-Term Outcomes

Cağlar Alp, Hüseyin Kandemir

Kırıkkale University Faculty of Medicine, Kırıkkale

Aim: To compare the real-world clinical characteristics of patients who underwent cardiac implantable electronic device (CIED) implantation or generator replacement in our clinic over the last year according to device types, and to evaluate short-term procedural safety.

Methods: A total of 97 consecutive patients who underwent pacemaker or implantable cardioverter-defibrillator (ICD) procedures at the Cardiology Clinic of Kırıkkale University Faculty of Medicine between January and December 2025 were retrospectively analyzed. Baseline demographic, clinical, and laboratory data, as well as device-related complication rates (in-hospital and post-discharge), were recorded and compared between the groups.

Results: Of the 97 patients included in the study, 38 underwent pacemaker and 59 underwent ICD implantation. The mean age was 69.8 ± 10.1 years, and 63.9% of the patients were male. Compared to the pacemaker group, patients in the ICD group were significantly younger (67.9 ± 10.4 vs. 72.9 ± 9.3 years, $p=0.019$), and the male sex ratio was higher (72.9% vs. 50.0%, $p=0.022$). Coronary artery disease was observed more frequently in the ICD group (93.2% vs. 73.7%, $p=0.008$). Left ventricular ejection fraction was significantly higher in the pacemaker group (56.3 ± 4.8 vs. 30.7 ± 8.9 , $p<0.001$). The generator replacement procedure was performed significantly more often in the ICD group (40.7% vs. 13.2%, $p=0.004$). In the short-term follow-up, the overall complication rate was 11.3% ($n=11$), and the in-hospital complication rate was 3.1% ($n=3$). All complications were minor, and no procedure-related major complications or mortality occurred in any patient. There was no statistically significant difference between the groups in terms of the development of any complication ($p=0.194$).

Conclusion: Our single-center real-world experience reflects the expected clinical and demographic differences in CIED recipients and demonstrates that procedures in both device groups are performed with remarkably low complication rates and a high safety profile.

Keywords: Artificial pacemaker, implantable cardioverter-defibrillator, complications, real-world data, procedural safety

Table 1. Comparison of patients' baseline characteristics by device type (Pacemaker vs. ICD)

Variable	Overall (n=97)	Pacemaker (n=38)	ICD (n=59)	p value
Demographic characteristics				
Age (years)	69.8±10.1	72.9±9.3	67.9±10.4	0.019
Male sex, n (%)	62 (63.9)	19 (50.0)	43 (72.9)	0.022
Comorbidities				
Diabetes mellitus, n (%)	52 (53.6)	20 (52.6)	32 (54.2)	0.877
Hypertension, n (%)	83 (85.6)	31 (81.6)	52 (88.1)	0.370
Coronary artery disease, n (%)	83 (85.6)	28 (73.7)	55 (93.2)	0.008
Prior cerebrovascular event, n (%)	13 (13.4)	5 (13.2)	8 (13.8)	0.929
Cardiac characteristics				
Left ventricular ejection fraction (%)	40.7±14.6	56.3±4.8	30.7±8.9	<0.001
Baseline rhythm / conduction status				
Sinus rhythm n (%)	42 (43.3)	5 (13.2)	37 (62.7)	<0.001
Atrial fibrillation n (%)	13 (13.4)	1 (2.6)	12 (20.3)	
AV block n (%)	42v(43.3)	32(84.2)	10 (16.9)	
Baseline QRS duration (ms)	114.1±29.7	118.0±30.7	112.7±32.4	0.986
Clinical outcomes				
Replacement procedure n (%)	29 (29.9)	5 (13.2)	24 (40.7)	0.004
Any complications, n (%)	11 (11.3)	2 (5.4)	9 (15.3)	0.194
In-hospital complication n (%)	3 (3.1)	1 (2.6)	2 (3.4)	0.833
Post-discharge complication n (%)	8 (8.2)	1 (2.6)	7 (11.9)	0.143
Laboratory parameters				
Hemoglobin (g/dL)	13.1±1.8	12.6±1.7	13.6±1.9	0.016
White blood cell count ($\times 10^3/\mu\text{L}$)	8.4±2.1	8.1±1.8	8.3±2.3	0.605
Platelet count ($\times 10^3/\mu\text{L}$)	220.4±59.6	214.9±61.9	223.9±58.6	0.471
C-reactive protein (mg/L)	7.4 (2.7-16.5)	6.9 (2.7-17.0)	7.7 (3.0-16.5)	0.953
Glucose (mg/dL)	131.2 ±56.7	127.3±41.6	133.2±65	0.623
Creatinine (mg/dL)	0.98 (0.84-1.27)	0.95 (0.78-1.25)	1.01 (0.86-1.29)	0.313
Estimated GFR (mL/min/1.73m ²)	68.0±21.5	65.9±22.1	69.4±21.2	0.443
Potassium (mmol/L)	4.45 ± 0.52	4.50±0.48	4.42±0.55	0.453
HbA1c (%)	6.0 (5.9-8.9)	6.3 (5.9-8.2)	6.0 (5.8-6.7)	0.163
TSH (mIU/L)	1.45 (0.95-2.33)	1.45 (0.90-2.13)	1.44 (1.00-2.59)	0.716
Albumin (g/dL)	4.17 ± 0.49	4.11±0.58	4.20±0.41	0.408

ICD: Implantable Cardioverter-Defibrillator; SD: Standard Deviation; AV: Atrioventricular; GFR: Glomerular Filtration Rate; HbA1c: Glycated Hemoglobin; TSH: Thyroid Stimulating Hormone.

Table 2. Comparison of baseline clinical and procedural characteristics according to short-term procedural safety and the development of composite complications

Variable	No complication (n=86)	Complication (n=11)	P Value
Demographic and clinical characteristics			
Age (years)	71.0 (64.0-81.4)	72.0 (66.0-75.0)	0.815
Male sex, n (%)	54 (62.8)	8 (72.7)	0.518
Left ventricular ejection fraction (%)	35.0 (27.0-56.5)	35 (25.0-44.0)	0.432
Comorbidities			
Diabetes mellitus, n (%)	44 (51.2)	8 (72.7)	0.177
Hypertension, n (%)	72 (83.7)	11 (100.0)	0.148
Coronary artery disease, n (%)	72 (83.7)	11 (100.0)	0.145
Prior cerebrovascular event, n (%)	10 (11.8)	3 (27.3)	0.157
Laboratory parameters			
Hemoglobin (g/dL)	13.5 (11.8-14.6)	13.4 (12.4-14.6)	0.811
C-reactive protein (mg/L)	6.8 (2.5-16.0)	8.3 (7.4-26.8)	0.339
Estimated GFR (mL/min/1.73m ²)	68.0 (51.0-86.5)	76.0 (64.0-89.0)	0.357
HbA1c (%)	6.0 (5.9-7.2)	6.0 (6.0-8.2)	0.872
Albumin (g/dL)	4.2 (3.9-4.5)	4.3 (3.9-4.4)	0.527
Glucose (mg/dL)	110.0 (93.0-144.0)	108.0 (94.0-211.0)	0.954
Device and procedural characteristics			
ICD, n (%)	50 (58.1)	9 (81.8)	0.130
Pacemaker, n (%)	36 (41.9)	2 (18.2)	
New implantation, n (%)	59 (68.6)	9 (81.8)	0.367
Generator replacement, n (%)	27 (31.4)	2 (18.2)	

ICD: Implantable Cardioverter-Defibrillator; GFR: Glomerular Filtration Rate; HbA1c: Glycated Hemoglobin; CRP: C-Reactive Protein

[OP-86]

Endovascular Treatment of Descending Thoracic Aortic Aneurysm with Severe Tortuosity Causing Tracheal and Esophageal Compression

Uğur Çetingök

University of Health Sciences Türkiye, Ankara Etlik City Hospital, Ankara

Aim: Tracheal and/or esophageal compression is a rare condition in thoracic aortic aneurysms. When there is severe tortuosity of the aorta, implantation of the device is difficult. Establishment of a brachio-femoral through and through a guidewire is an auxiliary manipulation in the presence of severe tortuosity. We present a case of a 75-years-old man treated with thoracic endovascular aortic repair (TEVAR). He had moderate dyspnea and dysphagia caused by descending thoracic aortic aneurysm with severe tortuosity.

Methods: A 75-year-old male was admitted with a history of dyspnea, stridor, dry cough, hoarseness of voice, chest pain, dysphagia and weight loss. CTA revealed a large fusiform aneurysm of descending thoracic aorta, and severe tortuosity. Aneurysmal dilatation was 88x290 mm. There was compression of the trachea and esophagus. Proximal neck angulation was 70 degrees.

In addition, aneurysms of the right and left iliac arteries and osteal stenosis of the right iliac artery were observed. TEVAR was performed with local anesthesia. Standard hydrophilic guidewire and pigtail catheter was delivered to the ascending aorta. But, the backup wire could not be exchanged due to excessive aortic tortuosity. The guidewire (Radiofocus® Glidewire, 0,035", 260 cm, Terumo, Japan) was inserted from the right brachial cannula to the outside of the left femoral cannula. The device was placed on the wire. Tension was applied to the wire by pulling it from the brachial and femoral ends. The system was delivered to the implantation level under wire guidance. Two Ankura™ thoracic stent grafts were used as a 36 mm x 200 mm proximal and a 46 mm x 150 mm distal device for zones 3-4 coverage. The devices were successfully delivered through highly tortuous anatomy and deployed, excluding the entire length of the aneurysm with precise landing, excellent apposition. The patient well tolerated the procedure.

Results: The patient had no dyspnea and no stridor after procedure. CT showed reduction the tracheal and esophageal compression on the first day. The patient was discharged from the hospital on the postoperative fifth day. Control CT angiography was performed four months later. Endoleak and compression to the trachea and esophagus was not detected. The visceral arteries were patent.

Conclusion: TEVAR is safer than open surgery, it can also be applied with some special manipulations in severe tortuosity of the aorta.

Keywords: Endovascular repair, thoracic aortic aneurysms, tortuosity

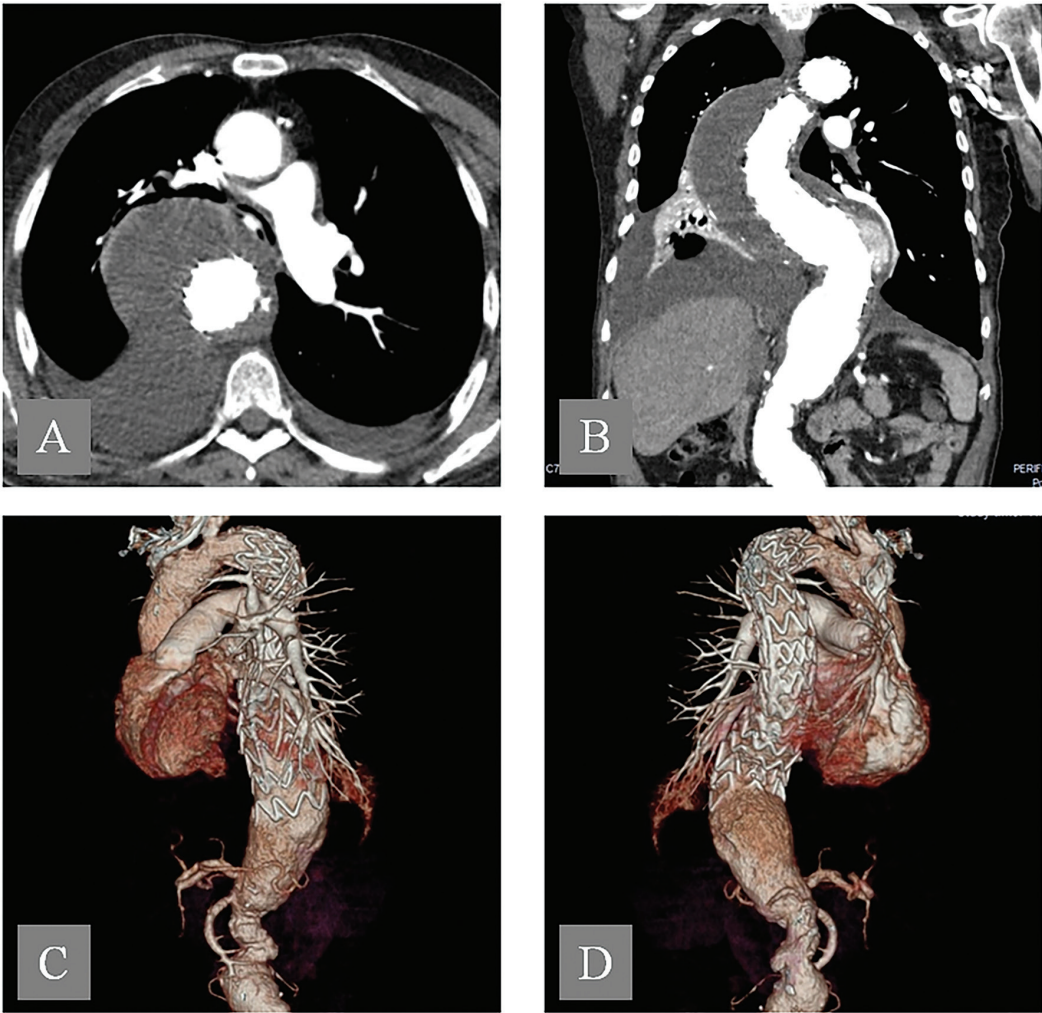


Figure 1. Control CT angiography after 4 months from TEVAR
CT: Computed tomography, TEVAR: Thoracic endovascular aortic repair

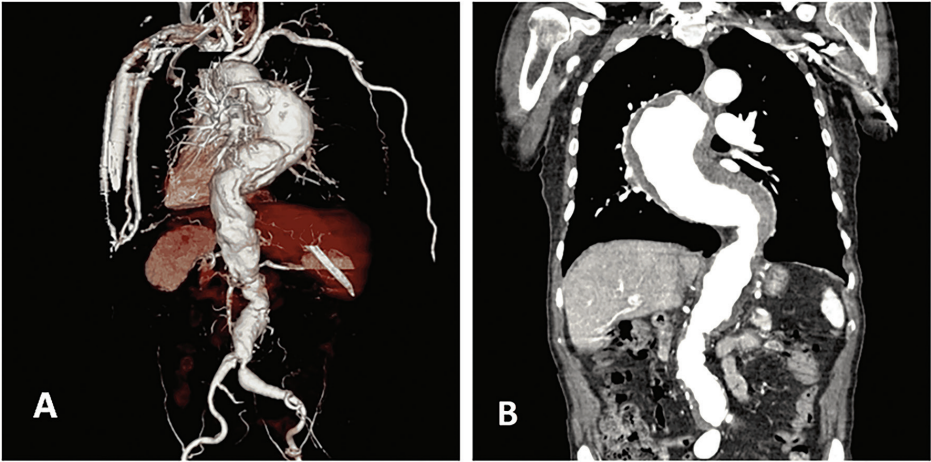


Figure 2. Severe tortuosity of DTA

[OP-87]**The Role of Pharmacological Cocktails in Preventing Radial Spasm During Percutaneous Coronary Intervention: A Prospective Clinical Study in Uzbekistan**

Sherzod Akhmedov

¹Ezgu Niyat Clinic, Tashkent²Carmen Clinic, Bukhara

Aim: Transradial access (TRA) has become the preferred approach for percutaneous coronary intervention (PCI) due to reduced bleeding complications, earlier mobilization, and improved patient comfort. However, radial artery spasm (RAS) remains a common procedural challenge that can lead to patient discomfort, procedural delay, and access failure. Pharmacological strategies aimed at preventing RAS are widely used, yet data comparing specific drug combinations remain limited. To evaluate the efficacy and safety of a pharmacological cocktail consisting of nitroglycerin, verapamil, and heparin in preventing radial artery spasm and related complications during PCI.

Methods: A prospective randomized clinical study was conducted from January to December 2024 at Ezgu Niyat Clinic (Tashkent) and Carmen + Clinic (Bukhara), Uzbekistan. A total of 900 patients with coronary artery disease scheduled for elective PCI via radial access were enrolled. Patients were randomly assigned to two groups:

Cocktail group: intra-arterial nitroglycerin (100 mcg), verapamil (2.5 mg), and heparin (5000 IU) administered before the procedure.

Control group: no premedication.

Primary outcomes included the incidence of radial artery spasm confirmed clinically and by Doppler assessment. Secondary outcomes included pain intensity measured using the Visual Analog Scale (VAS), access site complications (hematoma, radial artery occlusion, crossover to femoral access), and hemodynamic stability.

Results: The incidence of radial artery spasm was significantly lower in the cocktail group compared with the control group (4.8% vs. 18.2%, $p < 0.001$).

Pain scores were also significantly reduced in patients receiving the cocktail (VAS 2.1 ± 0.8 vs. 4.3 ± 1.1 , $p < 0.001$).

Access site complications were less frequent in the cocktail group:

Grade II hematomas: 1.8% vs. 5.4%

Radial artery occlusion: 0.7% vs. 3.6%

Femoral crossover: 1 case vs. 8 cases

No clinically significant hemodynamic instability was observed in either group.

Conclusion: Premedication with a nitroglycerin-verapamil-heparin cocktail significantly reduces radial artery spasm, procedural pain, and vascular complications during transradial PCI. These findings support the routine use of this pharmacological strategy to improve procedural success and patient safety in interventional cardiology.

Keywords: Radial artery spasm, nitroglycerin, transradial access

[P-88]

A Compact Unified Model for Moderate-to-Severe Carotid Artery Stenosis Using Image Segmentation: A Multicenter Study

Talat Tavlı¹, Ahmet Tavlı², İlker Gül³, Murat Ertürk⁴, Haydar Yaşa⁵, Haluk Mergen⁶, Bülent Cumen⁷

¹Clinic of Cardiology, Central Hospital, İzmir,

²Department of Computer Science, Özyeğin University, İstanbul

³Department of Cardiology, Bakırçay University, İzmir

⁴Department of Cardiology, Başkent University, İzmir

⁵Clinic of Cardiovascular Surgery, University of Health Sciences Türkiye, İzmir Tepecik Training and Research Hospital, İzmir

⁶Clinic of Public Health, University of Health Science Türkiye, İzmir Tepecik Training and Research Hospital, İzmir

⁷Clinic of Cardiovascular Surgery, Denizli State Hospital, Denizli

Aim: This study aims to investigate the diagnostic accuracy of a new AI model, the compact unified model (CU-Model), in patients with moderate to severe carotid artery stenosis compared to digital subtraction angiographic (DSA) images and clinical findings.

Methods: This study was designed as a retrospective cohort study. It included 156 patients with confirmed moderate to severe carotid artery stenosis. We used a pretrained CU-Model to process the DSA images without fine-tuning on clinical data. Two double-blind researchers from the medical centers were asked to interpret the images.

Results: DSA images processed by the CU-Model (an artificial intelligence model) revealed left internal carotid artery stenosis (ICAS) in 84 patients and right ICAS in the remaining 72. Compared with the DSA technique, the CU-Model misclassified only one case of moderate left ICA stenosis as normal. Of all the cases, 106 were assessed as moderate stenosis (50-69%), and 50 as severe stenosis (≥70%). These thresholds were defined as 50-69% for moderate stenosis, accounting for measurement variability, adapted to NASCET standards. The results of the CU-Model-processed images compare favorably with the standard DSA images in assessing moderate and severe carotid artery stenosis [57.68±5.94 and 57.71±6.19, respectively; r=0.83 (95% CI: 0.76-0.88), p<0.001; 86.96±5.97 and 87.02±6.18, r=0.91 (95% CI: 0.85-0.95), p<0.001]. The most common risk factors were hypertension (77%), smoking, and syncope, which were significant risk factors in patients with symptomatic carotid artery disease (p<0.05).

Conclusion: The images obtained using the new artificial intelligence technique were shown to compare favorably with the standard angiographic images, demonstrating a practical, easily applicable method. Pending larger studies, the CU-Model shows promise as a complementary post-DSA tool for efficient image processing.

Keywords: Carotid artery stenosis, digital subtraction angiography, compact unified model, artificial intelligence

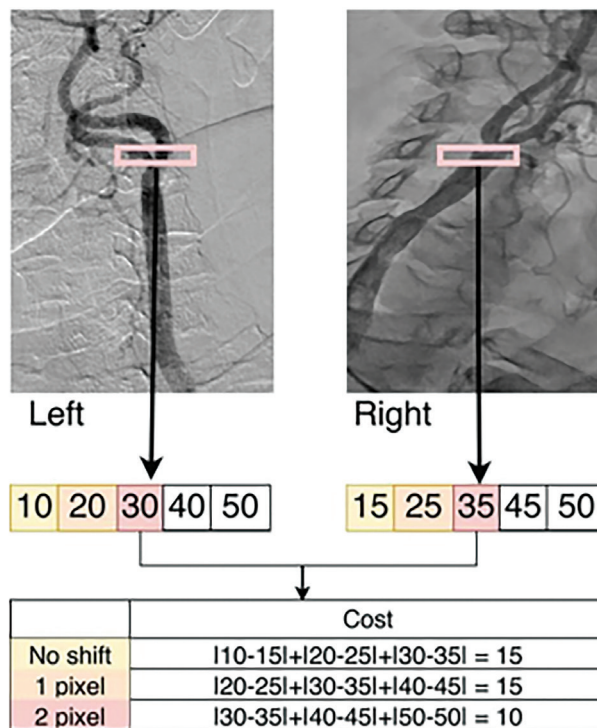


Figure 1. Traditional calculation of the pixel-wise match cost

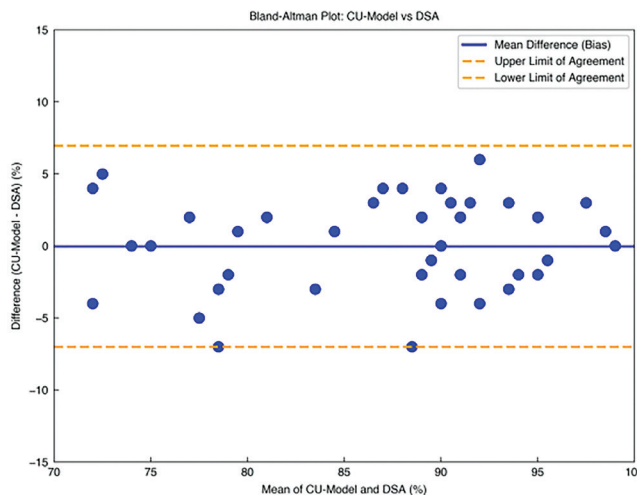


Figure 2. Linear correlation coefficient for inter-observer variability in patients with moderate to severe carotid artery stenosis (CUM-1 vs CUM-2), CUM1: Compact Unified Model (reader 1), CUM2: Compact Unified Model (reader 2)

Table 1. Baseline characteristics of study population

Characteristics	Value	Symptomatic	Asymptomatic	p value
Sample size	156	82	74	
Male	118 (75.6%)	52 (63%)	48 (66%)	0.05
Age years (mean \pm SD)	68 \pm 12	67 \pm 11.8	69 \pm 12.3	0.05
Obesity	87 (55.7 %)	48 (58%)	39 (52%)	0.05
Hypertension	121 (77 %)	71 (86%)	50 (67%)	0.009
Diabetes mellitus	42 (26 %)	22 (26%)	20 (27%)	0.05
Hypercholesterolemia	89 (57.5 %)	48 (58%)	41 (55%)	0.05
Smokers	104 (66%)	68 (82%)	36 (48%)	0.05
Sencopy	23 (14.7%)	23 (28%)	-	0.05
Presence of Left ICA	84 (53.8 %)	44 (53%)	40 (54%)	0.05
Right ICA	72 (46.1 %)	39 (47%)	33 (44%)	0.05

ICA: Internal carotid artery

Table 2. Compact-Unified Model (CU-Model) results for Inter observer variability in patients with carotis artery stenosis

	CU-Model-1	CU-Model-2	r value
Modarate Stenosis (n=106)	57.46 \pm 7.23	57.93 \pm 6.53	0.91
Severe Stenosis (n=50)	84.41 \pm 8.27	81.88 \pm 7.92	0.89

CU-Model (reader 1), Compact Unified Model, CU-Model-2, Compact Unified Model (reader 2)

[OP-89]**Inflammatory and Platelet Biomarkers Predicting Early Cerebrovascular Complications After Carotid Angiography**

Ali Evsen

Clinic of Cardiology, Dağkapı State Hospital, Diyarbakır

Aim: Early cerebrovascular complications following carotid angiography remain clinically important events associated with increased morbidity. Inflammatory processes and platelet activation are considered key mechanisms in the development of periprocedural cerebrovascular events. Simple hematological biomarkers derived from routine blood tests may provide additional information for identifying patients at increased risk. Therefore, this study aimed to evaluate the predictive value of inflammatory and platelet biomarkers for early cerebrovascular complications after carotid angiography.

Methods: This retrospective study included 316 consecutive patients who underwent carotid angiography. Early cerebrovascular complications were defined as the occurrence of stroke, transient ischemic attack (TIA), or amaurosis fugax within 48-72 hours after the procedure. Baseline clinical characteristics and laboratory parameters were compared between patients with and without early cerebrovascular complications. Inflammatory and platelet biomarkers including plateletcrit (PCT), mean platelet volume (MPV), neutrophil-to-lymphocyte ratio (NLR), platelet-to-lymphocyte ratio (PLR), and C-reactive protein (CRP) were evaluated. Univariable and multivariable logistic regression analyses were performed to identify potential predictors. Receiver operating characteristic (ROC) curve analysis was used to assess the discriminative ability of the biomarkers.

Results: Early cerebrovascular complications occurred in 58 patients (18.4%). Baseline characteristics were largely comparable between patients with and without complications, although patients with complications had numerically higher rates of diabetes mellitus and higher CRP levels. In univariable logistic regression analysis, platelet-related biomarkers including PCT, MPV, and PLR, as well as NLR, were not significantly associated with early cerebrovascular complications. Diabetes mellitus and CRP demonstrated borderline associations with early cerebrovascular events. In multivariable logistic regression analysis including age, diabetes mellitus, CRP, PCT, and NLR, none of the evaluated biomarkers were identified as independent predictors of early cerebrovascular complications. ROC curve analysis showed limited

discriminative ability for all evaluated biomarkers (AUC values: PCT 0.47, NLR 0.52, PLR 0.48, CRP 0.53), with CRP demonstrating the highest but still modest predictive performance.

Conclusion: In this study, inflammatory and platelet biomarkers derived from routine blood tests were not independently associated with early cerebrovascular complications after carotid angiography. Although CRP demonstrated the highest discriminative ability among the evaluated biomarkers, its predictive performance remained limited. These findings suggest that routine inflammatory and platelet biomarkers alone may have limited utility for identifying patients at risk of early cerebrovascular complications following carotid angiography.

Keywords: Carotid angiography, cerebrovascular complications, plateletcrit, NLR, PLR, inflammation

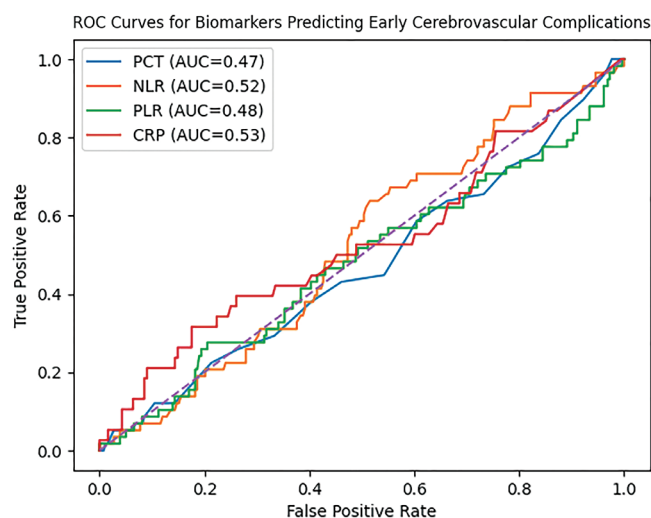


Figure 1. ROC curves for biomarkers predicting early cerebrovascular complications. Receiver operating characteristic (ROC) curves of plateletcrit (PCT), neutrophil-to-lymphocyte ratio (NLR), platelet-to-lymphocyte ratio (PLR), and C-reactive protein (CRP) for predicting early cerebrovascular complications following carotid angiography

Table 1. Baseline characteristics according to early cerebrovascular complications

Variable	No complication (n=258)	Complication (n=58)	p value
Age (years)	69.3±9.6	68.8±9.9	0.60
Female sex, n (%)	94 (36.4%)	24 (41.4%)	0.48
Hypertension, n (%)	188 (72.9%)	45 (77.6%)	0.44
Diabetes mellitus, n (%)	92 (35.7%)	28 (48.3%)	0.10
Hyperlipidemia, n (%)	146 (56.6%)	34 (58.6%)	0.72
Smoking, n (%)	105 (40.7%)	24 (41.4%)	0.99
Coronary artery disease, n (%)	117 (45.3%)	24 (41.4%)	0.73
Platelet count	248±67	243±69	0.45
Mean platelet volume	10.3±1.2	10.4±1.3	0.56
Plateletcrit	0.21±0.07	0.20±0.06	0.63
Neutrophil-to-lymphocyte ratio	2.8±1.9	0.20±0.06	0.30
Platelet-to-lymphocyte ratio	136±71	142±75	0.27
C-reactive protein	5.2±4.7	6.8±5.1	0.08

Table 2. Univariable and multivariable logistic regression analysis for early cerebrovascular complications

Variable	Univariable OR (95% CI)	p value	Multivariable OR (95% CI)	p value
Age	0.99 (0.96-1.02)	0.60	0.99 (0.96-1.02)	0.62
Female sex	1.19 (0.72-1.96)	0.54		
Hypertension	1.25 (0.71-2.20)	0.44		
Diabetes mellitus	1.65 (0.92-2.95)	0.10	1.53 (0.84-2.80)	0.15
Hyperlipidemia	1.11 (0.63-1.94)	0.72		
Smoking	1.00 (0.57-1.77)	0.99		
Coronary artery disease	0.90 (0.52-1.56)	0.73		
Platelet count	0.99 (0.99-1.01)	0.45		
Mean platelet volume	1.05 (0.89-1.24)	0.56		
Plateletcrit	0.38 (0.02-6.18)	0.63	0.41 (0.02-7.11)	0.66
Neutrophil-to-lymphocyte ratio	1.01 (0.99-1.04)	0.30	1.01 (0.98-1.05)	0.35
Platelet-to-lymphocyte ratio	1.00 (0.99-1.01)	0.27		
C-reactive protein	1.09 (0.99-1.19)	0.08	1.08 (0.99-1.18)	0.09

OR: Odds ratio, CI: Confidence interval

[OP-91]**Stepwise Hemodynamic Stabilization in Refractory Advanced Heart Failure: Sequential PCI, CRT Upgrade, and Salvage TEER**

Mehdi Onaç, Mehmet Vatankulu, Enes Alıç, Ahmad Huraibat, Emrah Ermiş, Sinem Özbay Özyılmaz, Hakan Ucar

Istanbul Aydın University, VM Medical Park Florya Hospital, Istanbul

Aim: Advanced decompensated heart failure often reflects the interplay of multiple pathophysiological mechanisms. Myocardial ischemia, electrical dyssynchrony, and secondary mitral regurgitation may coexist and collectively aggravate hemodynamic instability. In patients considered unsuitable for surgery, management may evolve as a stepwise strategy targeting the dominant contributor to decompensation rather than following a predefined treatment algorithm.

Case Report: An 81-year-old hemodialysis-dependent man with a history of transcatheter aortic valve implantation and permanent pacemaker implantation presented with acute pulmonary edema and hypotension. Baseline evaluation revealed severe left ventricular systolic dysfunction (LVEF 30%), left bundle branch block (QRS 160 ms), severe functional mitral regurgitation, and complex multivessel coronary artery disease. Combined surgical revascularization and mitral valve surgery were considered prohibitive by the Heart Team. A high-risk multivessel percutaneous coronary intervention (PCI) was initially performed to reduce the ischemic burden. Although partial hemodynamic stabilization was achieved, significant congestion persisted. Because of the persistently wide QRS complex and evidence of mechanical dyssynchrony, the existing pacemaker system was upgraded to cardiac resynchronization therapy (CRT). This resulted in QRS narrowing and a modest improvement in left ventricular ejection fraction. Despite these improvements, recurrent pulmonary edema continued, particularly on non-dialysis days. Follow-up imaging demonstrated persistent severe mitral regurgitation despite partial recovery of ventricular function. Although the mitral valve anatomy was considered borderline for transcatheter edge-to-edge repair (TEER), a salvage TEER procedure was performed. Mitral regurgitation decreased to mild-to-moderate (2+), pulmonary venous flow improved, and sustained clinical stabilization was achieved.

Conclusion: In advanced heart failure with multifactorial hemodynamic compromise, the dominant driver of instability may evolve over time. Sequentially targeting ischemia, dyssynchrony, and mitral regurgitation may result in meaningful hemodynamic improvement, even when individual interventions provide only partial benefit, particularly in patients who are not candidates for surgical therapy.

Keywords: PCI, TEER, advanced heart failure

[OP-92]**Acute Ischemic Stroke Due to Chordal Embolism After Percutaneous Mitral Balloon Valvuloplasty in a Pregnant Patient With Severe Rheumatic Mitral Stenosis: A Case Report**

Mert Evlice¹, Halil Coşkun¹, Mükremin Coşkun¹, Ayşegül Küçükosmanoğlu², Derya Özdoğru³, İbrahim Halil Kurt¹, Emre Sezici¹, Burak Cabbar Karakurt¹, İlhan Kaplan¹

¹*Clinic of Cardiology, University of Health Sciences Türkiye, Adana City Training and Research Hospital, Adana*

²*Clinic of Pathology, University of Health Sciences Türkiye, Adana City Training and Research Hospital, Adana*

³*Clinic of Neurology, University of Health Sciences Türkiye, Adana City Training and Research Hospital, Adana*

Percutaneous mitral balloon valvuloplasty (PMBV) is the preferred treatment modality for severe mitral stenosis unresponsive to medical therapy during pregnancy. Although the procedure is generally safe, embolic complications are rare. In this report, we present a 22-year-old woman at 25 weeks of gestation with severe rheumatic mitral stenosis who underwent PMBV and subsequently developed an acute ischemic stroke due to histopathologically confirmed chordal embolism. Complete neurological recovery was achieved with emergency endovascular thrombectomy. The pregnancy progressed without complications, and the patient delivered a healthy infant at term by cesarean section. This case represents one of the rare reports demonstrating pathological evidence of chordal embolism after PMBV with a favorable maternal and fetal outcome.

Keywords: Pregnancy, mitral stenosis, percutaneous mitral balloon valvuloplasty, chordal embolism, acute ischemic stroke




Figure 1. These two biopsy samples, one 0.4 cm and the other 0.3 cm in diameter, both yellowish-white in color

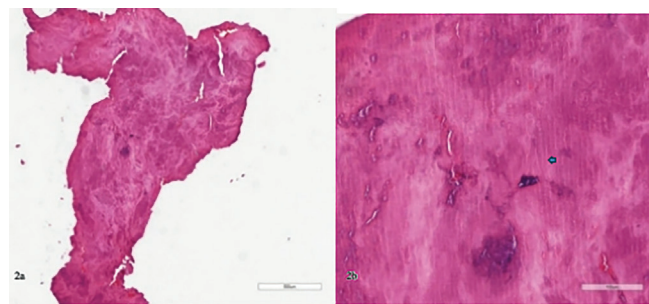


Figure 2. In the sections, Fibrosis (Figure 2a) and calcification (Figure 2b) were observed (HE)

[OP-93]**Absence of the Left Main Coronary Artery with Hypoplastic LAD and LCx Accompanied by a Superdominant Right Coronary Artery: A Rare Congenital Coronary Anomaly**Sewal Özdemir¹, Emre Eynel²¹Department of Cardiology, Sakarya University Faculty of Medicine, Sakarya²Clinic of Cardiology, Sakarya Training and Research Hospital, Sakarya

Aim: Coronary artery anomalies are rare cardiovascular malformations, most often identified incidentally during coronary angiography performed for suspected coronary artery disease or other cardiac conditions. Their prevalence is reported to be below 1%, while the presence of a single coronary artery is exceptionally rare, with an incidence of approximately 0.05%. Depending on their anatomical origin, course, and structural characteristics, these anomalies may range from benign variants to clinically significant conditions associated with myocardial ischemia and sudden cardiac death. We report a rare case of left main coronary artery (LMCA) agenesis accompanied by hypoplastic left anterior descending (LAD) and left circumflex (LCx) arteries, in which a superdominant right coronary artery (RCA) supplied the majority of the myocardium.

Case Report: A 48-year-old male with a history of smoking and a positive family history of cardiovascular disease presented with a several-day history of left arm pain. On admission, his vital signs were within normal limits, and electrocardiography demonstrated normal sinus rhythm without ischemic changes. Transthoracic echocardiography revealed a preserved left ventricular ejection fraction of 65% and no significant valvular abnormalities. Laboratory evaluation showed markedly elevated lipid levels, including low-density lipoprotein cholesterol of 268 mg/dL, total cholesterol of 372 mg/dL, and triglycerides of 203 mg/dL. High-sensitivity troponin I was within normal limits (<0.1 µg/L). Coronary computed tomography angiography demonstrated a coronary artery calcium score of 0 according to AJ-130 criteria. A hypoplastic vascular structure arising from the left sinus of Valsalva was suspected; however, a true LMCA was not identified. The proximal segment of the LAD appeared atretic, whereas its mid and distal segments were visualized via retrograde filling from the RCA. The LCx artery was also atretic. The RCA was superdominant, giving rise to the posterior descending artery and posterolateral branches, and supplying an extensive myocardial territory, including the LAD distribution. Additionally, multiple collateral vascular structures originating from the descending aorta were observed. Invasive coronary angiography confirmed the absence of the LMCA, along with hypoplastic LAD and LCx arteries. The superdominant RCA exhibited non-critical atherosclerotic plaques and provided perfusion to the majority of the myocardium. The patient was initiated on medical therapy with aspirin (100 mg/day) and rosuvastatin (40 mg/day) and was discharged with a plan for outpatient follow-up.

Discussion: Single coronary artery anomalies are classified based on the origin and anatomical course of the vessel, with the Lipton-Yamanaka classification being the most widely used system. In Group I variants, either the right or left coronary artery follows its normal anatomical course while supplying the entire myocardium as a superdominant vessel. A superdominant RCA is an extremely rare finding. The reported prevalence of congenital absence of the LCx artery is approximately 0.067%. In the present case, the coexistence of LMCA agenesis, hypoplastic LAD and LCx arteries, and a superdominant RCA supplying a large myocardial territory represents an unusual anatomical configuration that does not fully conform to existing classification systems.

The mechanisms responsible for symptom development in such anomalies are not fully understood. Proposed explanations include coronary vasospasm, mechanical compression during myocardial contraction, abnormal take-off angles resulting in impaired coronary flow, and arterial hypoplasia. In addition, a coronary steal phenomenon related to increased myocardial oxygen demand may contribute to clinical manifestations.

Conclusion: Coronary artery anomalies in which a single dominant vessel supplies a large myocardial territory may have important clinical implications. In such cases, any future stenosis or occlusion may place a substantial portion of the myocardium at risk. Therefore, accurate identification of these rare anatomical variants using advanced imaging modalities is essential for appropriate clinical management and risk stratification.

Keywords: Congenital coronary anomaly, LMCA agenesis, superdominant RCA, single coronary artery

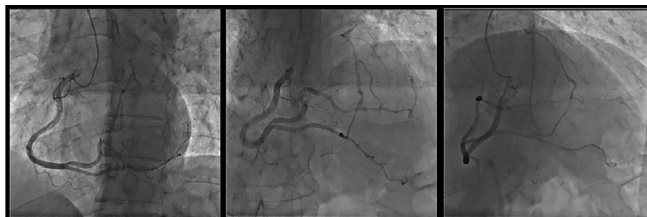


Figure 1. Angiographic imaging of the right coronary system

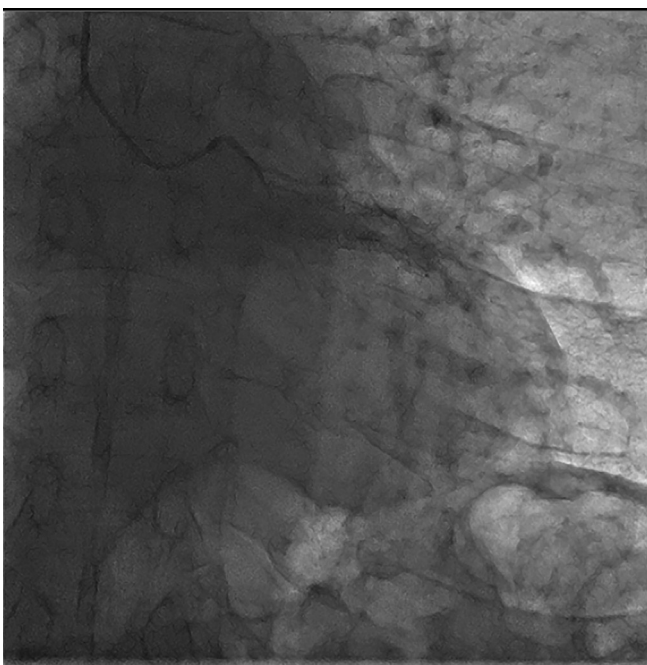

Figure 2. Angiographic imaging of the left coronary system

[OP-94]**Transcatheter Treatment Approach in Dual-drained Partial Pulmonary Venous Return: The Critical Role of the Balloon Occlusion Test**

Özlem Sürekli Karakus, Şule Arıcı, Erkan Taş, Sezgin Bayraktar, Fatih Alparslan Genç, Gülperi Yağar Keskin, Metin Sungur, Ayşe İnci Yıldırım

Clinic of Pediatric Cardiology, University of Health Sciences Türkiye, Koşuyolu High Specialty Training and Research Hospital, Istanbul

Aim: Partial anomalous pulmonary venous return (PAPVR) is a congenital anomaly that requires surgical repair. However, the presence of dual pulmonary venous drainage (connection to both the systemic circulation and left atrium) offers an important interventional opportunity to avoid surgical morbidity. This study presents a transcatheter closure strategy guided by balloon occlusion testing and the early outcomes of PAPVR management.

Methods: Between 2022 and 2026, 25 patients diagnosed with isolated PAPVR at our center were retrospectively analyzed. Patients were evaluated in terms of venous drainage patterns, invasive hemodynamic data, and suitability for transcatheter interventions.

Results: In the study group (n=25, age range 2-16 years), abnormal venous return was located on the left side in 13 patients and on the right side in 12 patients. Surgical repair was performed in 17 patients, and six patients were followed up clinically. In the last year, a transcatheter strategy was applied to two cases of angiographically detected dual pulmonary venous drainage (abnormal vein connecting both to the innominate vein via the vertical vein and to the left atrium via the natural pathway) using a balloon occlusion test. Both patients showed normal pulmonary artery pressures and significant left-to-right shunts (Qp/Qs=2) on invasive evaluation. Prior to permanent occlusion, balloon occlusion of the vertical vein demonstrated sufficient pulmonary venous drainage to the left atrium and stable hemodynamics (pulmonary venous and left atrial pressure). Subsequently, the abnormal connection was successfully closed using Amplatzer Vascular Plug II devices owing to their high vascular compatibility and rapid occlusion capacity. One-year follow-up showed complete regression of right heart volume overload without pulmonary venous obstruction or device-related complications.

Conclusion: In patients diagnosed with PAPVR, the presence of dual venous drainage should be meticulously investigated. The balloon occlusion test must be an integral part of the procedure in all cases with suitable anatomy. In patients in whom sufficient pulmonary venous drainage to the left atrium is confirmed hemodynamically and angiographically during the test, transcatheter closure provides a safe, minimally invasive, and superior alternative to surgery. This approach should be considered the preferred option for PAPVR management with appropriate anatomical variants, as it eliminates the need for surgical and cardiopulmonary bypass interventions.

Keywords: Partial pulmonary venous return anomaly, dual drainage, transcatheter occlusion

[OP-95]**Spatial QRS-T Angle and Quantified Ischemia Burden in Ischemia with Non-obstructive Coronary Arteries**

Müzeyyen Gizem Parmak, Erdoğan Sökmen, Muhammet Salih Ateş, Alp Yıldırım

Clinic of Cardiology, Kırşehir Training and Research Hospital, Kırşehir

Aim: Ischemia with non-obstructive coronary arteries (INOCA) is increasingly recognized as a clinically relevant entity, yet effective risk stratification remains limited. The spatial QRS-T (sQRS-T) angle integrates global depolarization-repolarization heterogeneity and may reflect ischemic burden more accurately than conventional ECG markers.

Methods: This retrospective study included 1,432 INOCA patients with reversible perfusion defects on myocardial perfusion scintigraphy (MPS) and no $\geq 50\%$ epicardial stenosis on angiography. Ischemic burden was quantified as the percentage of left ventricular (LV) myocardium with reversible defects and categorized as $<5\%$, $5-10\%$, or $>10\%$. Spatial and frontal QRS-T angles, QT dispersion (QTd), QTc, P-wave dispersion, Tp-e interval, and Tp-e/QTc ratio were measured on resting ECGs. Echocardiographic indices and routine laboratory markers were also recorded. Severe ischemia ($>10\%$ LV) was the primary logistic regression outcome. Four hierarchical multivariable models incorporated ECG, clinical, echocardiographic, and laboratory parameters. ROC analyses with DeLong testing evaluated discrimination.

Results: Among 1,432 patients, 52.4% had $<5\%$ ischemia, 27.9% had $5-10\%$, and 19.7% had $>10\%$. The sQRS-T angle, QTd, Tp-e, and Tp-e/QTc increased stepwise across ischemia categories (all $p < 0.001$). In multivariable models, the sQRS-T angle remained an independent predictor of severe ischemia (OR: 1.27 per 10° increase, 95% CI: 1.16-1.40; $p < 0.001$). QTd and Tp-e/QTc also retained significance, whereas frontal QRS-T angle, QTc, Tp-e interval, and P-wave dispersion did not. The sQRS-T angle showed good discrimination (AUC: 0.78), and a combined ECG model integrating sQRS-T angle, QTd, and Tp-e/QTc improved performance (AUC: 0.83; $p = 0.008$).

Conclusion: The sQRS-T angle is independently associated with MPS-derived ischemic burden in INOCA. A simple ECG-based model combining dispersion markers provides incremental discriminatory value and may help identify patients with a high ischemic burden who require closer follow-up.

Keywords: Coronary microvascular dysfunction, electrocardiography, myocardial ischemia, repolarization, single-photon emission computerized tomography

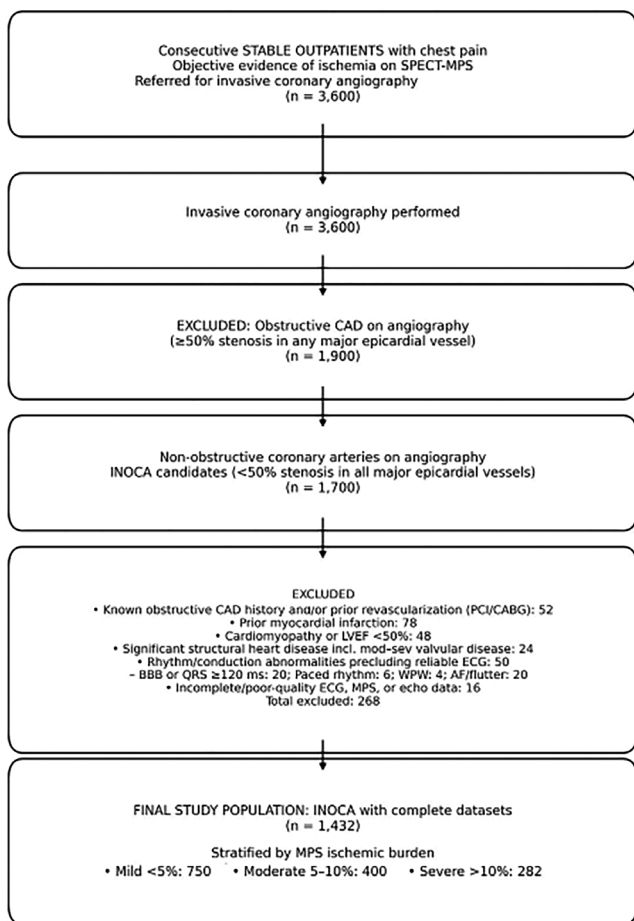


Figure 1. Patient inclusion flowchart

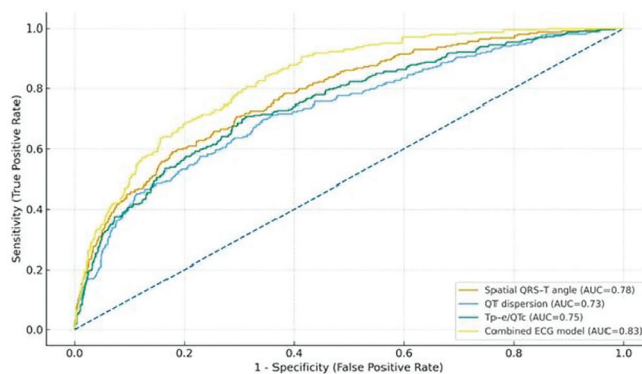


Figure 2. Receiver-operating characteristic (ROC) curves comparing ECG-based predictors of >10% LV ischemia

Table 4.

Variable (unit increase)	Univariate, OR (95% CI)	p value	Model 1 ECG only, OR (95% CI)	p value	Model 2 ECG + Clinical, OR (95% CI)	p value	Model 3 + Echo, OR (95% CI)	p value	Model 4 + Lab, OR (95% CI)	p-value
Spatial QRS-T angle	1.45 (1.33-1.58)	<0.001	1.38 (1.27-1.51)	<0.001	1.33 (1.22-1.45)	<0.001	1.30 (1.19-1.42)	<0.001	1.27 (1.16-1.40)	<0.001
Frontal QRS-T angle	1.12 (1.04-1.21)	0.004	1.06 (0.99-1.15)	0.10	1.04 (0.97- 1.13)	0.27	1.03 (0.96-1.12)	0.38	1.02 (0.95-1.11)	0.54
QT dispersion	1.30 (1.21-1.40)	<0.001	1.24 (1.15-1.34)	<0.001	1.20 (1.11-1.30)	<0.001	1.17 (1.08-1.28)	<0.001	1.15 (1.05-1.26)	0.003
P-wave dispersion	1.20 (1.09-1.33)	0.001	1.09 (0.99-1.21)	0.08	1.07 (0.97-1.18)	0.19	1.06 (0.96-1.17)	0.30	1.05 (0.95-1.16)	0.36
Tp-e interval	1.17 (1.08-1.27)	<0.001	1.10 (1.01-1.20)	0.04	1.12 (1.03-1.23)	0.009	1.07 (0.98-1.18)	0.12	1.06 (0.97-1.16)	0.22
QTc	1.14 (1.06-1.22)	0.001	1.10 (1.02-1.19)	0.02	1.08 (1.01-1.17)	0.03	1.05 (0.97-1.14)	0.18	1.04 (0.96-1.13)	0.26
Tp-e/QTc	1.22 (1.13-1.32)	<0.001	1.20 (1.11-1.30)	<0.001	1.18 (1.09-1.28)	<0.001	1.16 (1.07-1.26)	<0.001	1.14 (1.05-1.24)	0.002

Logistic regression analysis of ECG parameters for predicting >10% LV ischemia

Table 5.

Variable/model	AUC (95% CI)	p (AUC >0.5)	Optimal cut-off	Sensitivity, %	Specificity, %	DeLong p vs. spatial QRS-T
Spatial QRS-T angle (°)	0.78 (0.75-0.82)	<0.001	>85°	78	69	Reference
QT dispersion (ms)	0.73 (0.69-0.76)	<0.001	>47 ms	68	65	0.03
Tp-e/QTc	0.75 (0.72-0.79)	<0.001	>0.205	70	67	0.09
Combined ECG model*	0.83 (0.80-0.86)	<0.001	Probability >0.45	80	72	0.008

Receiver-operating characteristic (ROC) analysis for predicting >10% LV ischemia
*Combined ECG model includes spatial QRS-T angle, QT dispersion, and Tp-e/QTc in a logistic regression-derived probability

[OP-96]**A Rare Condition Detected by Cardiac CT: A Case of the Right Coronary Artery Running within the Right Atrium**

Ahmet Yanık, İsmail Ekinözü

Medicana International Samsun Hospital, Samsun

A 64-year-old female patient presented to our outpatient clinic with palpitations and intermittent atypical chest pain. Her medical history included hypertension and diabetes mellitus. She was receiving bisoprolol 5 mg once daily, olmesartan 40 mg once daily, and oral antidiabetic medication. Her electrocardiogram showed normal sinus rhythm at 80 beats per minute, with no ischemic changes. Echocardiography revealed a left ventricular ejection fraction of 65%, normal left ventricular dimensions and systolic function, degenerative valvular changes, and grade 1 aortic regurgitation. Due to the patient's symptoms and cardiovascular risk factors, coronary CT angiography was recommended. Coronary CT angiography demonstrated that the right coronary artery originated from the right coronary sinus. Its proximal segment coursed through the coronary sulcus; subsequently, it travelled within the right atrium for approximately 30 mm before returning to the coronary sulcus. Mild to moderate stenosis, approximately 25-49%, was observed in the right coronary artery. In the literature, a right coronary artery coursing within the atrium is usually detected in autopsy series or by coronary CT angiography. Our case represents one of the rare cases identified by coronary CT angiography. The patient is currently being followed medically.

Keywords: Coronary CT, right coronary artery, coronary anomaly

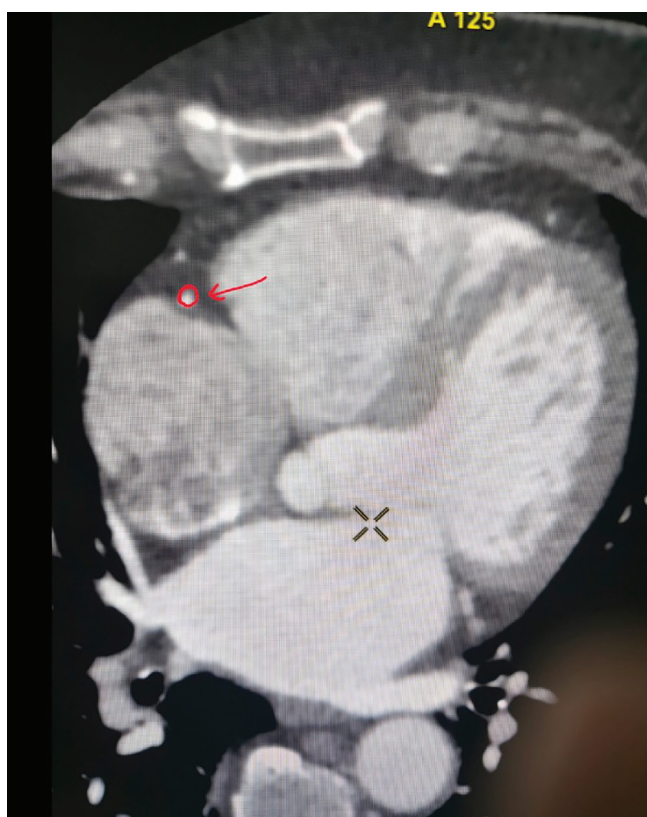


Figure 1. RCA image coursing within the atrium-1

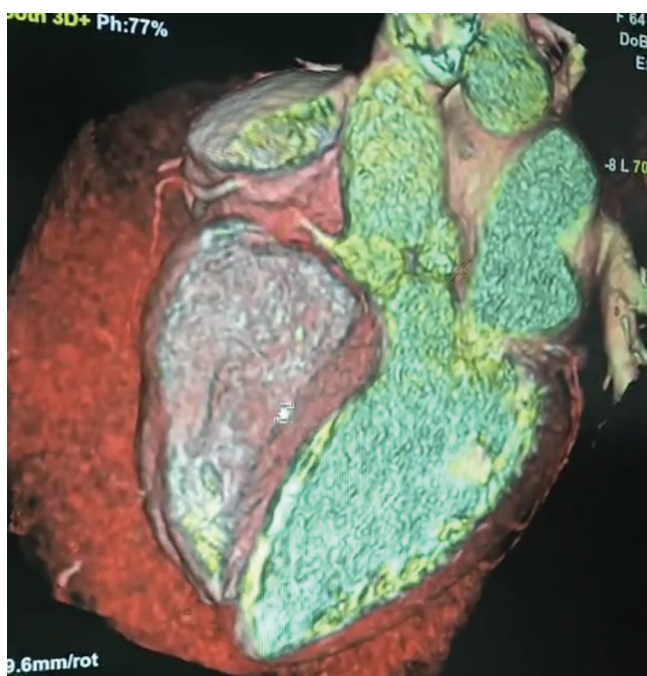

Figure 2. RCA image coursing within the atrium-2

[OP-97]

Takotsubo Cardiomyopathy Following Pembrolizumab Therapy: A Case Report

Gizem Ayyıldız, Kenan Yalta, Servet Altay

Department of Cardiology, Trakya University Faculty of Medicine, Edirne

Aim: Takotsubo cardiomyopathy is a rare cardiac condition that mimics acute myocardial infarction. Its association with immune checkpoint inhibitors and chemotherapeutic agents used in cancer treatment has been reported only occasionally. Takotsubo cardiomyopathy is a rare cardiac syndrome, usually triggered by physical or emotional stress, and characterized by transient left ventricular dysfunction. Cardiac events related to immune checkpoint inhibitors (e.g., pembrolizumab) and chemotherapeutic agents (e.g., pemetrexed) have been infrequently reported in oncology patients. This case provides a valuable contribution to the literature, highlighting the development of Takotsubo cardiomyopathy following the combination of pembrolizumab and pemetrexed.

Case Report: A 68-year-old male patient with a history of hypertension and a prior inferior myocardial infarction, treated with a percutaneous coronary intervention (PCI) to the circumflex artery, was diagnosed with lung adenocarcinoma in 2023. Systemic therapy with pembrolizumab and pemetrexed was initiated. In April 2025, after the 34th cycle, pembrolizumab was discontinued, and treatment continued with pemetrexed alone. The last pemetrexed dose was administered as the 46th cycle in December 2025. During routine follow-up, the patient was found to have elevated troponin levels and was referred to emergency room. While under observation, ST-segment elevation developed in the anterior leads, and primary coronary angiography was performed, revealing no acute obstructive coronary lesions. Transthoracic echocardiography demonstrated apical ballooning and marked wall motion abnormalities in the apical and mid-ventricular segments. Cardiac magnetic resonance imaging showed global hypokinesia of the apical segments and late gadolinium enhancement in the mid-ventricular segments, consistent with Takotsubo cardiomyopathy. Follow-up echocardiography performed one week later showed an EF of 60% with normal wall motion, confirming the transient nature of the syndrome.

Discussion: Takotsubo cardiomyopathy is a rare cardiac syndrome, usually triggered by physical or emotional stress, and characterized by transient left ventricular dysfunction. Cancer treatments, particularly immune checkpoint inhibitors (ICIs), have been associated with the development of Takotsubo cardiomyopathy, although this association is rare and the underlying mechanisms are not yet fully understood. The mechanisms of cancer therapy-associated Takotsubo cardiomyopathy are thought to involve not only stress-induced catecholamine surges and autonomic dysfunction, but also increased myocardial susceptibility caused by coronary microvascular dysfunction, endothelial injury, and oxidative stress. In our case, we hypothesize that prolonged pembrolizumab therapy induced a subclinical myocardial sensitization. By blocking the PD-1/PD-L1 pathway, pembrolizumab may have lowered the threshold for myocardial injury, making the heart hypersensitive to subsequent triggers. Following this “primed” state, the administration of pemetrexed likely acted as the definitive trigger. Pemetrexed has been

documented to cause cardiomyopathy and acute coronary syndrome signals in pharmacovigilance databases, potentially through endothelial dysfunction and coronary vasospasm. This combination provides a plausible “dual-hit” model for the development of the Takotsubo phenotype. A notable feature of this case is the delayed-onset presentation. While most ICI-related cardiotoxicities occur early, this event manifested after the 34th cycle of pembrolizumab and the 46th cycle of pemetrexed. This suggests that cumulative exposure can still trigger acute cardiac syndromes long after the initiation of therapy. The rapid recovery of the left ventricular ejection fraction to 60% within one week, with complete resolution of wall motion abnormalities, confirms the transient nature of the syndrome and the diagnosis of Takotsubo cardiomyopathy. The late gadolinium enhancement (LGE) observed on CMR may reflect transient myocardial edema rather than permanent necrosis, which is consistent with findings in therapy-related Takotsubo cases.

Conclusion: Our case highlights the development of Takotsubo cardiomyopathy following the combination of pembrolizumab and pemetrexed, providing a valuable contribution to the literature on rare cases where the immunologic and chemotherapeutic effects of cancer treatment are evaluated together. Clinicians should remain vigilant for late-onset cardiac complications in oncology patients, as early recognition and a multidisciplinary approach are essential for successful management.

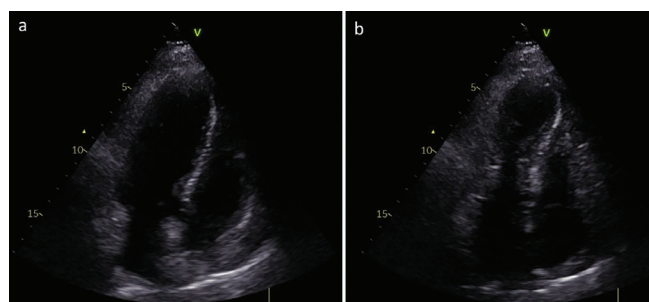


Figure 1. (a) Apical ballooning and apical hypokinesia in the left ventricle during end-diastolic phase. (b) Hyperkinetic motion of the basal segments in the left ventricle during end-systolic phase

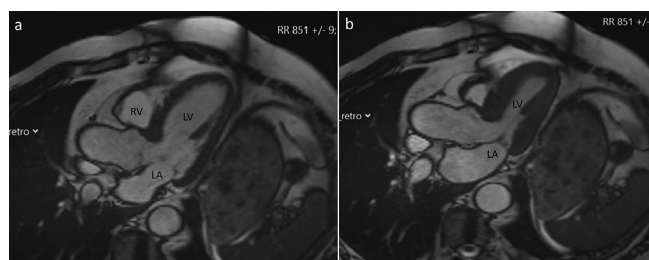


Figure 2. (a) Cardiac magnetic resonance imaging in the horizontal axis showing the left ventricle during the diastolic phase. (b) Cardiac magnetic resonance imaging in the horizontal axis showing the left ventricle during the systolic phase

[OP-98]

Low HALP Score in Non-obstructive Coronary Artery Disease: A Strong and Independent Predictor of Coronary Slow Flow Phenomenon

Nadire Işık Erol Algül¹, Muhammed Erzurum², Mehmet Ali Felekoğlu³, Nail Burak Özbeyaz⁴

¹Department of Cardiology, Yıldırım Beyazıt University Yenimahalle Training and Research Hospital, Ankara

²Clinic of Cardiology, Karabük Training and Research Hospital, Karabük

³Clinic of Cardiology, Yunus Emre State Hospital, Eskişehir

⁴Department of Cardiology, Ankara University Faculty of Medicine, Ankara

Aim: The HALP score (Hemoglobin×albumin×lymphocyte/platelet) is a novel biomarker that integratively reflects inflammation, nutritional status, and hematological condition. In this study, we aimed to investigate the relationship between the HALP score and the coronary slow flow phenomenon (CSFP) in patients with non-obstructive coronary artery disease (NOCAD), and to determine the independent predictive value of HALP for CSFP.

Methods: A total of 1,273 patients who underwent coronary angiography for chronic coronary syndrome between March 2019 and March 2023 and had no obstructive lesions (<40% stenosis) were retrospectively evaluated. Based on TIMI frame count (TFC) measurements, 79 patients were diagnosed with CSFP. A control group of 158 patients was formed using 1:2 age matching (total n=237). The HALP score was calculated using the formula: hemoglobin (g/dL)×albumin (g/L)×lymphocyte (/μL)/platelet (/μL). The groups were compared in terms of baseline characteristics and laboratory parameters. Independent predictors were identified using logistic regression analysis, and diagnostic performance was evaluated with receiver operating characteristic (ROC) curve analysis.

Results: The HALP score was significantly lower in the CSFP group compared to the control group (22.4±7.8 vs. 38.6±11.2; p<0.001). The HALP score decreased significantly as the number of affected vessels increased (p<0.001). In multivariate logistic regression analysis, only the HALP score was identified as an independent predictor (OR: 0.83; 95% CI: 0.77-0.94; p=0.001). In ROC analysis, the HALP score demonstrated the highest area under the curve (AUC) compared to hemoglobin, lymphocyte count, and albumin (AUC: 0.871; 95% CI: 0.823-0.919; p<0.001). The optimal cut-off value was ≤29.3, with a sensitivity of 79.7% and a specificity of 85.4%.

Conclusion: A low HALP score emerges as an independent predictor of CSFP in patients with NOCAD. By integrating inflammation, nutritional status, and hematological parameters into a single index, the HALP score can be easily calculated in routine clinical practice and may serve as a valuable tool for early identification of CSFP risk. Further multicenter prospective studies are warranted to validate these findings.

Keywords: Chronic coronary syndrome, coronary slow flow phenomenon, HALP score, inflammation, non-obstructive coronary artery disease

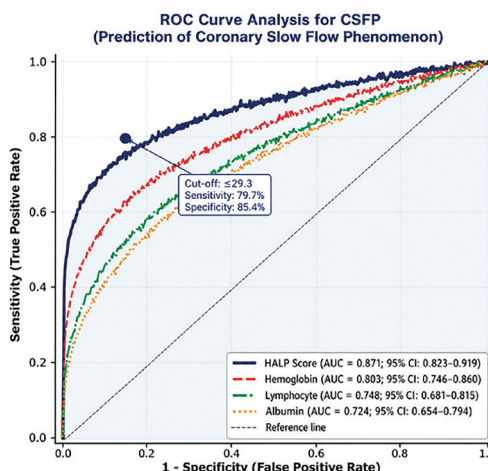


Figure 1. ROC curve for CSFP components of the HALP score AUC: Area under the curve, CI: Confidence interval, CSFP: Coronary slow flow phenomenon, the HALP score demonstrated the highest AUC value among all components

Table 1. Baseline clinical characteristics, laboratory parameters, and HALP score

Variable	CSFP Group (n=79)	Control Group (n=158)	p-value
Age (years)	61.3±9.4	61.3±9.4	1.000
Male sex, n (%)	62 (78.5)	122 (77.2)	0.823
BMI (kg/m ²)	25.1±2.8	25.0±3.1	0.801
Hypertension, n (%)	52 (65.8)	68 (43.0)	0.001
Diabetes mellitus, n (%)	26 (32.9)	38 (24.1)	0.153
Current smoking, n (%)	34 (43.0)	44 (27.8)	0.021
Statin use, n (%)	29 (36.7)	53 (33.5)	0.714
Beta-blocker use, n (%)	20 (25.3)	32 (20.3)	0.420
Hemoglobin (g/dL)	12.4±1.9	14.1±1.6	<0.001
Albumin (g/L)	36.8±4.1	38.6±3.5	0.002
Lymphocyte (×10 ³ /μL)	1.62±0.54	2.08±0.61	<0.001
Platelet (×10 ³ /μL)	198.4±52.1	221.7±58.3	0.004
LDL cholesterol (mmol/L)	2.9±0.9	2.7±0.9	0.118
eGFR (mL/min)	70.1±15.6	71.7±14.2	0.481
HALP score	22.4±7.8	38.6±11.2	<0.001

Table 2. Univariate and multivariate logistic regression analysis

Variable	Univariate OR	95% CI	Multivariate OR	95% CI	p-value
Hypertension	1.62	1.18-2.74	1.54	0.82-2.91	0.182
Smoking	1.97	1.21-3.84	1.86	0.91-3.79	0.087
HALP score	0.85	0.79-0.91	0.83	0.77-0.94	0.001

[OP-99]

Regression of Severe Mitral Regurgitation After STEMI Following Optimal Medical Therapy and Complete Coronary Revascularization

Emre Berk Erkip, Fatih Kahraman, Veysel Elitaş, Recep Gülmez, Afşin Parspur
 Department of Cardiology, Kütahya University of Health Sciences, Kütahya

Aim: Mitral regurgitation (MR) following acute myocardial infarction is associated with significant morbidity and mortality. As a mechanical complication, MR may arise due to papillary muscle dysfunction, left ventricular remodeling, or aneurysm formation. Although severe MR may require surgical intervention in some cases, regression may occur with optimal medical therapy and successful revascularization. In this report, we present a case of severe MR that improved clinically and echocardiographically without the need for valve intervention.

Case Report: A 65-year-old male presented with chest pain lasting more than 24 hours. He was diagnosed with subacute inferior STEMI and pneumonia. Coronary angiography revealed 100% CTO in the LAD after D1, 100% occlusion in the mid LCx, and 90% stenosis in the proximal RCA. The patient initially underwent primary PCI to the LCx along with treatment for pneumonia and was discharged. Fifteen days later, RCA PCI was performed, and elective LAD CTO PCI was planned. During this period, the patient developed progressively worsening dyspnea and heart failure symptoms. Transthoracic echocardiography showed severe MR and an ejection fraction of 30%. Despite initiation of optimal medical therapy, only minimal symptomatic improvement was achieved. The patient subsequently presented with worsening dyspnea and was found to have pulmonary congestion on chest X-ray, leading to admission to the coronary intensive care unit with a diagnosis of hypertensive pulmonary edema. On admission:

- Blood pressure: 180/100 mmHg
 - SpO₂: 84%
 - ECG: Normal sinus rhythm with poor R-wave progression in anterior leads
- Following intensive medical treatment, the patient improved clinically. However, repeat echocardiography showed persistent severe MR. Transesophageal echocardiography revealed:
- Severe MR (EROA: 0.69 cm², regurgitant volume: 97 mL)
 - Inferior wall aneurysm and diffuse hypokinesia
 - Moderate-to-severe tricuspid regurgitation
 - sPAP: 80 mmHg
- Due to persistent severe symptoms despite optimal medical therapy, early intervention for secondary MR was reconsidered. Treatment options included:
- Mitral valve replacement + LIMA-LAD CABG
 - MitraClip + LAD CTO PCI

The patient was initially discharged under intensified medical therapy. At 15-day follow-up TEE, MR regressed to moderate severity. However, symptoms persisted despite aggressive diuresis and optimized heart failure therapy. Therefore, early LAD CTO PCI was performed.

Discussion: MR is one of the most serious mechanical complications of acute coronary syndromes and is often secondary to left ventricular dysfunction. Acute ischemic MR can be highly symptomatic and may lead to severe heart failure, pulmonary congestion, and increased mortality if not treated promptly. The presence of a CTO may further contribute to clinical deterioration, raising the consideration of combined coronary and valvular interventions. However, percutaneous CTO intervention in patients with severe decompensation may be challenging due to prolonged procedural time, high contrast load, and patient intolerance. Ischemic MR is predominantly related to alterations in left ventricular geometry rather than primary valvular pathology. Revascularization of viable myocardium can result in reverse remodeling, reducing papillary muscle displacement and leaflet tethering,

thereby decreasing MR severity. In this case, the rapid regression of MR from severe to mild following optimal medical therapy and successful LAD CTO revascularization highlights the critical role of ventricular remodeling in the management of secondary MR.

Conclusion: Severe MR following acute coronary syndrome does not always require surgical intervention. With appropriate medical therapy and complete revascularization, significant regression may occur. This case emphasizes the importance of addressing ventricular pathology in the management of secondary MR.

Keywords: STEMI, mitral regurgitation, PCI, medical therapy

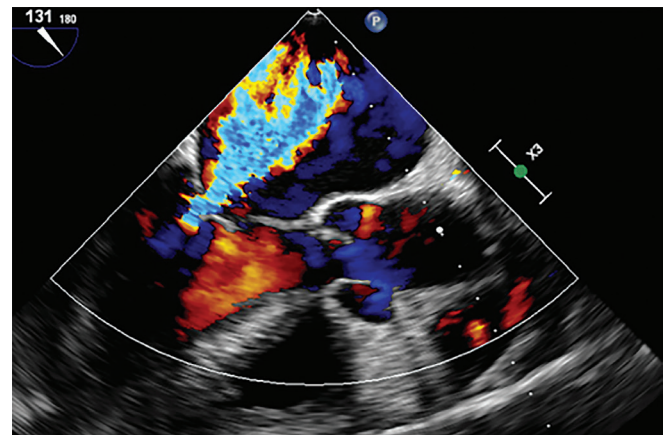


Figure 1. Severe mitral regurgitation, TEE image

CENTRAL ILLUSTRATION: Secondary Mitral Regurgitation Versus Atrial Functional Mitral Regurgitation	
Secondary Mitral Regurgitation	Atrial Functional Mitral Regurgitation
<p>↓ Closing Force</p> <ul style="list-style-type: none"> • ↓ LV contractility • ↑ LA pressure • ↓ Annular contraction <p>↑ Tethering Force</p> <ul style="list-style-type: none"> • LV dilation & dyskinesia • PM displacement/dysynchrony • Annular dilation (relative) <p>Coaptation Depth</p> <p>Eccentric MR Jet</p>	<p>↓ Closing Force</p> <ul style="list-style-type: none"> • ↑ LA pressure • ↓ Annular contraction <p>Leaflet Malcoaptation</p> <ul style="list-style-type: none"> • Annular dilation and flattening • Insufficient leaflet growth • Fibrotic leaflet thickening • Altered atrial/annular dynamics <p>Coaptation Depth</p> <p>Central MR Jet</p>
Etiology and Prevalence	
<ul style="list-style-type: none"> • 11%-59% post myocardial infarction • >50% in dilated cardiomyopathy 	<ul style="list-style-type: none"> • 6%-7% in lone AF • Up to 53% in HFpEF
Diagnosis	
<ul style="list-style-type: none"> • Systolic LV dysfunction • Restricted leaflet motion and tethering • Eccentric jet > central jet • Relative LA dilation 	<ul style="list-style-type: none"> • Normal systolic LV function • Normal leaflet motion • Central jet • Severe LA dilation
Management	
<ul style="list-style-type: none"> • Optimal HF therapy • Cardiac resynchronization therapy • Revascularization • MitraClip 	<ul style="list-style-type: none"> • Address AF/HFpEF risk factors and lifestyle • HF therapy, diuretics as indicated • Early sinus restoration strategy • ?Intervention, annuloplasty, MitraClip
Deferm, S. et al. J Am Coll Cardiol. 2019;73(19):2465-76.	

Figure 2. Secondary mitral regurgitation: mechanisms and management